

J. P. Lord.

PRESIDENT, 1910

TWENTIETH ANNUAL MEETING

TRANSACTIONS OF THE

WESTERN SURGICAL ASSOCIATION

Twentieth Annual Meeting, held at
Chicago, Illinois, December 19 & 20, 1910

MINNEAPOLIS
PRESS OF THE JOURNAL-LANCET
1911

BOSTON MEDICAL
MAY 7 1
LIBRARY

CATALOGUED
D. B. S.

OFFICERS AND EXECUTIVE COUNCIL, 1911

PRESIDENT

Amos W. Abbott - - - Minneapolis

FIRST VICE-PRESIDENT

Albert E. Halstead - - - - Chicago

SECOND VICE-PRESIDENT

William J. Frick - - - Kansas City, Mo.

SECRETARY-TREASURER

Arthur T. Mann - - - Minneapolis

EXECUTIVE COUNCIL

John P. Lord, Chairman - - Omaha, Neb.

Arthur L. Wright - - - Carroll, Iowa

William W. Grant - - - Denver, Colo.

Charles W. Oviatt - - - Oshkosh, Wis.

Malcolm L. Harris - - - Chicago, Ill.

James E. Moore - - - Minneapolis, Minn.

CHAIRMAN COMMITTEE OF ARRANGEMENTS

Jabez N. Jackson - - Kansas City, Mo.

EX-PRESIDENTS AND MEETING PLACES

PRESIDENT	PLACE	YEAR
S. S. Todd*	Topeka	1891
Milo B. Ward*	Kansas City	1892
Milo B. Ward*	Des Moines	1893
Lewis Schooler	Omaha	1894
John E. Summers, Jr.	Kansas City	1895
Thomas J. Beattie	Topeka	1896
Joseph Eastman*	Denver	1897
David S. Fairchild	Omaha	1898
Homer C. Crowell	Des Moines	1899
O. Beverly Campbell	Minneapolis	1900
August F. Jonas	Chicago	1901
James E. Moore	St. Joseph	1902
Alex. Hugh Ferguson	Denver	1903
Charles H. Mayo	Milwaukee	1904
Harvey D. Niles*	Kansas City	1905
Malcolm L. Harris	Salt Lake City	1906
Charles W. Oviatt	St. Louis	1907
William W. Grant	Minneapolis	1908
Arthur L. Wright	Omaha	1909
John P. Lord	Chicago	1910

*Deceased.

The Western Surgical Association does not hold itself responsible for, or necessarily endorse, any of the papers printed herein.

ARTHUR T. MANN, Secretary-Treasurer.

CONTENTS

Officers and Executive Council for 1911..... 5
Ex-Presidents and Meeting Places..... 7
Transactions 9

PAPERS

President's Address: Division of Fees and Giving Commissions. John P. Lord, Omaha, Nebraska..... 15

Desmoid Tumors of the Abdominal Wall After Operation. E. Wyllys Andrews, Chicago, Illinois..... 27

Non-Suppurative Osteomyelitis. J. Clark Stewart, Minneapolis, Minnesota..... 23

Primary Sarcoma of the Appendix. Everett O. Jones, Seattle, Washington..... 49

The Operative Technic in Acute Suppurative Appendicitis. Willard Bartlett, St. Louis, Missouri..... 67

Surgery of the Mediastinum Other than Injury and Disease of the Cardiovascular System. Benj. Merrill Ricketts, Cincinnati, Ohio..... 75

A New principle in the Action of Antiseptics. M. G. Seelig and C. W. Gould, St. Louis, Missouri..... 81

Definite Knowledge Obtained by Means of the *X*-ray. E. M. Sala, Rock Island, Illinois..... 95

Primary Suture of Subparietal Rupture of the Kidney, with Report. F. Gregory, Connell, Oshkosh, Wisconsin 109

Intussusception, with Special Reference to Adults. Ellsworth Eliot and James A. Corscaden, New York City, New York..... 131

Intestinal Obstruction Due to Kinks and Adhesions of the Terminal Ileum. Charles H. Mayo, Rochester, Minnesota 209

Pathological Conditions Arising as a Result of Meckel's Diverticulum. Byron B. Davis, Omaha, Nebraska.... 221

The Selection of Operation for Inguinal Hernia. Archibald MacLaren and Harry P. Ritchie, St. Paul, Minnesota 233

The Plication of the Anterior Fold of the Broad Ligament for Retrodisplacement of the Uterus. A. W. Abbott, Minneapolis, Minnesota..... 243

Abdominal Exclusion of the Fundus in Complete Procidentia. Joseph Riley Eastman, Indianapolis, Indiana 251

Lesions of the Hip-Joint and Their Management. John B. Murphy, Chicago, Illinois..... 263

Typhoidal Cholecystitis. John E. Summers, Omaha, Nebraska 273

Prevention and Cure of Insanity by Surgery. D. C. Brockman, Ottumwa, Iowa..... 283

BOSTON MEDICAL
MAY 7 1930
LIBRARY

Executive Session

DECEMBER 19, 1910—FIRST DAY—MORNING SESSION

The Association met in the ball-room of the LaSalle Hotel, Chicago, and was called to order by the President, Dr. John P. Lord, of Omaha, Nebraska, at 8:50 A. M.

After announcements by Dr. M. L. Harris, Chairman of the Local Committee of Arrangements, of luncheons at the University Club and the Chicago Athletic Club, the reading of papers was begun.

Dr. E. Wyllys Andrews read a paper entitled "Desmoid Tumors of the Abdominal Wall after Operation," which was discussed by Drs. Stewart, Hertzler, and, in closing, by the essayist.

Dr. J. Clark Stewart, of Minneapolis, Minnesota, read a paper entitled "Non-suppurative Osteomyelitis."

This paper was discussed by Drs. Fairchild, Grant, Moore, Mann, Magie, Hertzler, Harris, and, in closing, by the author of the paper.

Dr. Everett O. Jones, of Seattle, Washington, read a paper entitled "Sarcoma of the Appendix," which was discussed by Drs. Hertzler, Beede, McCarty, Macrae, Schwyzer, Root, Jepson, and, in closing, by the essayist.

Dr. Willard Bartlett, of St. Louis, Missouri, read a

paper entitled "The Operative Technic in Acute Suppurative Appendicitis."

This paper was discussed by Drs. Courtney, Van Buren Knott, and Seeling, after which, on motion, the Association adjourned until 2:30 P. M.

First Day—Afternoon Session

The Association reassembled at 2:30 P. M. and was called to order by the President.

Dr. B. Merrill Ricketts, of Cincinnati, Ohio, presented a paper entitled "Surgery of the Mediastinum."

Dr. M. G. Seelig, of St. Louis, Missouri, read a paper entitled "A New Principle in the Action of Antiseptics."

The paper was discussed by Drs. Schwyzer, Benjamin, and, in closing, by the author of the paper.

Dr. E. M. Sala, of Rock Island, Illinois, read a paper on "Definite Knowledge Obtained by Means of the *X*-ray."

This paper was discussed by Drs. Eisendrath, Bartlett, Levings, Root, and, in closing, by the essayist.

Dr. F. Gregory Connell, of Oshkosh. Wisconsin, read a paper entitled. "Subparietal Rupture of the Left Kidney," which was discussed by Drs. Frick, Kreider, Davis, Dunsmoor, Schwyzer, Abbott, Eisendrath, Andrews, Courtney, Moore, Macrae, and, in closing, by the author of the paper.

On motion, the Association adjourned until 9 A. M., Tuesday.

At the annual dinner, President John P. Lord delivered his address. He selected for his subject "Division of Fees and Giving of Commissions."

December 20—Second Day—Morning Session

The Association met at 9 A. M., and was called to order by the President.

Dr. Ellsworth Eliot, of New York City, read a paper entitled "Acute Intussusception, with Special Reference to Adults."

This paper was discussed by Drs. Moore, McArthur, Richardson, Grant, Johnston, and, in closing, by the author of the paper.

Dr. Charles H. Mayo, of Rochester, Minnesota, read a paper entitled "Intestinal Obstruction due to Kinks and Adhesions," which was discussed by Drs. Jackson, Haines, Grant, Dunsmoor, and, in closing, by the essayist.

Dr. B. B. Davis, of Omaha, Nebraska, read a paper entitled "Meckel's Diverticulum as a Cause of Ileus."

This paper was discussed by Drs. Knott, Eisendrath, and Benjamin.

Drs. Archibald MacLaren and Harry P. Ritchie, of St. Paul, Minnesota, contributed a joint paper entitled "Selection of Operation for Inguinal Hernia."

This paper was discussed by Dr. Connell and, in closing, by Dr. Ritchie.

The Secretary presented the report of the Executive Council, as follows:

REPORT OF THE EXECUTIVE COUNCIL

Chicago, December 20, 1910

There were present at the meeting of the Executive Council, Drs. Wright, Grant, Harris, Moore, Mayo, and Oviatt.

The following were recommended as officers for the coming year.

President.....Amos W. Abbott
First Vice-President.....Albert E. Halstead
Second Vice-President.....William J. Frick
Secretary-Treasurer.....Arthur T. Mann

Executive Committee: Malcolm L. Harris and James E. Moore to fill the two vacancies.

The following are recommended for membership:

Eric P. Quain.....Bismarck, N. D.
Vilray P. Blair.....St. Louis, Mo.
A. J. Burge.....Iowa City, Iowa
Maurice Kahn.....Leadville, Colo.
Joseph F. Smith.....Wausau, Wis.
Herman E. Pearse.....Kansas City, Mo.

Some applicants for membership were dropped from the list on account of well authenticated complicity in paying commissions for business. The committee also feels that it may be necessary to enter into this question in connection with some active members of the Association.

A number of members were dropped in accordance with our By-laws for non-attendance, in order to increase the efficiency of the Association.

The Treasurer's report was approved and is as follows:

RECEIPTS

Balance on hand Dec. 20, 1909.....	$617.06	
Fees and dues to Dec. 20, 1910.....	1,245.00	
Extra banquet tickets sold.....	60.00	
Total		$1,922.06

DISBURSEMENTS.

Paid for printing.....	$55.50	
Paid William Whitford for reporting the Chicago meeting	130.44	
Paid for printing 250 vols. of the Transactions	610.00	
Paid for honorarium to the Secretary....	100.00	
Paid for postage, express, etc.....	20.65	
Paid for badges.....	16.40	
Paid for the banquet at Chicago.....	325.00	
Total		$1,257.99
Balance on hand December 20, 1910.....		$664.07

Kansas City is recommended as the next place of meeting, with Dr. Jabez N. Jackson as Chairman of the Committee of Arrangements. The date recommended for the session is December 18 and 19, 1911.

On motion of Dr. W. D. Haggard, the report was adopted.

On motion the Association adjourned until 2:30 P. M.

Second Day—Afternoon Session

The Association reassembled at 2 P. M., and was called to order by the President.

Dr. A. W. Abbott, of Minneapolis, Minnesota, read a paper entitled "Plication of the Anterior Broad Ligament of the Uterus for Retrodisplacements."

This paper was discussed by Drs. Schwyzer, Martin, Dorsett, Grant, and, in closing, by the essayist.

Dr. Joseph Rilus Eastman, of Indianapolis, Indiana, read a paper entitled "Abdominal Exclusion of the Fundus in Complete Procidentia."

The paper was discussed by Drs. Haines, Abbott, Jackson, Harris, Grant, Murphy, and, in closing, by the author of the paper.

Dr. John B. Murphy, of Chicago, read a paper entitled "Lesions of the Hip-joint and Their Management," which was discussed by Drs. Ferguson and Sala.

Dr. John E. Summers, of Omaha, Nebraska, read a paper entitled "Typhoidal Cholecystitis," which was discussed by Dr. W. D. Haggard and, in closing, by the essayist.

At the conclusion of Dr. Summers' remarks, Dr. Lord, the retiring President, said: This finishes our regular program, and I wish to thank you from the bottom of my heart for the excellent program which you have rendered here, for the generous support which you have given the discussions, and for your kind indulgence.

The time of meeting of the next meeting is determined by the Executive Council, and will be December 18 and 19, 1911, at Kansas City, Missouri.

I am going to ask Dr. Mayo and Dr. Haggard to escort the President-elect, Dr. Abbott, to the platform.

Dr. Abbott, in accepting the Presidency, said: I thank you for the distinguished honor you have conferred upon me. (Applause.)

Dr. W. W. Grant, of Denver, offered the following resolution:

RESOLVED, That our thanks and cordial appreciation be tendered to the Chicago members of our Association for their most kind and generous hospitality extended to the members and guests during this meeting.

The resolution was seconded by several and adopted unanimously by a rising vote.

There being no further business, on motion the Association adjourned to meet in Kansas City, Missouri, December 18 and 19, 1911.

President's Address

DIVISION OF FEES AND GIVING COMMISSIONS

John P. Lord, M. D.

OMAHA, NEBRASKA

To the Fellows of the Western Surgical Association:

Your servant, the recipient of your token of friendship, esteem, and confidence, is duly appreciative of your good-will, which is more highly prized than the honor which you have bestowed upon him. While the honor is pleasing and calls forth his gratitude, yet it is the personal quality of your individual and collective good-will, that will abide with him enduringly. This will be a hallowed memory and pleasure when temporary honors are forgotten.

In casting about for a theme to present to you this time it seemed that there was a greater need for me to discuss one of the ethical questions agitating the surgical world today than to add another scientific paper to the number presented at this meeting.

It has seemed to me that specialism, with all the advantages and benefits which it has brought to mankind, enabling specialists to render such distinct service to humanity and thereby enhancing public confidence and esteem, has not been an unmixed blessing to the professional body. The new conditions, changed relations, variable rewards, and re-adjustments in the relationships of patient, family doctor, and specialist, together with new economic conditions, as developed by our numerous public and private hospitals, dispen-

saries, laboratories, corporation work, indemnity insurance, and lodge and society practice, have brought problems for solution by the profession in general and our specialty in particular. The commercial spirit with which the present age is now credited, has added another factor in the control of which, we, with our somewhat neglected code of ethics, have not kept pace. The rapid development of specialism with its special rewards, and the keen rivalry incident thereto, have developed a new order of things professional, the ethical adjustments of which have not yet been generally made.

There has been so much said upon this subject that it would seem almost puerile to attempt to say more. Indeed, it is not my purpose to try to improve upon what has already been so well and so fully presented. Realizing as I do that the practice of fee-division, secret division, joint fees, commissions, so-called dichotomy, graft, and possibly money under false pretences, is increasing at an alarming rate, especially among the younger element, and that in many cities and towns it is the usual thing, I undertake to arouse our members from their seeming lethargy. We teachers and hospital surgeons are established, as a rule, in our respective communities, and have not felt the force of this evil to so great a degree as to compel action. Those who follow will feel it keenly. Many young men are wrestling with this moral problem and will yield to the general trend of practice unless some aroused moral force within the profession or the effect of publicity, checkmates this menace to professional honor, dignity, common honesty, and decency. I agree with those who favor publicity as the speediest and most effective remedy. Then, too, we need some Roosevelts to keep up a rapid-fire attack upon this dishonest practice.

We should maintain a sentiment against any coun-

tenance of graft. Its devotees should not be given positions of honor. They should learn the penalty for dishonesty and unfair and unmanly competition. The present standards of membership of this Association should prevail, though we would do well to revise our membership lists, since we have a considerable number who do business on a commercial basis. Our body is not in a position to reform the other fellows when we, too, are culpable. Scarcely a man among us is in a position to cast the first stone, but there are many who have recoiled from this thing upon the discovery that this temptress had assailed their manhood and their integrity, and that they had actually violated their patients' confidences.

In writing upon this subject several years ago I made the statement that the division of fees was not so bad in itself as that to which it leads. The road is short and direct to the practice of graft. This may be a seemingly harsh term to apply to some of the more respectable forms of secret fee-division; but being secret, however, makes it dishonest and renders possible all forms of abuse. The results of the practice are so manifestly demoralizing as to cause all those who love their profession and cherish its sacred traditions and seek to uphold its honor and good name to array themselves in opposition to those who seem concerned only for the monetary rewards of today.

It has been observed that these practitioners who work upon a commercial basis are too prone to lose sight of the patient, in their efforts to better serve their immediate selfish ends. Their lack of thorough conscientiousness leads them into questionable methods. They handle cases as merchandise, instead of treating them as patients. This causes them to hold on too long before advising operation, and then recommend operation upon a moribund case. Their zeal to have people operated on who are willing, causes them

to work up cases, and this working-up process sometimes is so considerable that they claim compensation for it. The service is oftentimes considered by them of equal or greater monetary value than the skilled and experienced services rendered by the surgeon who has possibly made, or caused to be made, various laboratory tests and has exhausted every resource to complete a diagnosis, having done the operation and given the after-care.

The specialists with their hospital connections and the valuable facilities for advanced and successful work, and the resulting wealthy and large clientele, cause the envious to consider that these men have the best of it, and they are willing to adopt grafting as their most ready means to easy money.

The practitioners who have for years adhered to an inelastic fee-bill find themselves with their financial wings clipped, and unable to rise above the level of customary fees. The specialist is something of a law unto himself and most often gets what he asks. These practitioners therefore avail themselves of the specialists' facile faculty of fee-getting, by requesting the specialist to add a sum for them, as the people would object to paying them a proper amount.

The specialists have often been accommodating in this way, and have saved themselves and the family doctor the trouble of explaining the matter to the patient. The country doctor often plays goody-goody, and says that he will not make a charge for accompanying the case if expenses are paid, of course depending upon receiving a part of the specialist's fee. The specialist's fee is therefore, under such circumstances, unnecessarily large. This gives the patient and all his friends an exaggerated idea of the value of the surgeon's services, and the relatively greater importance of the work of the specialist. The poor country doctor's services therefore become diminutive,

judged by the cheapness of his fees. In other words he is over-shadowed and has cheapened himself.

Doctors of all classes must learn to charge commensurate with the value of their services. Fee-bills hinder in this. It is the union's scale. It bolsters up the incompetent and oftentimes prevents the high-class scientific man from getting his deserts. A hide-bound fee-bill and an increasing lack of appreciation of the practitioner's value dwarf him, and compel him to resort to questionable methods for playing even. He must learn to elevate his standing by special fees for his improved methods of diagnosis and treatment. These have been acquired perhaps by special post-graduate courses, time abroad, and special equipment; and yet his price per visit or consultation is the same as it was twenty-five years ago.

Surgeon's fees may be no greater, but when we come to consider that it is possible for the surgeon to do several cases in the course of the morning, rendered possible by having the command of an unlimited hospital force, we can readily understand how the net results may be much greater than in the earlier days of surgery. On the other hand, the practitioner finds his work more exacting and painstaking, and requiring more time, trouble, and expense.

The rapid development of surgery during the last quarter century, with its greater rewards, has attracted so many to its ranks that competition for business has become so keen as to bring about these trade methods. Too many are now occupying the surgical field to be favored with teaching and hospital positions. Therefore other means must be resorted to for attracting business. This custom of fee-division, however, was probably established by some of the very men holding these places, and now their old weapon is turned against them.

Many of our surgeons throughout the country are

ready-made after a few weeks at some of our large clinics, and then after self-styling themselves surgeons and passing word along the line that they are liberal and fair with the general practitioner, they are soon doing business and are not embarrassed by that period of waiting so well remembered by some of us.

Our medical schools have been remiss in their ethical instruction to students. The subject of fee-division has been eschewed in some faculties for fear of engendering feeling, developing strife, and endangering the integrity of the organization. The same silence has prevailed in medical societies because it might cost something to speak. Students are now without the close contact that was enjoyed in the days of the preceptor, whereas they now need more of the moral side than ever before.

Clearly, so gross a violation of honesty and ethics, if continued, will lead to greater violations of fair play. If our tendency is to lower levels of conduct, it will be but a question of time until our noble profession will be out of favor with the people. There has never been a time when full confidence is more needed because the co-operation and confidence of the people are necessary to secure the legislation needed for conserving the public health. This would aid the people in realizing our dreams of health and resultant happiness from the prevention of disease consequent upon a universal crusade against violations of hygiene and health, and the elimination of all preventable diseases. A mercenary profession unworthy of public confidence will retard this movement, and the unworthy members must be held to account by us and our standards maintained. At present the profession is becoming demoralized and our standards are being systematically assailed. Not only our standards but those who stand for them are attacked and their characters and motives are besmirched.

The graft element is going into medical politics, and some county societies are controlled by them. The old guard is discredited, and lowered standards are set up. The influence of these classes is against the American Medical Association, and their influence is soon to be felt in their organized opposition. The profession of Chicago and some other places do not have to go from home to read the handwriting on the wall.

The demoralization will be more complete when this practice extends to other lines than surgery. The movement has begun and consultation practice and other specialties are now in the throes of this evil. The practitioner will call a man of sufficient standing to enable him to name a fancy price as the consultant's fee, which he collects and then remits the consultant the minimum fee. Any one of us can verify this by personal experience.

The primary object of fee-splitting is to get business. It is unfair competition. It has been my observation that fee-splitters are bad competitors in other ways. They will resort to other equally devious or questionable means of getting patients. They are usually underbidders; they lack sincerity; they are dishonest; they do not stop at dividing with doctors, hotel clerks, hack-men, news-agents, bar-keepers, ordinary clerks, traveling men, medical students, priests and preachers—all are represented, though few of the latter classes stoop to this practice. All classes who do this will lie and will not stop at willful misrepresentation of men of high character and standing. I have had doctors, even those who had graduated under me, lie about me in their efforts to run their prey to the grafter. Doctors go lower and lower who become infected with this vice, and their penchant for easy money becomes their undoing. They have been known to exploit a community until everybody willing is operated upon, or until their methods

become known. Then they sell out, move to another locality, and immediately proceed to beat the bushes for game.

The above, of course, are exaggerated examples of the doctor grafter, but a doctor that grafts at all is dishonest, unethical, will lie, and go out of his way to profit by means of gain. I have had them intercept my patients upon railway trains and divert them after their family doctor had directed them to me; and hack-drivers representing them have undertaken to deliver my patients to grafting surgeons.

The graft spirit has developed alarmingly within a decade, but a reaction has set in. Encouraging reports of progress have come from Chicago, Minneapolis, and St. Paul, and I am pleased to report that a stand has been taken by the faculty of the University of Nebraska and the Creighton Medical College. Whole states are, however, reported in the grasp of the system. Kansas, Iowa, and Missouri, as well as many other states, are enslaved by it. From Kansas, specialists report that division of fees is too mild a term, and that the surgeon must now accept what the general practitioner is willing to give him. They have gone out to bid for business, and the field has become so full of buyers bidding against one another that now they themselves are upon the block. After all, who pities them? They have brought it on themselves.

Hospital service is now required for graduation by some medical colleges; and considerable numbers who have had hospital training and are qualified to do surgery go to our smaller cities and larger towns. To gain a foothold, notwithstanding the prestige of college professors and the large denominational city hospitals, to meet the competition, a resort to fee-division and ultimate graft is the solution. The wail is going up in every quarter from our less enterprising

but more conscientious brothers, and we are now hearing from some of our city brethren who are beginning to observe the rather alarming prevalence of these methods of finance, exploitation of cases, and the merchandising of patients.

After all of this lugubrious, pessimistic, and despairing talk of conditions in our profession I am still hopeful. Doctors as a class are the best people on earth, made so by their education, environment, and every-day training in charity and human sympathy. This evil thing had a very innocent and insidious start. The surgeon wanted to be fair and divided fees that the doctor had in part actually earned. Nobody was harmed, for the patient had not been buncoed nor sold; neither doctor had been overpaid. So all of this was innocent enough. Then came the time when the unscrupulous doctor collected the fee and told the surgeon that the patient could pay nothing, or could pay but little, and kept either the whole or an undue portion for himself, or took the divided fee and then rendered a separate bill. After this he became money-mad and sought subjects on which to satiate his sordid desires for easy gain. Unnecessary and ill-advised operations followed. If the honest surgeon turned him down he sought those who would not, and he has been busy ever since. The surgeon who follows the lines of least resistance in these moral matters soon finds himself in the throes of the system. Many very good but quasi-respectable men follow this practice and persuade themselves that the doctor cannot be paid too much, and they uphold the practice because it suits their convenience and is more profitable. Then, too, they say, "What's the difference?" The difference is most keenly realized when you have to tell your son, as I have mine, that our profession is becoming commercialized.

The prospects therefore are not encouraging for

the profession, and you are compelled to admit that it is not what it once was. Its ideals are lowered. Its ethics may not be maintained, and the best men under these conditions will not be eager to enter it.

These things, if pursued, will cost the profession its influence, and cause loss of respect and confidence of the people. Over-crowding and commercial competition will cheapen services, and with the increase of endowed hospitals, dispensaries and laboratories, rewards for scientific medicine will be reduced. The general profession which is already over-shadowed by specialism will then be in hard lines. Every time a doctor fails to make a proper and independent self-respecting charge for the services rendered by him in the making of a diagnosis, recommending an operation, accompanying a patient to a hospital, being present, or assisting in an operation, he belittles himself, unduly aggrandizes the surgeon, and discounts his own future usefulness, making it that much harder for those who follow him.

To be respected the doctor must be self-respecting and respectable. He is the surgeon's friend, and the surgeon will help him, if he wishes, to be independently, adequately, and respectably paid for his valuable services to the patient and to the surgeon as well. The too frequent present system is wrong, dishonest, cannot endure, and must be stopped for the good of all concerned. It has been my settled conviction for a long time that the doctor is the ultimate loser by this practice, no matter how immediately profitable it may be. He is becoming dwarfed by his own short-sightedness and is becoming asphyxiated by a noose handed him by a crafty specialist, perhaps, but which he himself is now tightening about his own throat.

There has been more harm done than can be overcome by a generation. Delayed action means more sacrifice. The organized profession should busy itself

in reformation and take its stand in our medical colleges, hospitals, and societies; and as individuals and organizations should educate the public and reform our own members. The most hopeful view may be taken of the result. Any practice which even smacks of graft or of obtaining money under false pretenses cannot endure before a righteous public opinion. Nor will it continue in a profession which has cherished ideals from Hippocrates and the whole line of medical saints, religiously followed by that vast majority, during all the ages of the history of medicine.

DESMOID TUMORS OF THE ABDOMINAL WALL AFTER OPERATION

E. Wyllys Andrews, A. M., M. D.

CHICAGO, ILLINOIS

A noteworthy occurrence, one somewhat disconcerting to the surgeon and happily rare, is the appearance of a benign or hyperplastic tumor in a new or healthy wound. I have seen only two cases of desmoid tumor in several thousand abdominal operations, both of which followed herniotomies. The rarity of this complication makes it worth while to report these two cases; most of those so far on record being of another type, followed pregnancy or injury of the fascia above the inguinal region.

Desmoids, or hard white fibroids of the fascia, are analogous clinically, but not anatomically, to two other traumatic or post-operative tumors, keloid or fibromas of the skin and "holzphlegmone" or ligneous abscess seen after wounds in the neck. Under the name *phlegmone ligneuse* Reclus described a peculiar process causing a tumor of wood-like hardness of the fascia of the neck. Schmincke has recently attempted from findings in one case to make out a resemblance to a neoplasm, and classes the growth as "cancer-like" (cancroid). Merkel, continuing the histologic study, found only leucocyte and lymphocyte infiltration, and denied the validity of the cancerous theory, citing the well-known fact that these cases run a benign course. The disease is, in fact, an attenuated microbic infection.

Keloid is also distinct from either "holzphlegmone"

or desmoid in belonging to the skin. Although originating in scar-tissue, as after burns or wounds, it always remains movable with the skin, and grows outward not into the deep fascia.

True desmoids are found not in the skin or external cicatrix, nor in the muscles, but in the fascia and aponeurosis, especially of the abdominal wall.

Nearly all the reported cases have been in women after repeated childbirth. Morrison has recently reported seven cases, one of them a man. This male case was like the two herewith reported in being in the inguinal region, but the subsequent history of recurrence and death makes it probable that the trouble was sarcomatous.

Histologically, desmoid tumors are pure fibromata of the hard white form, like fibromata of other parts, showing coarse whirls of cut fibers macroscopically like uterine myomata, and spindle cells microscopically with numerous fibrillæ between. The cells show oval nuclei. Myxomatous and even malignant degenerations may occur, as in similar growths elsewhere, but commonly they are benign. These growths form tumor-masses often elongated or sausage-shaped, the size of a hen's egg or even much larger. They are often multiple and have a predilection for the upper abdomen, especially the upper rectus sheath behind the muscles. Such growths naturally may be mistaken for intra-abdominal tumors, as of the pylorus, gall-bladder, or appendix, especially one matted by omental adhesions to the anterior wall. The desmoid tumor is not tender, as a rule, and is movable laterally across the rectus, but not longitudinally, so that in thin subjects it can distinctly be made out as a part of the abdominal wall, not a visceral mass.

The desmoid tumors should be removed by operation inasmuch as the tendency is to grow larger and

occasionally to start degenerative retrograde or malignant changes.

The following two cases are alike in causation, both following hernia operation, but Case 1 was not examined histologically, and was not seen by me before the mass had formed. It was possibly not a true desmoid, but a chronic ligneous abscess, like the "holzphlegmone" of the neck.

Case 1.—Male, aged 35, had been operated upon for right inguinal hernia two months before at an advertising institute, which usually practiced the injection treatment. He was told that his case required a cutting operation, and an open method was used and left a scar five inches long above Poupart's ligament. His recovery was very tedious, and after some weeks his friends removed him to Mercy Hospital. He had then a normal temperature and no sinuses. The groin presented a non-fluctuating tumor, not tender or red, which filled the false pelvis on the right side, was immovable, and pushed Poupart's ligament and the fascia lata forward in a mass four by six inches, and firmly fixed to the deep structures. I thought this to be a deep abscess and expected some softening or signs of burrowing under moist warm dressings. The temperature and pulse remained normal, and no tenderness appeared. The leucocyte count was 7,200. No change appeared in the mass in several weeks, and finally I explored the mass by freely incising and blunt dissection, hoping to find and remove some infected suture or other irritating or septic material. The whole groin tissue was a dense fibrous mass of woody hardness with no defined edges. It faded imperceptibly into the adjoining normal parts. It was so hard as to resist blunt dissection entirely by the fingers and could be separated into layers only by considerable force of blunt scissors and a Kocher director. The hardness was due to and accompanied

by a sort of edema, possibly lymph-edema, so that a slight serous oozing appeared on section. No lymph-nodes were encountered. The inguinal canal and ring showed no knots, sutures, or foreign substance. The greater part of the mass was in the layers of the inguinal canal, and behind this in the pelvis outside the peritoneum. Nowhere in the mass was there found any focus of pus or infection or any cavity. The wound healed in a short time after the drainage was removed. No result followed this operation for about a month. The growth for a time was of the same size and consistency. It then slowly began to recede in prominence and rigidity. This process was very gradual, so that it required nearly six months for the last hardness to subside. No appearance of keloid was found in the scar of incision at any stage.

Case 2.—Male, aged 37, entered Michael Reese Hospital in 1909 for right inguinal hernia, for which I performed the imbrication operation. After the operation he appeared with a massive circumscribed tumor in the abdominal wall in and around the inguinal canal. The tumor was three by five inches, very hard, and somewhat movable, but not tender or red. There was no doubt of its location in the fascial structures rather than within the abdomen. The mass was of a wood-like hardness and felt like a neoplasm. It was free from tenderness or redness. No operation was performed. The patient was kept under observation for about eight months. After the third month the size of the mass slowly receded, and finally disappeared by resolution.

DISCUSSION

Dr. J. Clark Stewart (Minneapolis): I think the point of greatest interest in Dr. Andrews' report is the analogy which he possibly shows between this class of tumors and keloid as to etiology. Keloid, we know, arises largely from scar-tissue, and if we can show that any class of fibroid

tumors arise also from the seat of traumatism, it will be an important point in their etiology and in their analogy to keloid. I doubt whether the term *desmoid* should be generally used. Desmoid is an old name that has come down to us as a clinical term, which means just one thing, and I think it should be reserved for that one thing, because it has no clear clinical or pathological meaning, to my mind, disassociated from that one clinical condition. The original desmoids were tumors of the posterior sheath of the rectus muscle, and my memory differs from Dr. Andrews' when he says that the majority of them are found in the upper part of the abdomen. The majority of the reported tumors that I have run across have been found in the lower half of the abdomen. These tumors have marked pathological and clinical characteristics. Clinically, they grow inwardly, so that ultimately they become covered only by peritoneum. They attain considerable size and have no clear capsule, and their surgical removal is a serious undertaking, as the problem of closing the peritoneal gap is often a very difficult one.

Histologically, these tumors are characteristic: they are all fibromata of quite cellular type. The vessels are very largely of the sarcoma type, having no distinct walls, but though, according to the early histories, many recurred, the reason for these recurrences seems plain,—incomplete removal due to their lack of encapsulation.

I was very much interested in the statement made by Dr. Andrews with reference to these inguinal tumors being non-encapsulated, and hence liable to incomplete removal and consequent recurrence.

The use of the word *desmoid* as originally applied to tumors of the abdominal wall may have some value, but when you attempt to apply this term, as it was done in an article I saw a short time ago, to tumors around the shoulder-joint, you lose all the clinical significance of the term *desmoid,* and you had better call them *fibrous tumors.* The etiological factor is the one of interest to me, that these inguinal tumors come after a hernia, after an operation for hernia, consequently after traumatism, and hence can be considered analogous to tumors of the rectus muscle occurring after pregnancy, as most of these tumors did where there were lesions of the rectus sheath from which the tumor may have originated. In addition, the possible analogy shown to keloid makes this whole subject one deserving of the most careful study.

Dr. A. E. Hertzler (Kansas City, Mo.): A German writ-

ing in a recent journal ascribes these tumors arising after a hernia operation to a low grade of infection. Silk ligatures were found in some instances in the centers of these masses. Desmoids are not associated with inflammatory processes and may go on to a continued growth, differing in this latter respect from the groin tumors, which tend to regress. Histologically, the groin tumors are more cellular and are marked by a greater variety of cells which characterize an irritative process. The desmoids are often very cellular, but more often are made up largely of fibrous tissue with sparse spindle nuclei.

The histogenesis of these inflammatory tumors is a matter of interest. They occur in the presence of low grades of inflammations only. An irritation sufficiently great to cause an exudate which is capable of being coagulated, forms a fibrin. If the irritation is greater, the power of the exudate to coagulate is lost, and fibrous tissue is produced.

Dr. Andrews (closing the discussion): I will not take up any further time except to reply to one point made with reference to the identity of keloid with desmoid. Clinically, I will repeat what I said, that keloid, although it appears in scar-tissue, never involves anything but skin. I think I am right in asserting that all keloids remain confined to this layer, no matter how extensively they may develop in size, and they are movable and free.

It appears to me that there is probably no such pathological entity as desmoid. My two cases were not quite desmoid as the term is understood by surgeons, but they were more of the nature of these perverse chronic inflammations, for both of them disappeared without removal by the surgeon.

NON-SUPPURATIVE OSTEOMYELITIS

J. Clark Stewart, M. D.

MINNEAPOLIS, MINNESOTA

Three distinct clinical conditions may be classed under the title of non-suppurative osteomyelitis:

I. Cases of ordinary osteomyelitis in which, owing to the non-virulence of the invading germ or to unknown conditions increasing the resistance of the individual, no necrosis is caused. In such cases there is no pus, and no sequestrum, but, instead, in a certain number, marked irritative reaction is set up, and there is great overproduction of bony tissue, resulting in a thickened, dense, and painful enlargement of the bone attacked. These cases are quite common, regularly recognized, and properly treated.

As an illustration of this form of disease the following case is instructive:

Case 1.—Mrs. B., aged 30 years, had a septic abortion with marked constitutional symptoms, including an infected knee-joint, accompanied by enlargement and pain of the adjacent femur. The knee was aspirated and seropus found, and the patient was cared for until her fever subsided. At this time she came into my hands with a subluxated and stiffened knee. and thickening and pain in the femur above. The deformity was corrected by extension, rest, and manipulation, and a very fair result obtained as to position and function. The femur remained enlarged to about one and a half times its actual size in its lower third, but all fever subsided and no abscess appeared. There was a gradual improvement as to pain in the limb until about four years later, when she fell and struck this thigh, in which a swelling in the soft parts at the outer side then developed, and finally a small sluggish abscess leading to a small sinus in the bone. This was opened and chiseled out some inches through a fairly dense bone. It terminated in a small cavity not over a quarter of an inch in diameter, containing only pale granulation-tissue. Curettage and packing caused this to heal in about three months, and the limb has remained well for the last ten years.

There seemed here to be a small quiescent focus left by the old infection, which had caused, by irritation, much new bone-formation, but no pus or sinus until it was again stimulated by the slight injury. The same conditions are frequently seen about the chronic bone-abscess where the pus has become sterile, but still acts as an irritant and causes new bone production.

II. Cases of injury, generally fracture, clinically where a small piece of bone is entirely separated and dies, forming about it a closed cavity of dense new bone in which it lies until absorbed, but without suppuration.

Case 2.—This case illustrates the above point beautifully. A man, aged 35 years, received a forcible bending of the leg, causing a subperiosteal fracture of the tibia without displacement. Under ordinary treatment he made a prompt and apparently perfect recovery, but kept returning, complaining of pain at the seat of fracture, especially at night. Six months after the accident I opened the tibia, there being no manifest lesions of the periosteum or dense cortical bone, and found a small fragment of bone less than one quarter of an inch in any dimension, lying in a cavity walled off from the medullary canal by dense, ivory-like bone. This cavity was scraped out and allowed to heal by blood-clot organization. The patient has remained well over five years.

This man had no fever at any time, and the only symptoms pointing to the conditions were constant pain, worse at night, and point-tenderness on pressure over the site of the fracture, the latter being only marked toward the end of the six months.

Case 3.—Almost exactly the same conditions as in Case 2 were found in a young woman, aged 29 years, who struck her tibia on a stone step, causing a bad bruise and slight abrasion of the skin. About eight months later she came into my care suffering with pain at the site of injury, which was worse at night, but with no local swelling, either in the bone or soft parts. She had slight point-tenderness over a small spot at the middle of the tibia, and her temperature was quite regularly above 99° F. every afternoon. Operation showed the periosteum and the cortical bone normal with a small cavity less than a half inch in diameter containing granulation-tissue and a very small sequestrum. This cavity was entirely shut off from the balance of the medullary canal by dense bone.

These cases differ entirely from those of the first class in that the irritant, which causes new production of bone, is not bacterial, or, at least, not primarily so, but is a fragment of bone, which remains practically aseptic.



Fig. 1.—Anteroposterior view of tibia, Case 5, showing unabsorbed bone-wax at bottom of cavity over eight months after operation. Note light area about the wax, as not yet calcified.

Fig. 2.—Lateral view of tibia, Case 5, showing complete filling of cavity by new bone covering the bone-wax at the bottom of the gutter made at operation.

III. The third class, and the one to which I especially wish to call the reader's attention, differs entirely from the two previous classes by having no notable beginning, but an insidious onset. The disease is essentially chronic, but progressive, and is regularly misdiagnosticated and treated as rheumatism.

I have seen the lesions present in the tibia only, but this must be accidental, as it might as well occur elsewhere. Any etiological factor seems absolutely wanting, as the two cases narrated have nothing in common, while the pathology and the symptomatology are identical.

Case 4.—Mrs. B., aged 38 years, two years ago was quite sick with the grip in Montreal, and after recovery suffered from rheumatism in her legs, for which she was treated and apparently relieved. During the past two years she had repeated attacks of pain in the right tibia, and during the past six months these had been more severe, and she had nearly always pain in this leg, especially after exercise and at night before storms. Careful examination showed slight roughening along the crest of the tibia, slight fusiform enlargement extending over the middle third, and marked point-tenderness at various spots over the enlargement. Her evening temperature varied from normal to 100° F., generally being about 99° F. The other tibia was smooth and had never pained her. Potassium iodide was pushed for one month, without relief, and then an operation was advised and accepted. The tibia was guttered for about five inches, the conditions present being an obliteration of the medullary cavity, shut off by dense bone at each end of the area involved. In the former medullary canal was a series of irregular cavities formed by spongy bone and filled by what looked like red marrow. No histological examination was made. The gutter was packed with iodoform gauze, and healed completely in four months.

The patient remained under observation for seven years, and had no further trouble. Complete relief from the night pains followed.

Case 5.—Mrs. R., aged 25 years, came to the dispensary in the summer of 1909 for a painful tibia, diagnosticated rheumatism. She gave no history of any onset, except a slight injury three years before, but said she had had pain in the leg for the past year, worse in rainy weather and at night. No history of syphilis; no children; no abortions.

Examination showed the left tibia to be much enlarged over its middle two quarters. This enlargement was fusiform, but irregular and nodular. The tibia was very tender to fingertip pressure all over the enlargement, and more tender at certain points. The opposite tibia was smooth.

No evidence of syphilis. Potassium iodide was tried for six weeks, but had no effect. The temperature at the dispensary at 2 p. m. was always normal. She was admitted to the University Hospital and operated upon by the writer. The conditions were identical with those in Case 4, except that there was more subperiosteal overproduction of bone, which caused the irregular nodes. The bone was also softer and less compact. The tibia was guttered for six inches, the spongy bone curetted away, the cavity swabbed out with carbolic acid and alcohol, dried, and filled with Moorhof bone-wax. The periosteum and skin were then sutured without drainage. The patient made a slow recovery, as a few skin sutures cut out, exposing the wax, which had to be covered by granulation. She finally was discharged well, and has remained so up to date.

An examination of this patient on January 3, 1911, showed the bone smooth and non-depressed at the seat of operation. The skin was freely movable over the bone and showed no evidence of delayed healing. Skiagrams taken at this date showed the bone-defect smoothly filled in by new bone, and the remnants of the bone-wax, still unabsorbed at the bottom of the cavity, completely covered over by new bone.

Cultures taken from the bone-cavities of this case showed a staphylococcus, believed to be *staphylococcus pyogenes albus*. The red tissue appeared to be a mixture of marrow cells and red and white blood-cells, not resembling granulation-tissue.

Now, it seems to me that these two cases of the third class are of a type of chronic osteomyelitis not recognized by the text-books on surgery, the nearest approach to a description of them being called *chronic osteoperiostitis,* which is certainly a misnomer, for in these cases the periosteum is regularly normal. Their characteristics, pathologically, are the transformation of the marrow cavity into a multicellular labyrinth filled with a tissue which, macroscopically, resembles red marrow. There is also a synchronous subperiosteal production of bone, which results in a fusiform enlargement, the new bone being spongy and not dense.

Symptomatologically, they are characterized by insidious onset and so-called rheumatic pains, which are worse in damp weather and at night, with slight evening rise of temperature. While each of the two cases cited give a history of an acute causative agent, in neither could this be said to stand in an un-

doubted etiological position, as the local symptoms in each case occurred over two years later. What would ultimately happen to a case of this kind without operation can only be surmised. Neither case showed any apparent change during the several months under observation, and it seems probable that the bone would merely remain enlarged and painful until stirred up by a fresh injury or infection, when there would be suppuration, and a sinus would be formed.

Diagnosis is easy after syphilis is excluded by the non-effect of the iodides. Tuberculous osteomyelitis regularly causes cold abscess and sinus-formation, while periosteal sarcoma is generally more rapid and can be eliminated by the use of skiagrams. A fusiform enlargement of a long bone, increasing very slowly in size with point-pressure tenderness at various places over the enlarged bone and slight rise in the afternoon temperature, gives a characteristic picture.

The treatment is, as noted in the cases cited, opening the bone and following the morbid process each way until normal bone is reached, cleansing, drying, and filling the cavity with Moorhof wax for union by first intention.

The technic of the use of the Moorhof bone-plug in these cases is as follows: An Esmarch rubber bandage is used, and all necessary excavation of the bone is completed. The Esmarch bandage is then removed, and the cavity in the bone is packed with gauze, while all bleeding from the soft parts is checked by ligature and pressure. The bone-packing is then removed, and the cavity swabbed out with pure carbolic acid, followed after one minute by alcohol, used freely. The cavity is then dried by pressure, alcohol, and hot air, before the wax is poured in. The periosteum is then sutured over the wax, the skin

closed without drainage, and the limb put up in a plaster-of-Paris dressing for complete immobility.

DISCUSSION

Dr. D. S. Fairchild (Clinton, Iowa): This certainly constitutes a very interesting class of bone defects, and they seem to be due to a number of causes. They seem to be due to some irritation that produces a proliferating inflammation of the bone, and are oftentimes associated with inflammatory changes taking place in the periosteum, as well as in the endosteum. I have seen a number of cases of this kind which seem to have arisen from a trauma or from some injury which has been inflicted to the bone and in which the periosteum has been involved to some extent. The trouble seems to extend throughout the shaft of the bone, the tibia being most commonly affected because it is more subject to traumatic influences. In these cases, according to my observation, the bone is dense; that is to say, if the trouble has existed for a long time the bone becomes dense throughout its entire thickness. In the younger cases where the disease has not been very progressive for a long time, the bone will be softer. When the medullary canal is examined, in this disease it is found almost entirely occluded by the proliferation of bone-tissue. It seems to me more like an osteitis in which the inflammation has extended, not only into the medullary canal and from the periosteum, but into the bone substance itself, because the cases I have seen of long standing have shown great density of the bone, so that when a gutter was tunneled out it required a considerable amount of chiseling. It was with some difficulty that we could cut open the bone to any considerable extent. Syphilis, no doubt, is a prolific cause of this sort of difficulty, and yet we often meet with cases where there is no history of syphilis, and also where the iodide-of-potassium test shows that it could not have been of syphilitic origin, so that we seek some other cause than syphilis. It is possible the condition we call *rheumatism* may have had something to do with this condition of things.

In the class of cases the doctor speaks of in connection with spicula or fragments of bone that have been left behind following an injury, those are usually to be accounted for; but the latter constitute a class of cases where the symptoms have been apparently those of rheumatism. The patient has complained of deep pains in the bones, and these pains continue perhaps to be the chief cause of the patient's seeking advice.

A patient comes to you and you find enlargement of the bone, which may give rise to the idea of sarcoma, and yet the long continuation of the affection and its characteristics show it is not sarcoma, but is really some inflammatory process in the bone, and does not produce pus. The ordinary pus germs do not seem to have been the cause of the difficulty, so that there is some form of toxemia which produces irritation and leads to the formation of a thickened amount of bone-cells and resulting sclerosis, the sclerotic process taking place in the whole extent of the bone. The treatment that has been suggested, of cutting down on to the bone and chiseling out a gutter, has given the best results. I remember one case in particular where we tried to do this three or four times before the patient finally got relief, and yet the density of the bone did not clear up; the bone still remained enlarged, but the pain disappeared, improvement took place, and the suffering was relieved. Now, sometimes the bone dies on account of the Haversian canals being obliterated, compression of the vessels leading finally to the death of the bone, cutting off its vascular supply. While these cases are not very common they are yet common enough to constitute a matter of very considerable interest to the medical profession.

Dr. W. W. Grant (Denver, Colo.): The trouble is that, except in acute osteomyelitis, the condition is not understood and the diagnosis is not made early; and that is why we do not see more of these cases of non-suppurative osteomyelitis, as mentioned by the essayist, for, in my opinion, if you will give them time there will be ultimately developed death of the part and either pus or a sequestrum and involucrum. We saw these cases formerly much oftener than now, because then no one thought of operation until there were several sinuses leading to the canal. That was formerly the usual condition found in dealing with these cases. Today the diagnosis should be made earlier, and if it is, operation should be done earlier, and the patient will be saved several months and years of suffering and will finally get well with a better leg and a better-looking leg.

It is necessary to exclude syphilis and tuberculosis, especially in arriving at a proper diagnosis. We know that tuberculosis, which begins in the epiphysis, is much more likely to suppurate. Syphilis will involve the periosteum, often primarily, and it is not so necessary to operate in these cases. Specific treatment will cure them.

I wish to speak of the concluding portion of the operation

when it is done. I have had several cases in the past year that interested me greatly. In two cases, one and three years before coming to me, the surgeon had simply made an incision through the skin and periosteum, because he did not recognize the fact that the disease was an osteomyelitis. The result was, these patients suffered intermittently, and more severely at night. Frequently the pain is aggravated, and when there is pus pent up, with no fistula, I know of no condition in which pain becomes more unbearable. These patients will get no relief until there is perfect drainage and evacuation of the pus.

Dr. Stewart speaks of the usual method of packing the cavity. I want to dissent from this old way of making a gutter in the bony canal. In recent text-books you will find this method of treating these cases approved. After excavating, curetting, and chiseling out the diseased bone, a flap is turned in to the bottom of the canal, hoping by a plastic method to get a good result, which usually will be realized, but you will get a disfigured bone and leg. My own method, no matter whether there is pus or not, is not to pack the canal. You will have enough oozing of blood, if your canal is left clean and aseptic, to fill this up and become organized. My own rule is invariably, in the septic and pus cases, to put in a small drainage-tube at one or more places in the canal, but to bring carefully the periosteum of the bone together by chromicized catgut, united separately from the skin, and then to unite the skin, usually, by subcuticular stitch of silkworm gut. I can show cases treated in this way the past year in which we have a leg that looks as smooth and round as the other leg, and there is no disfigurement as occurs by permitting the skin to heal in the bottom of the bone cavity.

I mention this because, to my mind, it is perfectly feasible, and the periosteum will take care of the cavity, and the patient will have a much better looking leg and just as good a result.

Dr. James E. Moore (Minneapolis, Minn.): I have been greatly interested in this line of work. I think Dr. Stewart properly classifies this chronic inflammation of bone as non-suppurative osteomyelitis. The whole history indicates that when it is non-suppurative it means either that the infection was a very mild one or that the resisting power of the patient was so great as to overcome it. The older writers called it *condensing osteitis.*

The principal difficulty in diagnosis is between non-sup-

purative osteomyelitis and chronic bone abscess. Of course, the therapeutic tests will eliminate the syphilitics, and, as a rule, syphilitic disease of the bone is bilateral, whereas this condition we are discussing is usually unilateral. Chronic abscess of bone is likely to be limited to one end of the diaphysis, and the conditions he speaks of affect the whole diaphysis. The history of the case is that of a low form of inflammation and gradual enlargement of the part, the principal symptom being pain at night.

When we come to operate upon these cases we find, as Dr. Fairchild has pointed out, in the majority of cases that the main part of the bone proper is eburnated, so that late writers speak of it as an *eburnating osteitis.* The older surgeons amputated a great many of these limbs on account of the great pain. The modern surgical treatment is such as that which Dr. Stewart has portrayed in his last case. I am sure, in those earlier cases in which the bone cavity was packed, the patients did not do quite as well as they do now when we use the Moorhof bone-plug, and modern methods of dressing bone-sinuses. It matters not what the cause is, aside from malignancy, we are led to make an opening in the bone, and if we get a clean cavity, use the Moorhof bone-wax, and institute timely drainage, we shall get nice-looking limbs on an average.

From my experience in one of my cases it would seem that there is a special tendency in certain individuals to develop this slow form of inflammation. I first operated on this young lady in Minneapolis. The bone was found eburnated in one leg, the medullary cavity being involved, and there was a little pocket left, filled with granulation-tissue, seemingly. The case was treated in the usual manner, and she made a good recovery. It took her a good while to get well, but she was relieved of pain immediately after the operation. Some years afterwards I was requested to operate on her in Denver, Colorado, for the same condition on the other side. Just recently I heard she had the same trouble in both legs. It is a number of years ago since I operated on both of them. There are certain individuals who have unusual power of overcoming bacterial infection, but I am sure you will agree with me that it is not so easy for some people to overcome this peculiar variety of infection.

Dr. Arthur T. Mann (Minneapolis, Minn.): In the last six months I have had two cases in which I have used this bone-wax, both of them being cases of this type of osteomyelitis, one in a girl. thirteen years of age, who had had symp-

toms for two years and had been under the observation of another physician, who spoke to me about her six months before I saw her. She had the usual symptoms of chronic osteomyelitis in the lower third of the tibia, and with the pain worse at night, and so on, the temperature running up to 102° at times. As a rule, however, the temperature was not as high as that. Six months later, at the end of two years, when I saw her she had a fusiform swelling at the junction of the lower and third quarter of the tibia, which was tender, and for which she was crying at night with pain. On opening this there seemed to be a mass of more or less cancellous tissue, more dense than the usual tissue, but thinner by a good deal than the ordinary cortical bone, so that the cortex had thinned out and the medullary cavity had filled in. In the center of this there was granulation tissue of very limited quantity. That is all. The case had run on for two years. The whole area was scooped out and then filled with twenty per cent bone-wax, twenty per cent of iodoform, and twenty each of spermaceti and oil of sesamum.

The periosteum should always be closed over this, and the tier sutures used just as we close the abdomen. The original dressing was taken off and returned, and left there until the end of the first ten days. There was healing by first intention. Six months later I heard from the girl, and she was well. The pain stopped immediately following the operation. This was a case in which there had never been suppuration.

The other case was in a young man, twenty-eight years of age, who twenty years before had been operated on for the relief of a pathological condition at the lower end of his femur. At the end of three weeks suppuration had occurred, and the doctor did one more operation which he thought was a bone operation. We had a rather indefinite history of suppurative osteomyelitis twenty years before, with no recurrence during the twenty years; then two weeks before, pain began at the knee and in the popliteal space. When I saw him at the end of two weeks he was tender in the popliteal space—just moderately so. He was tender over the internal condyle, and I put him to bed with the hope that the inflammatory condition in the popliteal space would clear up, and that I should not have to go into the popliteal space. This did clear up, and in ten days there was no tenderness on pressure in the popliteal space. Then I went into the internal condyle, and found something which corresponded to the red bone-marrow, more red than normal red bone-marrow, but no pus; and I felt quite dissatisfied because it seemed that I had

not found enough to warrant operation. I filled in the hole with bone-wax, and sewed it tight in layers. The old pain ceased at once. He had less pain the night following the operation than the night before operation, and in two or three days there was no pain whatever. There was healing by first intention.

The idea in using bone-wax is to fill up the cavity with some substance which will not become septic and in which granulation-tissue and bone-forming tissue may grow exactly the same as we make use of the idea of an old blood-clot filling the cavity, but the bone-plug seems to be much better for this purpose, as it is safer from infections than a blood-clot.

Dr. William H. Magie (Duluth, Minn.): I wish to speak of a form of treatment which I adopted in one case recently. This case had been troughed by myself, and later by Dr. Judd, of Rochester, Minn. Recurrence took place four or five months afterwards. The patient then returned to me with the symptoms all re-established and magnified. At the examination I found the tibia for fully eight inches in length enormously enlarged, and it really looked as though it might be a sarcoma. I adopted the plan of not troughing the tibia, but chiseling down at the extreme end of this enlargement above and below then removing half of the diameter of the tibia, splitting it, not troughing it, then I applied the skin direct upon the raw surfaces of the bone that had been left after removing half of the diameter of the tibia over these eight inches in length. The wound healed perfectly by first intention, and pain was immediately relieved. He has been perfectly well since and is working at his occupation in the woods as foreman of a lumber crew of loggers. It seemed to me it was not sufficient to trough the bone in this case as I could not get all the diseased bone away. There is not anything in the medullary canal to remove except the new growth of bone, which is replaced again by still further new growth It occurred to me that by removing this tibia in the way I did we could get relief from the pressure-symptoms, at the same time leaving the tibia nearly the normal size. I hope that in the future, if I have the opportunity, I may again try this method of bone-removal.

Dr. A. E. Hertzler (Kansas City, Mo.): In discussing the pathogenesis of this condition, I do not think we shall go very far astray if we call it a *desmoid* of the bone. If the tumor in Dr. Andrews' case had occurred in the medullary

cavity, we should have had this sort of trouble. The so-called albuminous osteomyelitis and periostitis have been recently rather fully dealt with in some of the German papers, and I have been able to demonstrate bacteria in some of the cases I have seen, and have succeeded in making a culture from cases of albuminous periositis. This culture when injected subcutaneously in a rabbit, produced a desmoid after the tumor described by Dr. Andrews. Likewise in a bone-abscess which causes a localized globular enlargement, you have there a sclerosing process which is due to a slight irritation, and I believe if care is taken in these cases, in the bacteriological examination, bacteria will be demonstrated. But great care must be taken. They do not grow usually in ordinary room temperature. Frequently, as far as I know, they are not pathogenic to animals. They do not kill the animal, but simply produce a local reaction. What happens, as far as I am able to demonstrate, is something like this: with certain types of low-grade inflammation you get the fibrillar type of fibrin which is organized into fibrous tissue. A more intense type of inflammation gives you the granular type of fibrin which is absorbed. Now, as the history in Dr. Andrews' case very well demonstrated, he had a relatively acute type of this disease, the process occurring in three weeks. A more chronic process would have taken six months or longer. In his case, if tissue had been obtained in five weeks, granular fibrin might have been demonstrated in contradistinction to the fibrillar type of fibrin. In this chronic sclerosing type of bone disease we have a milder form of infection which produces an exudate which is capable of being organized and which is not seen in the more acute types which form an exudate, and which is not organized. These conditions, I think, can be rather clearly followed out if one takes the trouble of applying tinctorial chemistry to these various tissues. Rather unconsciously, I suspect, in the use of the Moorhof bone-plug you are imitating in a measure a very mild type of infection. What the iodoform does has never really gotten into the literature, but it does produce an exudate which is capable of being thrown down into the fibrillar type of fibrin, and not the type of fibrin which is produced by active hyperemia acting as a substance which produces an exudate without forming this type of fibrin that healing has brought about. This type of fibrin apparently, as you see, acts not as a germicide, but as a bacterial inhibitant, and it is perhaps an expression of this. We find chronic processes where the breaking down does not occur. The tissue of this

type is able to take care of these milder types of infection. In all of these cases of bone-infection I believe it is becoming more clearly demonstrated that they are of bacterial origin. I know of no case that has been reported where there has been a careful attempt at bacteriological demonstration that has not succeeded.

In the treatment of these conditions I followed the method of Murphy, using carbolic acid followed by alcohol, and closing the skin fully; and my experience has been that in nine cases out of ten we get complete permanent primary union. If one does fail, he is no worse off than if he started with packing in the beginning. I believe if more careful operations were done our success would be even greater than the percentage I have mentioned, namely, nine out of ten.

Dr. M. L. Harris (Chicago): These cases of non-suppurative bone-lesions form a very interesting group. We may recognize two sub-groups. The first in which trauma is a distinct part of the history, in which there is usually an enlargement of the bone macroscopically, in which there is condensation of the bone, and in which there is or is not a macroscopic focus of suppuration. The picture of these cases has been well worked out by Tavel in his work on the staphylomycoses. The majority of cases which have run an extremely chronic course, in which a microscopic abscess was discovered, but no macroscopic abscess found, have been found to be due to the white staphyloccocus, the organism which Dr. Stewart found in one of his cases. The second sub-group includes what has been called and graphically described by the French as *osteomylite douloureuse*. In these cases there is no material enlargement or condensation of the bone. The shaft of the long bones is the part usually affected. In the interior of the bone we find red marrow, as Dr. Stewart has mentioned in one of his sub-groups. The marrow is of an exceedingly red color; it is very soft and is almost semiliquid in some cases. These cases are characterized by very great pain.

The most interesting case of that kind, and a very typical one, which I saw, was in a man, affecting the humerus. He was past middle age. He had been treated for syphilis, had been sent to Hot Springs, to Europe, and had visited several watering-places, but no relief was experienced. There was extreme pain in the shaft of the humerus which was completely and permanently relieved by opening the medullary canal. These cases are sensitive when the bone is percussed with a hammer or on deep pressure. They do not require, in

the operation, the cleaning out of the medullary cavity. All that is necessary to do is to open the medullary cavity. By relieving the tension, these cases recover. It is unnecessary to pack them, and it is unnecessary to clean out the medullary cavity, as I have said. They make a rapid recovery as soon as the medullary cavity is opened. The pain seems to disappear as if by magic, and does not recur. In the first subgroup it is necessary to clean out the medullary cavity, because in perhaps all of those, while we call them non-suppurative, there is microscopic pus-formation. At least, they are all bacterial in their origin. The bacteriology of the second subgroup, or the osteomyelite douloureuse of the French, has not been carefully worked out, and it is not known whether they are of bacterial origin or not.

Dr. Stewart (closing the discussion): I am very grateful to the members for the interest they have taken in this subject and for the variety of discussion. My paper, however, was not on the treatment of osteomyelitis, but I made a plea for the recognition of a definite form of the disease, and most of the gentlemen discussing the paper did not notice one point about these two cases, which are absolutely identical in every way, namely, they did not have sclerosis of the bone. The bone was thickened, but not sclerosed. The bone was more porous than normal.

In these two cases a peculiar thing was the large extent of the medulla of the bone attacked, transforming the medulla into a sort of labyrinthine cavity full of tissue, which looked like red marrow, and which, microscopically, showed evidences of chronic inflammation and gave cultures of the white staphylococcus. These cases are peculiar, and my paper was for the purpose of drawing your attention to these two cases as a type of chronic osteomyelitis, which is not recognized very well.

Dr. Grant did not listen to the reading of my paper very carefully. The cases that were packed dated back fifteen or eighteen years. I have not packed a bone case in many years. I use the Moorhof bone-plug, sew the periosteum and skin over it, and get primary union under the first dressing. Dr. Grant confounds the word *recognize* with the word *understand.* The diagnosis should be easy if you know there is such a condition. There are a great many things we do not understand, but we may *recognize* conditions that we do not *understand.*

I wonder if the remarks of Dr. Hertzler in regard to

iodoform as being essential in the Moorhof bone-plug, are correct. We have experimented with other forms of bone-plug, and the results are not very different from those of iodoform, and the absolute quiescence of the bone-plug for many months in some cases has rather negated the idea of there being any active exudate around it. I have seen these bone-plugs stay absolutely unchanged, as shown by repeated skiagraphs which we can measure, for a year, absolutely quiescent, non-absorbed, or changed in any way. That is not the usual history, but I have seen that happen, and I have wondered if iodoform is essential to the results which we get after the use of the bone-plug.

PRIMARY SARCOMA OF THE APPENDIX

EVERETT O. JONES, M. D.

SEATTLE, WASHINGTON

Sarcoma of the intestinal tract is not common, and a primary sarcoma of the appendix is an extremely rare occurrence. Nothnagel, in his enumeration of sarcoma of the alimentary canal, does not note a sin case. From time to time, cases of sarcoma of the appendix have been reported, but in the majority of these the descriptions of the microscopical findings have been indefinite and unsatisfactory. In 1893 Gifford reported the first authentic case, and the first recorded in America was reported by J. C. Warren, in 1898. Up to the present time eight cases in all have been recorded in the literature, four of which were reported in this country.

Because of the rarity and special interest attached to sarcoma of the appendix the writer deems the following case of sufficient interest to merit reporting.

Mrs. F., 26 years of age, was referred by Dr. Taggart of Bremerton, Wash. Her family history is of no importance except that her father died at the age of 53 of a metastatic sarcoma of the retroperitoneal lymph-glands, which resulted from a primary growth in the testicle.

The patient herself had the usual diseases of childhood, and also suffered from a severe attack of typhoid fever, but otherwise enjoyed good health until four years before the time I first saw her. While running to catch a boat her foot slipped and she fell striking her side against an upright post on the dock. She had

to be carried home, and she suffered so much pain that a hypodermic of morphine was required to relieve her. Pain and tenderness persisted in the lower abdomen for two weeks. A few months later a similar attack came on spontaneously, and during the following four years she averaged an attack about once every six months. These attacks were quite uniform in character and began suddenly with pain in the lower right abdomen. Nausea was present, but never vomiting. There was always marked local tenderness, and usually considerable general prostration, which often persisted some time after the pain had subsided.

When I first saw her, in March, 1910, she had been sick for three weeks with symptoms quite similar to her previous attacks, except that it showed no disposition to abate. She was confined to her bed, suffered constant pain in the right lower abdomen, and felt extremely weak and prostrated. The appetite was poor, and the bowels were moderately constipated. The patient was pale and somewhat emaciated, and the abdomen flat. Inspection disclosed at once a small tumor apparently the size of a walnut situated at McBurney's point. This tumor was hard to the touch, quite immovable, and very tender. There was moderate muscular rigidity over the lower abdomen. The percussion-note was everywhere normal. The pulse was 100, and the temperature normal. Further physical examination revealed nothing abnormal. The blood examination gave hemoglobin 70 per cent; red blood cells, 4,000; whites, 12,000; polynuclear neutrophiles, 78 per cent. Her physician assured me that her temperature had been normal throughout the attack, and that this was also the case in two previous attacks during which he had attended her. The visible and palpable tumor had only been evident during the last two weeks. A diagnosis of recurrent appen-

dicitis, with probably a small circumscribed abscess, was made, and appendectomy advised.

Operation (March 15, 1910) disclosed the head of the cecum covered with what appeared to be adhesions, which were peculiarly friable, and out of the center of which the appendix was excavated with the finger. As the appendix was being freed, two or three drops of a milky-white fluid exuded from the mass. The appendix when separated was found to be of the same peculiar friable consistency as the mass in which it was buried. Suspicion of a possible malignancy was aroused by the peculiar appearance of the tissues, but, not feeling certain, the wound was closed after a simple appendectomy. The specimen was submitted at once to microscopical examination. The report being sarcoma, five days later the wound was re-opened and the cecum resected, the ileum being joined to the ascending colon by lateral anastomosis.

The subsequent recovery of the patient was uninterrupted. She left the hospital at the end of the third week, and at the present time reports herself as enjoying better health than at any time during the past four years.

Microscopic section showed the growth to be a pure spindle-cell sarcoma, composed of solid masses of cells, containing large vesicular nuclei, and with here and there a fine fibrillar intracellular stroma. Serial sections made through the appendix and the adjacent walls of the cecum showed the growth to have originated in the submucosa of the appendix about midway between the base and tip. It grew outward, invading successively all the coats of the appendix until the serosa was involved, and then extended to the serous covering of the cecum, probably because preexisting adhesions had already bound the appendix in its whole length to the wall of the cecum. Sections through the appendix taken at the edge of the tumor

show columns of cells growing outward from the submucosa and infiltrating the inner muscular coat; also sections of the cecal wall show the tumor invading the serosa with here and there groups of cells infiltrating the outer muscular layer; no tumor cells were found at a deeper layer in the wall of the cecum. The mucosa of the appendix was everywhere uninvolved, though considerable round-celled infiltration was present.

It would appear that we had here a mild recurrent appendicitis, occurring in a patient possessing a hereditary tendency toward sarcoma formation. The low-grade inflammatory process eventually resulted in a true sarcoma, which, because of the adhesions already existing, was enabled to extend from the appendix to the wall of the cecum, although the point of origin of the tumor was at some distance from the base of the appendix.

The following cases have been collected from the literature:

(1) Gilford: A woman, aged 27 years, with symptoms of chronic appendicitis for thirteen years. Spindle-cell sarcoma of the appendix, which was adherent to the colon and ileum, neither of which were involved.

(2) Warren: Boy with symptoms of chronic appendicitis, intermittent pain and fever for one month. Tumor at ileocecal angle with involvement of the appendix. Round-cell sarcoma, with glands extending to the root of mesentery. Simple appendectomy. Was well four years later.

(3) Glazebrook: A colored man, aged 55, died of apoplexy. At the autopsy the appendix was found to be enlarged to the size of a pigeon's egg, and surrounded by dense adhesions. Fibrosarcoma of the tip of the appendix, originating in the serosa and invading all coats.

(4) Patterson: Man, aged 39 years; uneasiness and occasional pain in the right iliac fossa for three months; an acute attack with vomiting just before operation; a tender mass palpable. Diagnosis, chronic appendicitis. Operation: appendix found to be thickened and adherent. The wall of the cecum thickened for a quarter of an inch about the appendix. This thickened portion was removed with the appendix. The patient died six hours later. Autopsy showed no trace of tumor elsewhere. Round-cell sarcoma, involving all coats except serosa.

(5) Carvardine: Woman, aged 45, had symptoms of appendicitis for five months; had severe pain in the right iliac fossa; attacks of diarrhea and severe colic, a deep-seated, tender swelling present. Operation showed the appendix three and a half inches long, the size of the thumb, very hard, adherent, and peculiarly friable. Cecum not involved, but the head and a neighboring enlarged gland removed. Recurrence on left side. Death, nine months later. Round-cell sarcoma.

(6) Carvardine: Man; appendix removed for recurrent appendicitis. Central portion contains a concretion. At tip is situated a white-colored tumor the size of a hazel-nut. Some neighboring glands enlarged. Round-cell sarcoma. Author calls it lymphosarcoma.

(7) Bernays (reported by Kelly and Hurdon): Woman, 29 years of age, negative family history. Symptoms of chronic appendicitis for one year. Operation: appendix found free, distal portion normal, proximal portion large and firm, adjacent cecal wall infiltrated for short distance on one side. Complete excision of cecum. Recovery. Round-cell sarcoma, involving all layers of the appendix. Two years after operation the patient showed a tumor in the abdomen, which was considered to be a recurrence. (This case was ruled out by Rolleston and Jones on the ground

that the tumor was not primarily of the appendix. This criticism does not seem well founded by the writer.)

(8) Stewart: Man, 35 years of age. In course of a year had three attacks of what was diagnosed recurrent appendicitis. Each attack more severe. Pain, muscular rigidity, vomiting, pulse 100, temperature 102°. Operation: appendix found in the ilieocecal fossa, buried in what were taken for adhesions. Appendix enucleated with the finger. Simple appendectomy. Spindle-cell sarcoma.

From the few cases available for analysis it would be useless to attempt to build up a clinical picture by which a diagnosis of sarcoma of the appendix could be made. Indeed, as has been pointed out in the histories reported, a diagnosis has never been made before operation. This is hardly surprising since the symptoms in every instance were of appendicitis in one form or another. The extension of the growth to the cecum usually gives rise to symptoms which might lead to a correct diagnosis. Yet in three of the cases such an extension had taken place and in each instance a diagnosis of recurrent appendicitis, with possible circumscribed abscess, was made.

In the one case in which the condition was found at autopsy, the growth was probably in no way associated with the cause of death. The reasons which led to operation in all of the other eight cases were symptoms of more or less chronic appendicitis. In one case there was continuous pain in the right iliac fossa for a month, in another for three months, and in six there were recurrent attacks extending over periods ranging from one to thirteen years.

In some, then, the condition appears to have been relatively acute, while in others the symptoms had extended over many years. Can these extremes be reconciled with the view that the growth is directly

or indirectly the cause of the symptoms? or must it be assumed that the growth is a mere accidental occurrence? In the more acute cases it is easier to admit the possibility of the growth being the actual cause of the inflammatory trouble, for such a growth might predispose the walls of the appendix to infection, or it might block the lumen, or interfere with the nutrition of the tissues by compressing the blood-vessels.

In those cases with long-standing symptoms the obvious objection that the growth, if the primary cause, would long since have given rise to metastases, or would have spread locally and have caused the death of the patient, can be met, in part, by the fact that these tumors are not prone to form metastases. Letulle, Weinberg, and others have laid special stress on the probability that chronic inflammatory change is the precursor of malignancy in the appendix, just as it is well known to be in the female breast and the stomach.

The true explanation of the great divergence in symptoms and course of the disease is probably this, that the growth is at times the cause and at times the effect of the changes producing the symptoms. In those cases of comparatively short duration or in which the growth is the predominant feature, it is probably the direct cause of the symptoms. In those cases of chronic appendicitis in which the growth is discovered only by the aid of the microscope, it is probably the result of the long-continued inflammatory process.

The extent of operation called for in these cases has often exceeded the simple removal of the appendix. Of the eight operated cases here reported, in four the cecum and enlarged mesenteric glands were resected, as well as the appendix. Yet it is to be said that in none of the cases in which simple appendec-

tomy has been done has there been recurrence reported. The only certain case of recurrence after operation is that of Carvardine, and in this the cecum, as well as the appendix, was removed.

The results of operation, both immediate and remote, have been suprisingly good. Of the cases here reported there was one death immediately following operation, and one nine months after caused by recurrence. In the case reported by Warren he mentions that the patient was well and free from recurrence four years after operation. This is striking evidence of the slight malignancy of these growths as compared with the same growth in all other parts of the alimentary canal.

CONCLUSION

1. An accurate diagnosis before operation appears to be impossible. In every case the symptoms were those of some type of appendicitis.

2. Pathologically, the round-cell sarcoma predominates, next to this the spindle-cell type.

3. Inflammatory changes, either chronic or acute, very frequently accompany the growth.

4. The immediate prognosis and prospect of freedom from recurrence are very good.

5. The fact that primary sarcoma of the appendix takes its origin in an inflammatory process, forms a very strong additional argument for the removal of all appendices which show evidences of inflammation.

REFERENCES

Gilford: Lancet, 1893, vol. ii., p. 241.
Warren: Boston Med. and Surg. Journal, Feb. 24, 1898.
Glazebrook: Virginia Med. Monthly, 1895, p. 211.
Patterson: The Practitioner, 1903, p. 55.
Carvardine: Brit. Med. Journal, 1907, ii, p. 1771.
Kelly and Hurdon: The Vermiform Appendix, 1905.
Stewart, G. D.: Annals of Surgery, 1908, p. 607.
Letulle: Bul. et Memoirs de la Soc. Anat. de Paris, 1903, p. 638.
Weinberg, Bul. et Memoirs de la Soc. Anat. de Paris, 1905, Mars Annee 80.
Rolleston and Jones: Am. Jour. Med. Sciences, cxxxi, p. 957.
Harte: Annals of Surgery, xlvii, p. 968.
Vossmer, W.: Deutsche Zeitschrift für Chirurg., 1908, p. 445.

DISCUSSION

Dr. A. E. Hertzler (Kansas City, Mo.): This case resembles the groin-tumor and the bone-sclerosis in its pathogenesis. I would suggest that in speaking of disease of this character it would be worth while if some of the tissue from the case reported could be placed at the disposal of the members for examination. It seems to me it is very essential to have a microscope and slides in discussing a paper of this character, particularly where most points in diagnosis are not settled and are likely to come up and be discussed. I have no hesitation at all in referring to this case as one of chronic inflammation of low grade. These chronic hyperplasias are not confined to the appendix, by any means. A more frequent site of them is the cecum. A large tumorous mass is produced, and, if the process is relatively slow, you get the typical chronic hyperplastic structures, while, if this lesion is more rapid, you get the spheroidal cell with the polynuclear leucocytes. From a purely clinical point of view, if we find sarcoma in that region, which has this typical periodical exacerbation, we would be at once suspicious of a diagnosis of sarcoma. Sarcomas in other regions do not have this characteristic. The fact that sarcoma frequently follows trauma has led us to presuppose that these inflammatory lesions might precede sarcoma, but the type of lesion which is followed by sarcoma is totally different from the suppurative lesions which give rise to these hyperplasias of the intestinal tract. The sarcomas elsewhere, and the true sarcomas in the intestinal tract, are not followed by peripheral adhesions to surrounding structures as on the chronic hyperplasias. In going back to the possible histogenetic relation between sarcoma and inflammatory processes it can be demonstrated with a great degree of suggestiveness that the traumatic predisposing condition in sarcoma is not a true inflammatory condition, not a bacterial lesion at all, but the formation of some ferment which changes the exudative process about the lesion, which is neither suppurative nor fibroplastic. This can be shown in those hemorrhagic uterine myomas which are in process of undergoing sarcomatous degeneration, which is proven by the subsequent course of the disease. The extension of these inflammatory processes about the appendix, along the cecum, is rather usual. We had demonstrated to us last year a typical case of this same type of disease by Dr. Crosson, of St. Louis. You will remember in that instance a tumorous mass was produced in the cecum. What is necessary in this disease is

a more careful histopathological study of the tissue removed. The cases reported in the literature are not accompanied by detailed microscopic study, and are not accompanied by a detailed set of illustrations showing the actual findings which will enable us to clear up this extremely interesting problem. I believe it would add further to such a desirable end if the members who report these cases would bring along all of their slides and sections for examination.

Dr. S. C. Beede (David City, Neb.): I made up my mind when I found out I was to help along the discussion of this paper, to state that primary sarcoma of the appendix is a surgical curiosity. Now, since hearing the opening discussion, I am not so sure that it is even a curiosity. It would seem from the standpoint of practical surgeons that the question of primary sarcoma of the appendix is hardly worth discussing. It is true, there are many conditions that are accepted as common today that at one time were surgical curiosities. Even with regard to inflammation of the appendix itself, most of us can remember the time when a discussion of it would have been considered almost as curious and useless as a discussion of primary sarcoma of that same organ would seem today. But this discussion of appendiceal sarcoma is not a thing that can be of very much practical benefit to us. Ever since Warren reported his case, in 1898, there has been a good deal of investigation and close observation in regard to malignancy of the vermiform appendix. I have read quite a number of reports where sections were made of consecutive cases. In the pathological department of St. Mary's Hospital, Rochester, Minnesota, they have reported on five thousand appendices removed for disease of that organ, and of this number there were twenty-two cases of primary sarcoma of the appendix, but not a single case of sarcoma developed, and so far as utility is concerned we can leave the matter out of consideration. Evidently, however, the subject is of great interest to the pathologist, and I am going to leave it to the pathologists that are present.

I can conceive of one lesson which may be drawn, namely, if we do have primary malignancy in the appendix, and take occasion to immediately make a microscopic examination of the tissue removed, and find it is malignant, we can be a little more radical in the removal of tissue about the appendix than when we think it is simply an inflammatory infiltration.

As to the probability of chronic inflammation being a cause of sarcoma of the appendix: if we concede there is such a

thing, it seems to be so very remote that such a probability is almost impossible. It is true that repeated inflammations, repeated irritation, repeated small traumatisms, will cause cancer—do not understand me to say that it is a primary etiological factor, but it is certainly a clinical fact that it is a causative factor. Dr. Wilson says seventy-one per cent of the cases of cancer of the stomach that have come to examination microscopically at St. Mary's Hospital, Rochester, Minnesota, started from the scar of an old ulcer. We know very well the apparent influence of the pipe-stem in producing cancer of the lip, and so on. It is true, also, that sarcoma follows injury, but the type of injury, as Dr. Hertzler has already mentioned, is altogether different. While repeated small traumatisms will produce carcinoma, sarcoma follows a single severe injury. On account of the position of the appendix, it is peculiarly free from such injuries as would induce sarcoma. I do not think it is worth while to consider the prognosis of these cases, because, in the first place, we must find out whether we have sarcoma of the appendix or not.

Dr. William C. MacCarty (Rochester, Minn.): I thought when I came here I would have a chance to sit and enjoy this meeting instead of talking. As Dr. Beede, in discussing the paper, has just said, I have had the privilege of examining about five thousand appendices which were removed in Rochester by the Drs. Mayo, and since then the list has been extended to about ten thousand. In all of this series I have not seen a case of sarcoma of the appendix. In the five thousand cases to which he has referred there were twenty-two cases of carcinoma of the appendix, and two of these I had previously diagnosed as endothelioma, which in itself shows you that the differential diagnosis between endothelioma and sarcoma is frequently a difficult one. These cases were all very early cases, and in only one out of the seventeen was the serosa involved. I had an opportunity therefore to study something of the early morphology of the condition, and it appeared to me that these cells grew from the epithelial cells of the mucosa, rather than from the cells of musculature. They are arranged in groups, and the cells are round or oval, and therefore may resemble sarcoma.

As to the etiology in hese cases: Ninety per cent occurred in appendices with partially or completely obliterated lumena.

We must now consider the obliteration of the appendix an inflammatory process. Indeed, Ribbert, who was the chief advocate of the involutionary idea of the physiological involu-

tion or obliteration of the appendix, has given that up, and now considers the process inflammatory. We must consider inflammation a close associate of malignancy. Whether or not it is a direct etiological factor, remains to be seen.

In regard to the surgical significance of these malignant changes in the appendix, we may say two things. In the first place, it is practically impossible to diagnose carcinoma of the appendix clinically. In none of these cases was the diagnosis made. Seventeen out of twenty-two cases we found, we might say, accidentally by cutting serial blocks through a large series of cases. Clinically, we must consider carcinoma out of the question so far as the diagnosis of it is concerned.

As to the occurrence of carcinoma: one out of two hundred and twenty-six appendices removed at operation showed carcinoma. I am referring now to appendices that were removed at operation. This fact, I think, is possibly of some clinical significance because many surgeons are prone to say that if the appendix is becoming obliterated, nature is taking care of the inflammatory process. One out of every fifty-six partially or completely obliterated appendices was carcinoma.

Dr. Donald Macrae (Council Bluffs, Iowa): It has been my experience to have had a number of these cases, and while they are exceedingly rare yet I believe I have seen eight or ten of them that I recall to mind just now, in which a diagnosis of sarcoma was made so far as the macroscopic appearances were concerned. Notwithstanding this, however, I want to agree with Dr. Hertzler's remarks absolutely. I believe exactly as he does. I regret very much that I do not know as much about the pathology of this subject as he does, for if I did I could add to what he has said, but I am unable to do so. But I have had a number of these cases that have been diagnosed as appendicitis, but no diagnosis of sarcoma was made prior to the operation. In these cases the appendix has imparted to my fingers the sensation of sarcoma. Unfortunately, in the cases I have had the disease has not been confined to the appendix. The appendix was lost in a mass of this new tissue. In operating on these cases I found the pathologic condition involved the cecum, and in separating the adhesions they would tear away like frozen meat. A sarcomatous feel was imparted to the touch.

As I have said, in my cases the disease had extended beyond the appendix, so that the cecum was more or less involved, and the enlarged portion of the cecum had the same hard tumefaction and feel that a sarcoma would have. I can-

not describe it in any other way than that it had the feel and appearance of a sarcoma. In all my cases it was necessary, I thought, to do a resection of the cecum and a portion of the ileum and transplant the latter to the upper part of the ascending colon, or in several cases to the transverse colon. In all of these cases I had the conviction that I was dealing with sarcoma. Some of the pathologists who examined the tissue removed from some of my cases said it was undoubtedly sarcomatous, and others that the mass was simply a chronic inflammatory condition. However, after what has been said I am inclined to believe that these cases were not sarcoma. I can imagine that primary sarcoma of the appendix is a rarer disease than any pathological condition we have before us for consideration today. At the same time, if there is any class of cases in which the pathologist is confused and in which surgeons are at a disadvantage, it is in sarcoma. I have had this mistake made a number of times by the best pathologists. The interest attached to the condition is this, Is it necessary to resect quite a portion of the gut, which makes the operation more or less formidable? We think we have a simple case of appendicitis to deal with, but on cutting down we find the condition is such that we have to make a resection of the cecum and do an anastomosis, which is disagreeable, for the patient runs the extra risk, whereas we promised the patient, perhaps, that he would run no risk at all. I say, it is disagreeable.

Then comes the prognosis, which to the practical surgeon is very important. I have informed the friends of these patients that if the condition proved to be sarcoma, according to the report of the pathologist, they would in all probability have a recurrence. It is rather disagreeable to tell a patient he is going to die from recurrence and then have him die of old age. From my standpoint as a surgeon, I try to give the friends or relatives of the patient a prognosis. I have not previously reported any of these cases. There are doubtless some members here who have had similar experiences that they would like to report, and I would like to hear from them. While the appendices in my cases may have been sarcomatous, I do not believe they were after what has been said.

Dr. Gustav Schwyzer (Minneapolis, Minn.): After such a free discussion I feel it is very hard to hold your attention. Since we have observed that over one hundred cases of carcinoma well proven of the appendix have been added to the literature, I feel that we have contributed a great deal to the etiology and to the indications for operation, and that today,

knowing more about these malignant appendices, we are in a position to say to the patient, that, if he resists repeated advice for operation after numerous attacks, the disease may be something else—something more serious than only chronic appendicitis.

As to the pathology: I will say just one word in regard to carcinoma of the appendix. Reading the recent literature we find that the pathologists are not at all of the same opinion in regard to carcinoma of the appendix. This is the case regarding one class of carcinoma, namely, the small alveolar type, located at the tip of the appendix, mostly incidentally found. This form lacks its clinical proof. In none of this type does the disease recur. No metastases have been found.

As to sarcoma: We are still more in the dark. If you will pardon me, I will cite a case I saw a few years ago in Berne, Switzerland. A patient presented himself with a large tumor of the diaphysis of the femur. Professor Kocher was operating for the removal of the tumor, believing he had to deal with a sarcoma of the femur. After laying the tumor open, the pathologist, Professor Langhans, a well-known authority, was asked to make some sections, which, of course, had to be frozen in order to get a quick report. Professor Langhans sent in the positive report that the tumor consisted of a round-cell sarcoma. In the meantime Kocher was keenly observing the tumor while waiting for the pathologist's report, and he found some grayish little dots here and there which appeared to him deteriorated tissue, and he determined that this was an infectious granuloma, acted accordingly, leaving the femur, and saved the patient's leg. No recurrence took place.

It is not an easy matter to make a differential diagnosis between infectious granuloma and sarcoma. From Sticker in Berlin we learned that the tissue of round-cell sarcoma brought in direct contact with serum plates causes an indentation, which is not the case with granulomatous tissue. Sticker claims that this is due to the formation of a proteolytic ferment.

Dr. Emerson F. Root (Salt Lake City, Utah): This is a very important subject. Dr. Jones has reported a case of sarcoma of the appendix and has given sufficient data to make us believe that it is primary sarcoma of this organ. But his diagnosis has been doubted, and also the statistics of Dr. MacCarty are diametrically opposed to any condition possibly existing in this region. Dr. MacCarty has referred to ten thousand cases, which ought to be worth something in estab-

lishing the possibility or impossibility of sarcoma of the appendix. But I am going to venture this, at any rate, in support of Dr. Jones' idea: About six or seven years ago I had a case of what I thought was primary sarcoma of the appendix, where there had been chronic appendicitis for more than one year. The patient refused operation, and at this time for a month or two was rapidly running down, and then sought operation. No diagnosis was made other than that of chronic appendicitis. The appendix was found to be very large, five or six inches long, perhaps an inch or more in diameter, and its lumen almost occluded. It was friable, rather hard, and very loosely attached. The cecum was not involved to any great extent. The appendix was removed by removing a small portion of the head of the cecum. The wound healed promptly. The patient died two or three months later. According to the microscopic diagnosis, this was a case of round-cell sarcoma of the appendix.

Dr. William Jepson (Sioux City, Iowa): We have the paper that has been read before us for consideration, as well as the remarks of the gentlemen who have discussed it, and if it is permissible to make remarks on the statements made in the discussion of the paper, I would like to do so. The last gentleman discussing the paper said "he wanted to stir up the lions." I may say to you, I am one of those lions whom he has stirred up by his remark. Personally, I am averse to the continuation of useless terms in our literature. I am averse to coining terms that express nothing. The term *desmoid tumor* was coined prior to a knowledge of the histological structure of these tumors. Hence older surgeons finding fibroid tumors developing from the fibrous tissue of the abdominal wall, classed them as desmoid tumors owing to their having developed from the hard band-like masses found in the rectus muscle and in the transversalis fascia, which was then known as *desmoid tissue.* The term *desmoid* is from the Greek, meaning a hard band, as a tendon or ligament; and as these hard bands of fibrous tissue are found normally in the abdominal wall, at sites mentioned, it was natural that tumors developing from such structure and possessed of their gross characteristics would be called *desmoids.* Is there, however, any reason why we as surgeons should continue employing that term when it expresses nothing, while the term *fibroid* tumor (for that is all they are) expresses quite clearly their structure and incidently their growth-tendency. While I do not object to this term, which has crept into our surgical

literature and has been perpetuated through the writings of certain men, as long as it is used in the sense originally employed, namely, in connection with tumors of the abdominal wall, I do protest against applying the term to inflammatory processes of the appendix.

We do not have *desmoid* tumors of the appendix, and Dr. Hertzler has committed the error, it seems to me, of attempting to classify tumors upon an etiological rather than a histological basis, which in itself may not be so bad, but to use the general etiological factors involved in a trauma or inflammation as a basis, and then infer that because desmoid tumors are apparently occasionally caused by trauma or by inflammation, that all growths are desmoid when such a relationship is shown. If we are going to retain the term at all, let us restrict it to the hard fibromas of the abdominal wall—those that develop from its fibrous tissue, but let us not extend the term; instead, let us discard the term as rapidly as possible.

It has been stated that the tendency of desmoid tumors is to recur. This is contrary to my experience which has, however, been confined to three cases of desmoid tumors, which is, of course, not a sufficiently large number to draw deductions from, but in none of these has recurrence taken place, and the last one was operated on four or five years ago.

Dr. Jones (closing the discussion): My paper has elicited such a lively discussion that there is very little for me to say. I am not sufficiently well versed in pathology to answer the statements of Dr. Hertzler. I am sorry, however, I did not bring the sections along with me. I have plenty of them, and will be pleased to furnish them to any one who is interested. I might say that the growth certainly looked like a sarcoma, and the sections look like sarcoma, and four or five men of more or less local repute in my neighborhood as pathologists have stated that this was a case of sarcoma of the appendix. I think this whole question is one more of an argument over terms than of actual conditions.

As to the remarks of one gentleman who engaged in the discussion: I do not think there can be any doubt that there is such an entity as this particular kind of appendix which I have described. It certainly looks different and feels different from any inflammatory appendix that I have ever seen or felt, and whether it be a sarcoma or not, or whether it be something else, is not of great practical importance except from the standpoint of prognosis.

While in most of the cases reported no recurrence has followed, yet in one there was a recurrence followed by death.

In another case a year or so after operation a suspicious tumor developed in the abdominal cavity which was thought might be a recurrence, but whatever became of it the report, as I found it in the literature, did not say. The report by Dr. Root of another case followed by death within a few months, is of sufficient importance to emphasize the fact that the disease may be malignant, and from my own particular standpoint, if I run across another such case, I shall treat it by resecting the cecum, as well as removing the appendix, and tell the patient that there is a possibility of recurrence.

THE OPERATIVE TECHNIC IN ACUTE SUPPURATIVE APPENDICITIS

WILLARD BARTLETT, M. D.

ST. LOUIS, MISSOURI

Without desiring to touch upon the controversy as to the operability of acute appendicitis at one period or another of its course, I think it safe to assume that all surgeons now do operate upon all patients, if seen early. Some may define "early" in one way, some in another; but for our purpose let it be understood that what follows is intended to apply where the disease is a day or two old and pus exists. Complications are not frequent at this period, and for the sake of simplicity I desire to ignore them altogether; however, they may be so numerous and varied in character when later they do exist that no routine procedure will cover them all, and therefore I make no attempt here to deal with them, but simply have in mind an operative method which accomplishes all that is desired or needed in my early cases.

We have elaborate routine procedures of undoubted excellence for many of the operations of choice, as, for example, in inguinal hernia, where we can take our time and, as far as the patient's condition is concerned, do about as we please in every particular. It seems, then, that an emergency, such as acute appendicitis frequently presupposes, renders it all the more important that the operator have some method in mind which makes it possible to do all that is necessary for these patients in the shortest space of time with the least amount of damage. However, opinions

differ to the extent that all sorts of incisions are used. Removal of the appendix is accomplished as a routine by many, while others positively advocate against it.

The treatment of the stump varies greatly in the hands of those who *do* remove this small viscus. Some sew up the wound in the presence of pus, while others drain with every conceivable agent, from rigid tube to soft material of many sorts. Some operators flush the abdomen in every instance, others mop, wet or dry, while many let the pus take care of itself. As to walling off the general cavity during the operation, there is the same diversity of opinion; in consequence, some excellent surgeons carry out a technic which cannot be utilized within what seems to others the time-limit allowable for patients in the dangerous condition often obtaining in this disease. Certain incisions and methods of closure necessitate a long stay in bed, a matter by no means without importance, especially in hot weather and in view of the prevalence of hernia through abdominal wounds which have been infected. In view of these considerations it seems to me of value to recite a simple routine procedure at which I arrived after years of simplification.

1. The abdomen is invariably opened through a gridiron incision immediately over the dull area, if one can be made out, otherwise at McBurney's point. It is very rarely the case that this incision has to be enlarged, which can be done, though with slightly greater difficulty than is the case in ordinary through-and-through openings. My experience has taught me that it is just as applicable to pus work as to any other.

2. Immediate search for the appendix is made, it being my practice always to remove it if it can be found without unnecessary loss of time or disturbance of many adhesions in the presence of a large

amount of pus. I do not often go so far as to turn out the head of the cecum in order to find the appendix, but I consider this advisable where this carries with it the adherent viscera which completely surround a collection of pus, to be opened outside of the abdomen at the removal of the appendix. It is rarely my custom to do much or any so-called walling off with gauze in the search for the appendix. We long ago learned that intra-abdominal tension forces liberated pus toward the opening in the wall rather than in any other direction; on the other hand, undoubted harm is done by gauze packs; at the same time ready access to the viscera is interfered with. While in clean work I make a peritoneal autoplasty when working on the appendix or any other viscus covered by peritoneum, in these pus cases I simply tie a strand of catgut around the base of it, including the mesenteriolum, and cut it off. Not only does this save time, but the appendix and adjacent cecum are often so indurated and friable that ordinary Lembert stitches will not hold. By way of justifying a search for the appendix in the acute stage, it is hardly necessary to state that a variety of dangerous complications are avoided by its removal. In a very small percentage of these cases a fecal fistula has made its appearance, but not one has failed to close spontaneously in a few days.

3. Drainage is instituted in every case where exudate is met with. This is most readily and accurately accomplished to my thinking by tying at *its middle* a strip of rubber dam or a ribbon cut from an old rubber glove in the catgut ligature on the base of the appendix mentioned above. This treatment suffices for ordinary cases, although of course I am not here dealing with remote pus collections which are infrequent early in the disease and which must be considered as complications not to be dealt with in any

simple routine procedure. Drainage is further aided by placing the patient in bed on the face directly after the operation. In a few days the catgut ligature is absorbed, and the drain comes out of its own accord.

4. Suture of the deeper layers of the abdominal wall is never attempted unless the muscle-splitting incision has been considerably enlarged. The drain practically fills the small dead space resulting from the spontaneous closure of such incisions, thus re-establishing intra-abdominal pressure sufficiently for our purpose. In the middle of the skin-wound are placed one or two clips at each side of which one-half of the rubber drain emerges, its two ends being fastened together by a clip which prevents the possibility of its being drawn into the abdomen. Thus one has practically coäpted the edges of an infected wound without any danger of pus retention in the depths or under the skin. After the two drains have been removed at the end of a week the resulting defects in the skin are closed with adhesive plaster, and in two weeks after the operation most of these patients are out of bed with a solid abdominal wall and with the skin-wound completely healed or almost so.

In easy cases this simple procedure of opening the abdomen, ligating the appendix with its mesenteriolum, and attaching the rubber, can be accomplished in a very short time (it has been done repeatedly in five or six minutes); however, difficulty in locating the appendix must correspondingly prolong the operation.

DISCUSSION

Dr. Walter Courtney (Brainerd, Minn.): I feel somewhat embarrassed in attempting to discuss this subject, on account of the brevity with which Dr. Bartlett has dealt with it; also from the fact that he has talked to an entirely different title from that given in the program, so that I have

some feeling of trepidation as to what I should say in discussion.

The question of dealing with the appendiceal stump is one about which every surgeon has his individual opinion, and, usually, one man gets as good results as another.

The question of drainage is a varied one, about which individual surgeons have individual opinions.

I scarcely know what more to attempt in talking to the subject, except to say that I have, in a number of instances, followed the plan of Dr. Van Buren Knott with much satisfaction.

I could scarcely hear Dr. Bartlett from where I sat, so that I am not prepared to further discuss the subject, as he handled it. What I was able to hear seemed logical, and perhaps his method is as good as the rest and may be somewhat better.

Dr. Van Buren Knott (Sioux City, Iowa): Like Dr. Courtney, I was surprised, as I had supposed Dr. Bartlett was going to speak on the treatment of the stump of the appendix rather than on the operative technic in acute suppurative appendicitis, and inasmuch as he mentioned a former paper of mine on this particular subject, I shall give my additional experience. At the time the paper was read, some two years ago, you remember that it was advocated that the appendix be removed in every case as soon as the diagnosis of appendicitis was made, no exception being made. In other words, that in every case of localized abscess due to appendicitis the appendix should be removed. The thing that brought that about was the observation that in our cases of diffuse spreading peritonitis the recoveries were quicker than in those cases in which there was localized abscess, in which the abscess was simply opened and drainage instituted; that is, the appendix being removed in every case of spreading peritonitis, and left in the case of localized abscess. As soon as we began to liberate all adhesions we discovered here and there many adherent coils of intestine with localized pus-collections, which were not suspected at the time of the primary operation. These pus-collections occurred in those cases in which drainage alone was instituted, and were reported as secondary pus-collections, and the patients required secondary operations. In most instances these abscesses existed at the time of the original operation, and with a free separation of the adhesions and the establishment of drainage at the bottom of the pelvis no secondary operation would have been required.

Relative to the technic described by Dr. Bartlett in cases of this kind: I have not used it, and possibly for that reason I am not qualified to discuss it.

In our own work we have separated the adhesions, opening into the cul-de-sac or rectovesical pouch and draining from that point only, establishing no drainage in the region of the appendix stump. We still use a rubber tube, and I do not believe there is any danger of intestinal necrosis from the rubber tube if, in introducing the tube, you are careful that it does not impinge upon any of the coils of the intestine. If you should happen to pinch a coil of intestine between the tube and the bottom of the pelvis, unless it slips away, you will have obstruction due to pressure, or necrosis, with resulting fistula, which are serious complications. If the tube is carefully introduced, the chances of this occurring are remote, because the gauze makes a fixed point in the lower pelvis. Since adopting this plan of treatment we have had three hundred cases with only two deaths. The mortality following this plan of treatment in my hands has been much lower than from simple incision and drainage, and I have no hesitancy in recommending it to the profession. In recommending it, however, it is a plan of treatment which should be carried out only by men experienced in abdominal work, who can get in and do the operation and get out without the loss of unnecessary time and manipulation. We are not nearly so much afraid of spilling pus into the peritoneal cavity as we used to be. Practically all of these cases of acute diffuse septic peritonitis, if operated on early and drained sufficiently early, recover. It does away with the bugaboo about being so very particular in the case of localized appendicular abscess, or any other abscess, of merely opening and draining it without removing the exciting cause, leaving these patients to have secondary complications which will ensue in some thirty per cent of the cases unless the appendix is removed.

Dr. Major G. Seelig (St. Louis. Mo.): To revert to the title of the paper, as given on the program, the treatment of the stump of the appendix, I will say there is more or less diversity of opinion as to whether it is better to proceed along very simple lines, simply ligating the appendix, ablating it distal to the ligature, and sterilizing the stump, or whether to execute the more complex procedure of invagination or inversion of the stump.

I wish to utilize this opportunity to put on record a very simple experiment that I did only a week or so ago

that bears out further by way of favorable testimony the strength and safety of the simple method of ligation. I think we have failed to consider—I know I did—the physical mechanics of this particular region of the intestinal tract. We have failed to consider the thickness of the appendicular wall in comparison with the thickness of the well of the cecum and colon. One of the things that has been mostly feared following the use of the simple ligature without invagination has been that, as the cecum distends post-operative, we are apt to get a blow-out due to the strain of the gases on the ligature on the stump.

I had occasion a few years ago to have a rubber tube made of definite thickness down to about one-half inch from the tip, this distal one-half inch being made thinner-walled. When air was forced into this tube under pressure, the thicker portion of the walls would remain as rigid as steel, and the tip only would distend under the air-pressure. You have doubtless noticed the same thing in automobile tires. The tire when inflated assumes a normal contour except at the point where it is thin, at which point it balloons out and finally bursts. The appendix is the thickest wall of any tube in the abdomen. It is much thicker than the wall of the cecum, colon, or ileum, and based on this fact we are warranted in assuming that although the cecum might distend after operation, the appendix stump will not share in that distention, and consequently the ligature will bear no strain. In order to substantiate this, about a week ago I removed from a fresh cadaver immediately after death the cecum, appendix, and ileum. I tied off the appendix, removed it distally to the ligature, sewed up the end of the colon, and then connected the ileum with a force-pump and forced air in under pressure. Just as I had expected, the appendix did not participate in the distention of the ileum and colon to the slightest degree, even up to the point where the pressure was great enough to blow out the thin wall of the cecum. There was no time when the enclosed air-pressure put any strain on the ligature applied around the appendix. It would seem, then, on clinical grounds, and rationally on mechanical grounds, that we need not fear the treatment of the stump of the appendix with simple ligature. In other words, we need not fear it on the basis that the ligature is subjected to any strain by the accumulation of gas that occurs as a post-operative sequel.

SURGERY OF THE MEDIASTINUM OTHER THAN INJURY AND DISEASE OF THE CARDIOVASCULAR SYSTEM

BENJ. MERRILL RICKETTS, PH. B., M. D., LL. D.

CINCINNATI, OHIO

Mediastinal, next to cardio-aortic, surgery is the most recent of any applied to the thorax and its viscera. This has been due to pneumothorax resulting from exposing the space, directly or indirectly, to atmospheric pressure, but now that ways and means have been devised to overcome this condition any one or all of the four divisions of this space may be exposed at the same time with comparative safety.

The cavity being formed by the soft structures of the neck above, the diaphragm below, the sternum in front, vertebræ behind, and visceral pleuræ and pericardium laterally, together with the cardio-aortic system, esophagus, pneumogastric nerves, superior vena cava, thoracic duct, thymus and bronchial glands contained within it, renders it a most frequent locality for disease and injury.

The relations of the spaces, with the absence of injury or disease, are not constant, because they are many times embryologically defective. With all forms of neoplasms the relations are more or less varied, while the pressure of fluids, such as pus, serum, blood, and chyle, only temporarily changes the relations. This is demonstrated by their return to normal after the withdrawal of fluid.

Neoplasms, however, possess adhesions which may

cause the space to become temporarily or permanently obliterated. They may form within or enter from without the space and remain there or disappear into other cavities or tissues, or they may make their appearance externally.

Hare's (1888) prize essay must be the basis for future reckoning with injury and disease of this locality. That which is appended represents the observations upon these conditions since then. There is no disposition to detract from the value or sentiment of his work, except possibly to speak more encouragingly upon the surgical aspect, now that ways and means have been devised that were not known at that time. With this in view, the subject in its generality will remain at rest for the present, the ultimate object being to make the two résumés as complete as possible up to the date of its publication, which will appear within a few months. The most conspicuous features of this subject are found in diagnostic and surgical measures. The first immeasurably due to radiography and the second to intrabrachial insufflation.

About fifty per cent of all injuries and pathologic conditions of the mediastinum were found by Hare to be within its anterior portion. This was especially true with one hundred and thirty-four carcinomas, ninety-eight sarcomas, one hundred and fifteen abcesses, eleven dermoid cysts, six hematoma, seven fibromas, eight hydatids, twenty-one lymphomas and lymphadenomas and sixteen mediastinites, (non-suppurative); total, four hundred and sixteen.

The posterior portion comes next in order, while the middle and superior portions were very much less frequently attacked but about equal in number. Those conditions of less frequency according to *Hare* are as follows:

Miscellaneous	104
Stated	48
Not stated	56

Twelve foreign bodies, ten gun-shot, eight tubercular, three lipomas, three enchondromas, two fractures, two enlarged glands, one teratoma, one endothelioma, one emphysema, one gumma, one enlarged thymus gland, one edema, one abcess of thymus gland, and one diaphragmatic hernia.

History: Probably the first to write upon mediastinal diseases was *Van Swiejen,* during the early part of the seventeenth century. Since then, until 1888, when *H. A. Hare* presented his Fothergillian essay in which he tabulated five hundred and twenty cases of mediastinal affections surgery of this locality has received but slight recognition. From prodigious compilations much of our information is derived and our deep appreciation is herein tendered.

Hippocrates and *Galen* were familiar with disease and injuries of this locality, but it was not until *Velpeau,* 1754, that anything surgical is mentioned. He removed a portion of the sternum for caries. It continued to be a forbidden field for the surgeon for many years until *Hayfelder,* 1862, collected twenty-five resections of the sternum. Twenty-two were for caries, two compound fractures, and one for exostosis. Of this number only two died.

Velpeau was the most frequent contributor to this series. The most remarkable work was done by *Kaleczek,* who resected a portion of the third, fourth, fifth and sixth ribs for enchondroma. She made an uninterrupted recovery.

Injuries to, and foreign bodies within, this space, were no doubt first to receive attention from the surgeon, because they were of an emergency character. The conclusions drawn from Hare's work correspond with those of more recent date. Since 1888 about five

hundred papers have been written upon injuries and diseases of this locality, with the exception of forty-two on diagnosis, seven on anatomy, forty-one on pathology and one hundred and forty-four on tumors, making a total of two hundred and thirty-four. The character of the lesion in more than one hundred was some form of sarcoma, forty dermoids, thirty-six abcesses, eleven carcinomas, thirteen tubercular, thymus gland four, hemorrhage four, emphysema three, endothelioma three, embryoma two, actinomycosis one, gangrene one, lipoma one, and foreign body one. There have been forty-two papers written during the last twenty years upon the surgical aspects of these lesions, more than was written before 1888. Twenty-one of this number state the character of the lesion for which the operation was done, while the remaining ones are classed as miscellaneous.

Of the number operated upon, ten were for abscesses, six dermoids, three wounds, one lipoma, one foreign body. The methods resorted to, to accomplish this, were: costosternal osteal flaps, ten; trephine, two; injections, one; lateroposterior incision, one, and not stated, six. While these tables are necessarily more or less imperfect they indicate facts that cannot be obtained in any other way. The deductions drawn from them are in a measure conclusive, at least sufficiently so, to form a basis on which surgical principles may rest.

The first conclusion is, that the following conditions are amenable to surgery, while those not included are more or less, or not at all, influenced by the *x*-ray-, sero-, or chemico-therapy.

The following conditions are operable: abscess, dermoid, lipoma, foreign bodies, hemorrhage, enchondroma, serum hydatids, gangrene, fibroma, tuberculosis, emphysema, and diaphragmatic hernia. *Injuries,* fractures, depressions, exploration, caries, puncture.

Probably eighty per cent of diagnosis of intrathoracic diseases are in error. It is therefore assumed that but twenty per cent are correct. At any rate it is apparent that the increased uncertainty in diagnosis of intra-thoracic diseases is especially found in determining the character of neoplasms during the first stages of their development. This uncertainty will be greatly overcome by the use of the *x*-ray and exploration which is now made possible by intra-tracheal insufflation, which must be accepted as the safest, most efficient and practical means of exposing intrathoracic viscera for diagnosis and the application of surgical principles. The apparatus is simple, light in weight, portable and can be easily constructed by one of but slight mechanical ingenuity. Matas and Sourbruck's methods were the first steps with mechanical means to overcome pneumothorax, and while not practical they may give impetus to discovery of something more practical. There has been but little accomplished with this box that was not done before its discovery.

Surgery of the mediastinum has been principally confined to animal experimentation. It will not become generally applied to man, until a more perfect technic has been developed, though it is now apparently safe. However, it must be remembered that the sixty or seventy recorded sternal and mediastinal injuries and diseases operated upon, have been done without any device to overcome pneumothorax. With but three or four exceptions they were confined to the anterior portion. It is thus proven that surgical invasion of this cavity is not as dangerous as it has been accredited with having been.

Of the four divisions the middle and posterior are the most difficult to approach with safety, while the superior is second to the anterior portion in safety.

Technic for opening the mediastinum of the dog.—

With the Meltzer and Auer apparatus modified by Quinby, pneumothorax may be overcome so that any of the organs or intrathoracic viscera may be attacked surgically for any reasonable purpose or time.

The method of intratracheal insufflation surpasses in simplicity and effectiveness any yet devised. Ether spray mixed with air is introduced into the lung by means of a tracheotomy with a foot-bellows, maintaining a pressure of from eight to ten mm. of mercury.

A case of a dog reported having survived ether anesthesia for twelve hours by this method is sufficient evidence to justify its continued use.

For experimental purposes, thirty or forty grains of chloretone injected into the peritoneal cavity, or thirty minims of a saturated solution of curare given subcutaneously may be substituted for ether to deaden sensibility.

Chloretone is one of the most desirable general anesthetics for experimental purposes where the life of the animal is not to be preserved. The anesthetic dose so nearly approaches the fatal dose that it can not be used with safety. Thirty, forty or fifty grains dissolved in four drachms of warm olive oil injected into the peritoneal cavity will cause sufficient anesthesia to perform any surgical demonstration upon the thoracic viscera. Occasionally a few inhalations of ether will be necessary to complete the work, especially if prolonged beyond thirty or forty minutes should the animal survive the dose.

Curare is a very unstable product. Its value cannot be too highly lauded in experimental surgery of the chest, and its effects can be determined only by actual experiment with each preparation.

A NEW PRINCIPLE IN THE ACTION OF ANTISEPTICS

M. G. Seelig, M. D., and C. W. Gould, M. D.

(From the Pathological Laboratory of the St. Louis City Hospital)

ST. LOUIS, MISSOURI

It is interesting to note that, in the evolution of medical science, certain facts become established as so-called principles. Such establishment rests on the basis of incontestable clinical evidence, or on the basis of experimental induction that has been confirmed beyond all reasonable doubt. A very natural and healthy skepticism often delays the adoption of a principle until an overwhelming amount of proof has accumulated. This seems to be the case as regards the use in surgery of many of the so-called germicides. Despite the numerous contributions to literature concerning the inefficiency of such a drug, for example, as bichloride of mercury, it still remains a formal adjunct to most operating-rooms.

The aim of this paper is not so much to demonstrate the inefficiency of certain supposedly germical solutions, as it is to determine the underlying factor that makes a solution an effectual germicide. Up to the present time the various experimental methods used for testing out the strength of germicides have been faulty in the extreme, in so far as they have failed to reproduce the actual conditions which confront surgeons. Post and Nicholl (Jour. A. M. A., November 5, 1910, p. 1635) have stated these methods of testing germicidal power as follows:

1. Garnet method: emulsions of bacteria dried on

threads, which are suspended in the germicides to be tested.

2. Garnet method: emulsions of bacteria dried on garnets, which are immersed in the germicidal solutions.

3. Drop method: a known small quantity of broth culture of a definite species of bacteria, is added to a constant volume of germicidal solution.

After showing that all these test-methods are faulty, Post and Nicholl state their own method of plating out from a known quantity of germicidal solution to which a definite measure of an emulsion of bacteria had been added. Unfortunately, in the human organism bacteria do not occur in a state of acrobatic suspension on strings; they are not often, even in our better class of patients, found adherent to garnets, and rarely are they found under such conditions as to enable us to so effectually bathe them in a solution, as does the method of Post and Nicholl, or the drop method.

A point of absolutely vital importance in any consideration dealing with the artificial destruction of bacteria is the fact that these organisms are not always found free on the body or on wound surfaces, but occur also in the deeper layers of the skin and tissues, or covered over by blood or exudate. Furthermore the bacteria themselves have a more or less resistant exterior that serves as a protective armor for their vital protoplasm. It is clear therefore that a germicidal solution can be thoroughly effectual in the surgical sense—in the practical sense—only if it possess the power of penetration. Our problem is identically the same as the one which confronts our ordnance experts. The efficiency of a projectile depends almost entirely on the driving force back of it; whatever other excellent qualifications it may possess, it is useless as a destructive agency unless it possesses the

power of plowing through armor protection. And just so with a germicide. The results consequent upon catching a bacterium, fixing him on a string, and drowning him in an ocean of antiseptic, are in no sense of the word a measure of surgical efficiency. Our germicide must possess, in addition to the inherent power of killing, the property of reaching the bacteria by penetrating the tissues in which they lie.

This power to penetrate is none other than the physical and physiological process known as osmosis, and the task we set for ourselves was the determination of the relationship existing between osmotic power and germicidal efficiency. The work had its genesis in a clinical observation. For a year one of us was plagued by a distressing furunculosis. All the known varieties of wet packs were used with the result that after a painful siege each furuncle eventually came to incision. Finally, a pack of 95 per cent alcohol was tried, with the result that in every case, when used early enough, the furuncle was aborted. Further extended experience with punctured wounds and abrasions gave the same results. (The pack was saturated with alcohol, and resaturated as soon as it dried; under no circumstances was or should a rubber protective covering be used.) The alcohol certainly did what other much-vaunted germicides failed to do. The most rational explanation of the result attained was that the alcohol reached and destroyed the focus by penetrating into the deeper layers of the skin.

In our experimental work we studied the comparative germicidal solutions from the point of view of their osmotic power through animal and celloidin membranes. As animal membranes, we used mesentery, omentum, diaphragm, and skin; some of these membranes were used while still alive, others after removal from the body of the animal. We used celloidin membrane because it offered a particularly con-

venient and excellently controllable method. These celloidin test-tube capsules, made by a modification of the method of Harris, (N. M. Harris: Johns Hopkins Bulletin, May, 1902, p. 112) clearly illustrate our technic with celloidin membranes. The capsules were filled with broth cultures of various bacteria,* and then immersed in various watery solutions of antiseptics, such as carbolic acid, bichloride, chrysillic acid, and lysol. At intervals varying from 10 minutes to 24 hours, a loop full of the various cultures was removed and plated. With the exception of one watery antiseptic, the germs were unaffected, even after as long a period as 24 hours. This one exception was iodine. When iodine was dissolved to a strength of 12.5 per cent in water and potassium iodide, it sterilized the germ-content of the capsule in twenty-five minutes; furthermore, by the starch reaction, we could determine that the iodine had penetrated through the celloidin into the broth culture. After three quarters of an hour it penetrated in sufficient quantity to color the broth a walnut-brown.

The next series of experiments dealt with alcohol. We used alcohol (grain alcohol) of varying strengths, from 99 per cent to 50 per cent. The results were little short of astonishing. The higher strengths alcohol penetrated the capsule with striking rapidity. Above 94 per cent the contents of the capsules were sterilized in from three to ten minutes. Eighty per cent alcohol worked much slower, 70 per cent took 7½ hours to kill the bacteria, and 50 per cent had no apparent effect after 24 hours. These results are in accord with our personal clinical experience and also in accord with some lately published clinical reports from the medical department of the Prussian army.

*We found it very practical to use typhoid bacilli in all instances, because the time of cessation of motility and that of general sluggishness were very suggestive phenomena which we could determine and study during the course of the experiment, without waiting for the results of plating.

They stand out in marked contrast to the formerly credited doctrine that 50 per cent to 70 per cent alcohol was the most efficient antiseptic, a doctrine whose incorrectness depends entirely upon faulty deduction from laboratory data. Although we varied the details of this set of experiments in a half a dozen different ways, we always secured the same result, namely, that the germicidal power of alcohol varied directly as its percentage strength. It is interesting to note, however, that the higher we ascended in the scale of concentration of alcohol, the less marked was the bactericidal power. In other words, 95 per cent alcohol was much more effectual than 80 per cent alcohol, whereas 99 per cent was not perceptibly more efficient than 95 per cent.

Having ascertained thus the behavior of watery solution and of varying alcohol strengths on bacteria enclosed in a celloidin chamber, our next series of experiments were directed toward ascertaining whether the action of alcohol was intensified by dissolving germicidal drugs in it, such drugs, for instance, as bichloride, carbolic, Harrington's solution, and iodine. Here again we encountered some unexpected results. In the first place we found that with one exception, namely, iodine, the unadulterated alcohol acted as rapidly and efficiently as did the alcoholic solution of germicides. Further than this we found that if, in making up the solution, the alcohol was diluted, its action was not only not heightened, but actually lessened. Harrington's solution, for example, represents a 60 per cent dilution of alcohol, and it took the same time to kill the organisms despite its percentage of hydrochloric acid and bichloride of mercury, as did plain 60 per cent alcohol. The alcoholic solution of iodine sterilized the organisms more rapidly than did the highest strengths of plain alcohol. This is a fact of striking interest, for two reasons: (1) It confirms

recent clinical experience regarding the efficiency of tincture of iodine, and (2) it possibly signifies that by combining two substances with high osmotic power, we secure a solution of higher osmotic power than that possessed by either substance alone. We found that by raising or lowering the percentage of alcohol or by raising or lowering the percentage of iodine in the solution, we could proportionally heighten or diminish the germicidal power. After from three to five minutes a loop full of the broth removed from the celloidin capsule invariably gave the starch reaction for free iodine. When strong plain alcohol was used we could always determine that it had penetrated the capsule and entered the broth by the rapidity with which a loopful of broth would evaporate. when transferred to a clean glass slide.

Here, then, were a set of experiments, suggestive to say the least, in that they upset a few well-founded ideas fairly effectually, and also in that they suggested the conclusion that osmotic power is a force of prime importance in determining the efficacy of antiseptics. To have forthwith adopted this conclusion, however, and to have grafted our results bodily onto clinical data, would have been only another example of laboratory autocracy. In the ontogeny, and, for that matter, in the whole phylogeny of all varieties of animal life, a celloidin membrane is as foreign a material as is a dried thread of bacteria.

Our next line of attack therefore was on animal membranes. The method of procedure was very simple. A small salt cellar was filled with the germicidal solution to be tested, and then a flap of skin (still alive and attached to the animal) was laid over the salt cellar in such fashion as to pouch into the fluid. The same procedure was carried out with live mesentery and live omentum. Into the pouch which was bathed on one side by the fluid to be tested, was put

a measured quantity of broth-culture of bacteria. Thus we had, so to speak, a living osmometer. The diaphragm of a rabbit makes an excellent animal membrane, but, of course, we could not use the diaphragm while still in connection with the living animal. This animal experimentation, with but few exceptions, tallied with the results previously secured with celloidin. Alcohol penetrated and was effectual as a germicide in direct proportion to its percentage strength. We succeeded in determining that it penetrated even the hide-like skin of the rabbit. Tincture of iodine penetrated and killed even more rapidly than did strong alcohol. Indeed, in the experiments with the delicate thin mesentery, the penetration of the iodine was so rapid that the broth was colored brown before we had time to reach for a platinum loop with which to extract a drop of it. Watery solution of bichloride in the strength of 1-5,000 was totally ineffectual with all membranes, although a 1-1,000 solution penetrated mesentery and destroyed the germ-contents in 45 minutes. We encountered just one marked discrepancy: Five per cent carbolic acid in water effectually penetrated in three minutes a membrane made of diaphragm, whereas it will be remembered that this same strength of carbolic acid totally failed to influence organisms enclosed in a celloidin capsule. The penetration of animal membrane by watery solution of carbolic acid ought really to have been expected on pure *a priori* grounds, knowing, as we do, how readily carbolic acid may be recovered in the urine after extensive skin applications of this drug.

As you know, authorities are gradually veering to the point of view that the field of operation is best prepared by the simple application of tincture of iodine, or by bathing it in alcohol, without preliminary washing with soap and water. The reasons commonly assigned for this simplified method are, that washing

the skin with water swells the epidermis, thus imprisoning the bacteria; or that the water softens the epidermis so that it desquamates and easily brushes off during operative manipulations, or that the excess of water dilutes the alcohol used subsequently. The fact that water used immediately before the alcohol is prejudicial to thorough sterilization, we confirmed by our experiments; but we proved, we think, that the reasons assigned therefor are faulty. It is a fairly well established principle in osmosis that the process goes on best when the fluid on one side of the membrane is thoroughly soluble in the membrane. Now, alcohol is soluble in the fatty constituents of the cell, and the more of this fat that there is present the more complete is the osmotic phenomenon. This observation was made and lost sight of as early as 1855, by Lhermite (Ann. de Chim. et de Physique, 1855, 3me Ser. XLIII, p. 420). We repeated Lhermite's experiments and found that by rubbing a rabbit's skin with castor oil we could hasten markedly the passage of alcohol through it. Preliminary washing of the skin is to be discredited, then, solely for the reason that it removes the natural oily constituents and not because of any swelling or softening effect on the epidermis.

We might detail innumerable clinical deductions, concerning such facts as the effect of alcohol on clean wounds, its vagaries of action depending on whether it is imprisoned under an impervious cover or allowed to evaporate freely, its use regionally, its fixing and hardening properties, etc.; but that would go beyond our purpose of attempting merely to establish the surgical principle of osmosis as a factor in the action of antiseptics. There are only a few words of caution necessary before closing. We realize fully that in dealing with the problem of osmosis, we have in hand a set of phenomena, the fundamental basis of which

has eluded all attempts at explanation by our best physicists and physiologists. We know that every variety of human tissue will react differently as an osmotic membrane, and that it is beyond our humble power to set to rights the complex and seemingly contradictory phenomena. We do not feel that this is either the time or place to go into these questions; but we certainly do feel the necessity of correlating so vital a phenomenon as osmosis with both surgical science and art.

DISCUSSION

Dr. Arnold Schwyzer (St. Paul, Minn.): I did not know any more about this subject than that the penetrating power of alcohol and tincture of iodine was to be the main part in the paper, and the subject, as our president has said, is a rather difficult one to deal with. The essayist has mentioned that in these two germicides, alcohol and the alcoholic solution of iodine, we have mainly the benefit of the osmotic pressure or power of these substances. I differ with the doctor just a little, but still I feel as though I should do it. We all know that osmosis in the body comes into play if watery solutions of one kind are separated by animal membranes from others. Osmosis is only to be spoken of, if we have watery solutions of salts, acids, or bases. Alcohol does not belong to any of those, nor does tincture of iodine, or the iodine itself. It is neither a salt, nor an acid, nor a base. We have in osmosis here a limiting membrane. On the one side we have a certain given concentration of salts and other substances that do not come into play; on the other side we have other salts, in other concentrations. There is a play now going on between these two solutions.

Certain solutions, for instance iron chloride and ferrocyanide of potassium, or a solution of glue and tannic acid, when they come in contact under solution make a membrane. They are membranogenous, and we have between them the membrane of precipitation. The chemical substances are inorganic or organic. The membrane then acts the same as the animal membrane. It separates the two membranogenes which are not permeable by either of these particular substances.

Von t' Hoff, who first created our scientific knowledge

of osmosis, showed that the dissolved substances in the solvent, the water, follow exactly the same laws as gases in a given volume. If the solutions of salts are divided by a membrane, and if that membrane is such that some of the salts can go through and water can go through, but certain salts are retained on the one side of the membrane, we have an application of the osmotic pressure. If, however, there is a simple spreading of certain substances in the whole volume of water, we speak of something else, and that is *diffusion.* When it comes to alcohol or iodine we have the principle of diffusion, not of osmosis. We have no true osmotic pressure in alcohol except on the other side of the membrane from the dehydration. Alcohol and the alcoholic solution of iodine have a great penetrating power, as has been so instructively illustrated by the author of the paper. He says that this particular quality has not been emphasized enough. However, it has been spoken of quite frequently. It has been shown, though probably not by such elaborate experiments as those of Dr. Seelig, that alcohol has that penetrating effect, and also the tincture of iodine. I think we should almost do an injustice to the clinical men if we were to accept the statement that these agents have not been known to owe their value to that power of penetration. The practical results have been well known.

If we speak of the germicidal action, we are to differentiate between simple disinfection of the skin, disinfection of a fresh wound, and disinfection of a granulating older wound. In most wounds we know that in general germicidal substances should be the least toxic possible. Let us take a germicide that is applied to the skin. We know that substances that are immediately decomposed as soon as they come in contact with an organic substance, like watery solutions of chlorine, are not to be used. They lose their value as soon as they come in contact with any organic substance. But the metallic salts, and especially the salt the essayist has mentioned, bichloride of mercury, have been retained in practice. The essayist thinks that surgeons have had too much reverence or respect for bichloride of mercury in retaining it so long. We know that these metallic salts, especially bichloride of mercury, precipitate to a great extent when they come in contact with the body surface or with a wound surface; that is, we get there an albuminate of mercury. The albuminate of mercury will, however, be a certain barrier against the invasion of the germs from the outside, especially in an open wound.

When it comes to the disinfection of freshly infected wounds experiments have been made in that regard also, for instance, by Tavel. He showed that a fresh wound, when infected with a certain quantity of bacteria, may heal, while the same number of bacteria in the wound, if the wound is disinfected with iodine, will suppurate, so that practical and clinical experience must be sufficiently considered in this connection. Where we have a freshly infected wound, and we have a germ which we know the organism will not resist, then we want to have deep penetration of the agents that we use. The clinical man then uses a hot iron or a similar destructive agent. It seems to me, when we look at the experiments that were made with infected wounds, the trend today is to break more and more away from much chemical disinfection. Friedrich, who was over here this year, has made extensive experiments with infected wounds. He found the main thing to be decompression, that is, the relief from pus or exudate under pressure. In an open wound we have a current of serum coming from the surface, which seems to be sufficient. If we use an iodine solution on a granulating wound, it looks as though we were directing our murderous artillery fire against our own line of battle into which a few of the advanced posts of the enemy have entered. We attempt to destroy them, leaving out of the question the innumerable, uncountable hordes of the enemy that are behind this line of battle. The organism must be able to take care of those few that have entered. A better thing would seem to be to throw up a barrier by bichloride of mercury, forming that precipitate of albuminate of mercury, which, though only slightly germicidal, has an inhibiting action upon the growth of bacteria. That would be a new barrier against the invasion of the bacteria.

We are mostly clinical men here, and for that reason I will refer to one change in the use of iodine for skin disinfection. It struck me as quite important. We know that used on the surface of the body for disinfection it has a great penetrating but also irritating power. If you read the proceedings of the last German Surgical Congress you will find that one man, speaking about laminectomies, said he had lost only one case from septic meningitis. The patient died because he had resorted to iodine disinfection of the skin, which caused a severe dermatitis followed by infection of the wound. In the course of the discussion, another man got up and said it was very singular, that he also had lost one

of his cases, and the only one, by the same cause, i. e., sepsis following an iodine dermatitis. We have an important factor in the penetrating power of iodine, but while the essayist's experiments demonstrate to us this fact more definitely *ad oculos,* we must insist that the fact itself was well known and considered in our practical deductions.

Dr. A. E. Benjamin (Minneapolis, Minn.): I do not like to let this paper go without a little comment on it, because I think it is a very important and valuable contribution, important for the reason that it is a step perhaps in advance in our methods of technic in the treatment of our patients before operation. It means comfort to our patients before and after operation. A great many of our laparotomy patients heretofore have been scrubbed and rubbed before the operation. Take, for instance, the cases of acute appendicitis: a great deal of manipulation has been done with harm. It seems to me that more harm than good has resulted by rubbing and scrubbing than if less manipulation had been permitted. For a number of years, perhaps ten years, I have been a great advocate of alcohol externally. It does a great deal of good when applied externally. For instance, I have found in doing a laparotomy, and not having made a diagnosis of gall-stones previous to the operation, if I rubbed alcohol thoroughly over the region of the gall-bladder, and then operated, the operation was followed with no trouble whatsoever. Where I have used alcohol altogether, and nothing else, I have never had any suppuration externally. I think the use of iodine in the strength we use it has been followed by a good deal of harm by causing blisters. I have had several cases of superficial suppuration, blisters having formed. They have caused an endless amount of trouble afterwards, and these patients have suffered more from the blisters than from the operation itself. It has been my habit to neutralize the iodine by the use of alcohol, going over the whole field with alcohol before the operation, and in some cases I have found it is satisfactory to put on the alcohol the night before, leaving it on over night, of the strength of about fifty per cent, and covering it with a piece of oil-silk or rubber tissue, and a little sponging with it previous to the operation has resulted in no trouble whatsoever. I think this question will be solved, and we shall do very little scrubbing in the future, and use some such method as the doctor has outlined.

Dr. Seelig (closing the discussion): I want to thank

Dr. Schwyzer for his intelligent discussion, and, at the same time, wish to reiterate that towards the end of my paper I said it was neither the time nor place to discuss the osmotic phenomena, and I said that rather advisedly. For instance, the question of bases, salts, and acids being the only substances that one can speak of as having the power of osmosis, is contrary to all recent work that has been done with such substances as pyridin, or the older work with sugar.

As regards the use of the word diffusion instead of osmosis, that would lead us merely into what the Germans call a Wortstreit, because in every osmotic experiment diffusion goes on, and we cannot separate diffusion, and after a very wearisome and painful digging at the subject I cannot make out where diffusion ends and osmosis begins, and, this being a clinical body, I left out of consideration that phase of the subject.

As regards Van t' Hoff's theory, I left that part of the subject out of discussion because prominent physiologists claim that Van t' Hoff was wrong and that his theory does not hold. All of us feel that there is such a thing as penetration, but I cannot find asserted anywhere in the literature the idea of penetration with purely physical phenomena of osmosis, and I thought it was apropos to attempt to suggest the possibility. I did not go so far as to say that the phenomena we get are osmotic phenomena: I simply suggested the possibility in the hope of stimulating further work along that direction to see if something could not be definitely worked out.

As regards iodine and the case of septic meningitis, I am much obliged to Dr. Schwyzer for bringing that out. I have never had the boldness to adopt the use of the officinal German tincture of iodine for that reason. I have in some instances used a two per cent solution of iodine in alcohol, but never have used pure iodine in spite of the experimental result I here report. Ehrlich, with his "606" discovery, is striving to kill the spirochetæ and allow the human organism to remain intact. We have got to do the same thing with germicides. If we want to effectually sterilize the field of operation, all we need to do is to put a hot flatiron on it, but we would get undesirable results from the trauma inflicted. With the iodine we have to temper our judgment with mercy to the patient, and use iodine in such strengths as clinical experience has demonstrated to be efficacious as a germicide, and not in such a manner as to be injurious to the individual on whom it is tried.

DEFINITE KNOWLEDGE OBTAINED BY MEANS OF THE *X*-RAY

E. M. Sala, M. D.

ROCK ISLAND, ILLINOIS

While it is possible for an expert photographer to so alter *x*-ray negatives and prints that they may be made to represent most anything, yet there can be no question about its wide range of usefulness in solving the many perplexing problems with which the surgeon is continuously confronted. Within the last sixty days an agent for one of our large *x*-ray houses said that certain physicians had told him that "the *x*-ray was a thing of the past, and it would soon be done away with." Such conclusions can emanate only from one of two causes, either these physicians have fumbled their own *x*-ray work or some one else has fumbled it for them. Some one has well said: "To read the report of finding a renal calculus, a tubercular hip, or a frontal-sinus disease is one thing; to realize the long road of failure and discouragement which the writer traveled to reach that end is quite another."

The man who sells you the machine and tells you it will take any old thing at any old time, puts it in and shows you how it is done; after he is gone your troubles just begin. When you have spoilt about two or three hundred plates and punctured half a dozen tubes, you begin to realize how little you really did know about the business in the beginning. I spent six years trying to get a hip-joint before I succeeded in getting one that I would dare exhibit without an apology. Some one has said that "Not failure but low aim is

crime." The *x*-ray is no longer estopped by the query, Can these things be taken? It is now only how good can they be taken; in other words, it is an exact science.

Much of our work previous to the *x*-ray was problematical. A fracture would be adjusted so that the parts looked all right to the naked eye and let go at that, but today it is different. After being adjusted an *x*-ray is taken, and if improperly adjusted it is treated accordingly. Time was when a surgeon might say that an injury to a joint was a simple sprain and stick to his opinion without fear of contradiction, but today he may be forced to change his opinion when confronted by the *x*-ray findings.

It is surely a great source of satisfaction to be in practice in the present age as compared with the many uncertainties which existed in the practice, say, twenty years ago. In fractures the *x*-ray shows us, many times, a very imperfect adjustment of the bones in what had seemed a perfect adjustment when examined without the aid of the *x*-ray. Frequently, amputations refuse to heal, and it is not always possible for one to say why, without the aid of an *x*-ray. A small piece of bone may have been left in rounding off the edges of the bone, or it may be found that the bone was left long when it should have been short. The case shown in the collection here is a very good illustration of how this happens. Here the surgeon, no doubt, thought the bones were even, but, instead, the fibula is one-half inch longer than the tibia with a sprig of bone extending down fully a half inch further that constantly gave trouble until removed. A condition like this may be solved without the *x*-ray in a thin subject, but in the average individual it would be rather difficult previous to operation. The course of the ureters can be outlined when containing metal catheters; the stomach may be clearly outlined when injected with bis-

Fig. 1. A. (Case 1.)—Shows result obtained before time of the x-ray.

Fig. 1. B. (Case 1.)—Shows a fracture which was adjusted by several physicians without the aid of the x-ray.

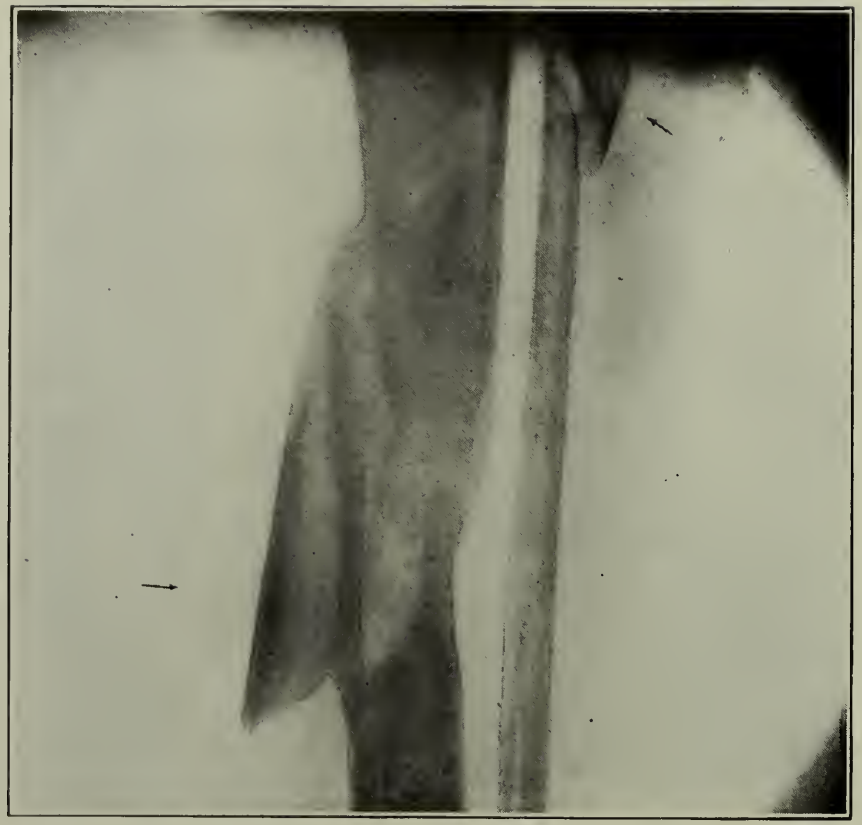

Fig. 2. A. (Case 2.)—Double compound fracture of tibia and comminuted fracture of fibula. Shows how necessary it is to take exposure from two or more directions in order to have a correct understanding of the existing deformity.

Fig. 2. B.—Lateral view of Case 2.

Fig. 3. A. (Case 3.)—Fracture and partial dislocation of left elbow. Arrow No. 1 points to detached external condyle and No. 2 points to internal condyle. Arm is still in splints after a labored effort to adjust the break without operation.

Fig. 3. B. (Case 3.)—Same elbow after adjustment and wiring the condyles in place. It was necessary to open the elbow by incisions in three places, and the tissues were elevated so that we could see clear through the arm in front of the bones. One incision was made where the bone had penetrated through the skin.

Fig. 3. C. (Case 3.)—Lateral view of the same fracture of both condyles before wiring, the upper fragment protruding through the skin.

Fig. 3. D. (Case 3.)—Lateral view of the same fracture after wiring. Elbow was put in splints and kept quiet for six weeks, no passive motion being permitted until the inflammation had entirely subsided. Four months after injury the boy has full use of the arm.

Fig. 4. A. (Case 4.)—A skiagram of a girl 8 years old who swallowed an iron fence-staple. The staple appears in upper right hand corner and is being churned around in the stomach. Picture taken three hours after the staple was swallowed.

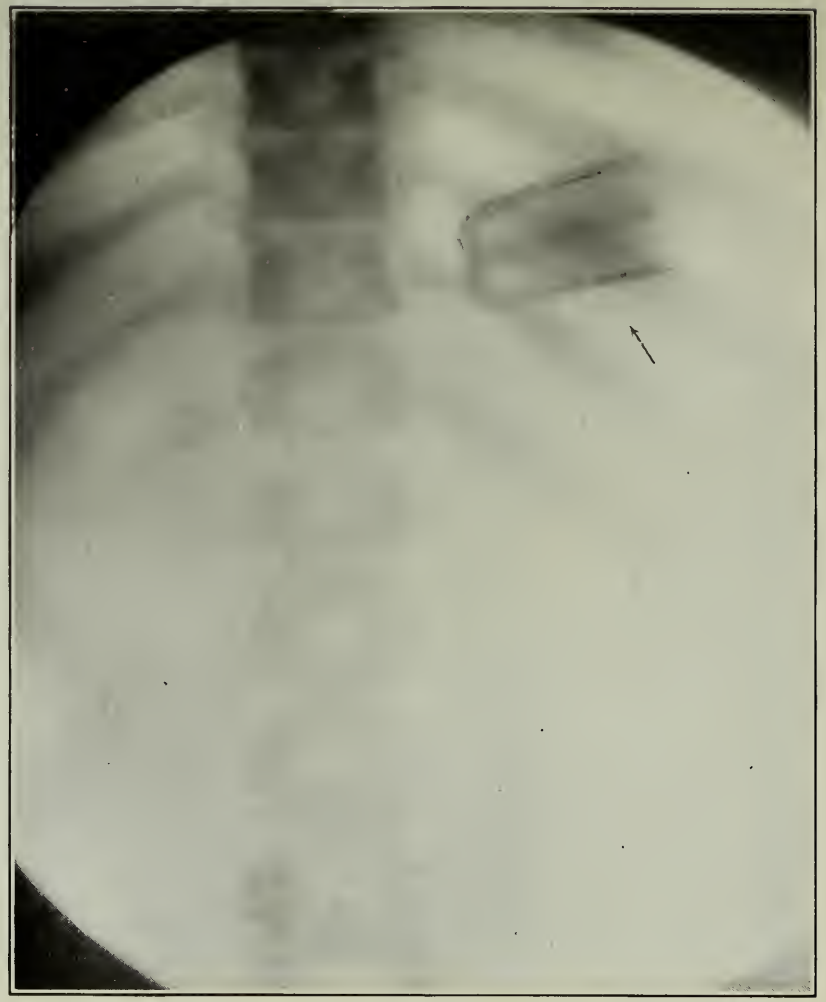

Fig. 4. B. (Case 4.)—Shows staple about to leave the stomach. Here staple made a half turn while being radiographed, and we have a double view of it.

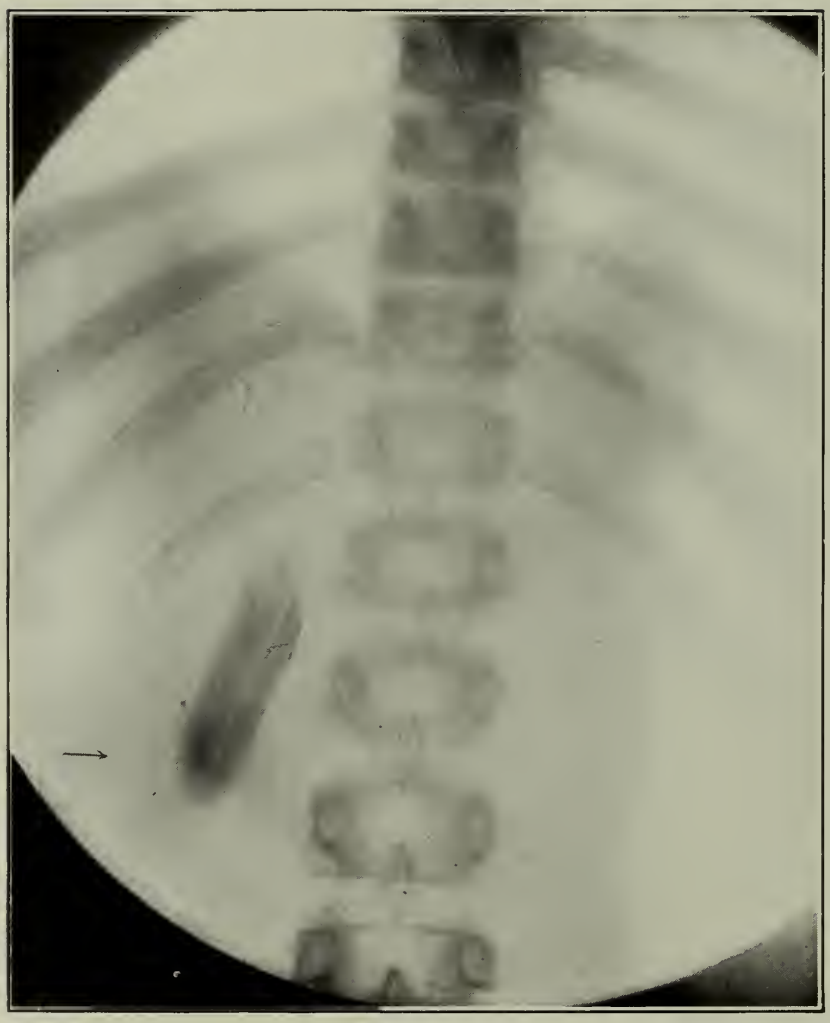

Fig. 4. C. (Case 4.)—Shows staple traversing the descending duodenum on opposite side of spine from A and B and down below last floating rib. Here we also get a partial double view on account of the peristaltic action of the bowel.

Fig. 4. D. (Case 4.)—Shows staple ascending duodenum about the duodenojejunal juncture. It has almost completed a circle and is also a double view. A, B, C, and D were all taken during the same hour, showing the speed such things travel. Staple then had traveled from upper right-hand corner to the jejunum in one hour's time or in four hours after being swallowed.

Fig. 4. E. (Case 4.)—Shows staple about to make the loop of the sigmoid and is still going in right direction.

Fig. 4. F. (Case 4.)—Is practically same as E. E and F were taken 36 hours after A, B, C, and D, and shows staple to a better advantage. No medicine was given the child except an enema, which was given 39 hours after staple was swallowed, when staple was washed away. E and F were each exposed to the *x*-ray nine seconds.

Fig. 5. F. (Case 5.)

Fig. 6. (Case 6.)

Fig. 7. (Case 7.)—Injury to frontal bone with loss of moon-shaped piece of bone. Taken after wound had completely healed.

Fig. 8. (Case 8.)

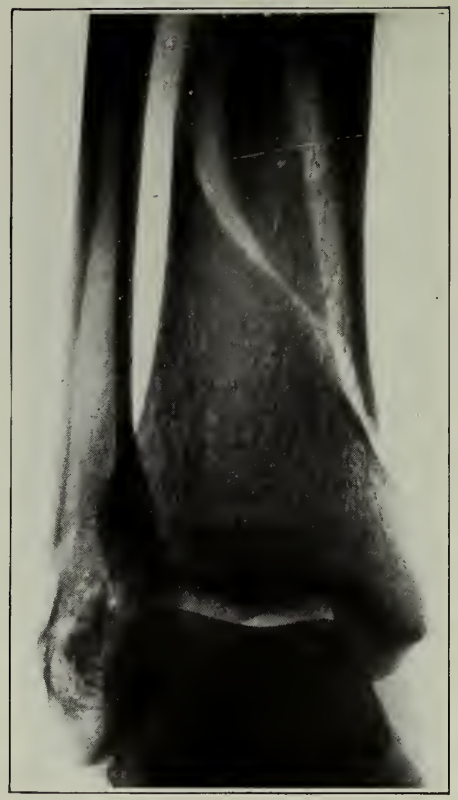

Fig. 9. (Case 9.)—Simple fracture right tibia, which, in appearance, resembles a separate detached piece of bone.

Fig. 10. (Case 10.)—Normal ankle on left and sprained ankle on right with particles of tibia broken off. Such injuries show why some sprained ankles do not recover rapidly, there being fracture in addition to the sprain. These breaks are always overlooked without the aid of an *x*-ray.

Fig. 11. Case 114



Fig. 12.—Spicula of bone left after amputation at inner side of fibula, causing trouble until removed by operation.

Fig. 13. (Case 13.)—Amputated leg, fibula being left one-half inch longer than tibia, with an additional spicula projecting one-fourth inch further.

This leg gave trouble until re-amputated, and the bones made even, which shows the importance of making bones even, or, if either bone is to be left longer, making it the tibia, because it is the larger and the bone that bears the weight of the body, the fibula being only a brace.

Fig. 14. (Case 14.)

Fig. 15. (Case 15.)—Fracture of tip of big toe. Picture also shows outline of several of the nails.

Fig. 16. (Case 16.)—Fracture of external condyle of humerus.

Fig. 17. (Case 17.)—Fracture of the internal condyle of the left humerus, with old dislocation and epiphyseal separation of olecranon.

Fig. 18. (Case 18.)—Backward dislocation of ulna and radius.

Fig. 19. A. (Case 19.)—Dislocation of wrist.

Fig. 19. B. (Case 19.)—Dislocation of wrist.

Fig. 19. C. (Case 19.)—Dislocation of wrist.

Fig. 20. A. (Case 20.)—Fracture of radius,—lateral view.

Fig. 20. B. (Case 20.)—Union of fractured radius in false position

Fig. 21. (Case 21.)—Remains of hand.

Fig. 22. (Case 22.)—Hand and foot taken on same negative, lead-plate covering that half of negative which is not being exposed.

Fig 23.—Right normal shoulder Referred to in Case 21.

Left shoulder showing deformity at the junction of the clavicle and scapula.



Fig. 24.—Undescended tocth in the antrum of Highmore, with probe inserted into antrum through tooth-socket.

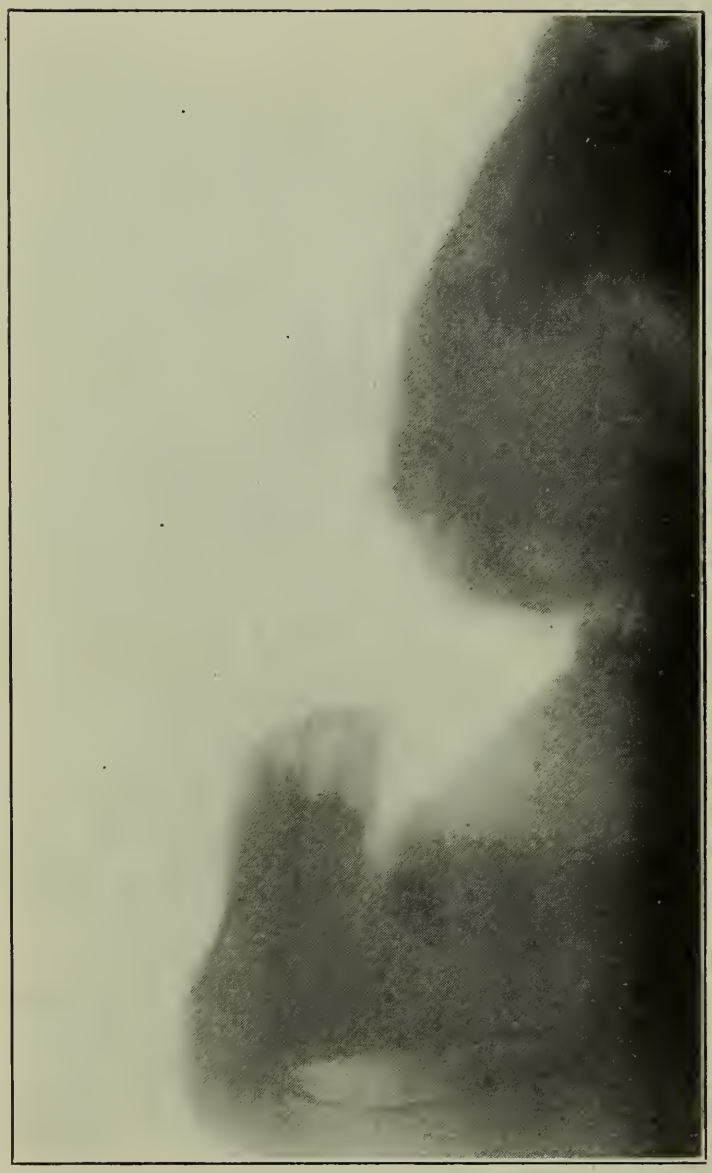

Fig. 25.—A screw in the right mental foramen of woman 71 years of age. Patient had suffered excruciating pain off and on for twelve years, never being entirely free from pain and soreness. For three weeks preceding the insertion of the screw she was unable to take medicine or nourishment without the greatest difficulty. A half inch of nerve was removed, and the screw screwed into the foramen. The nerve was hypertrophied to three times its natural size. The skiagram is taken by looking from behind forward through the mouth, held open by a large cork. Patient has had complete relief from pain and soreness, now seven months.

muth; and the work on the thoracic cavity so beautifully worked out by Beck makes the knowledge we may obtain with the *x*-ray very extensive. The aid which the *x*-ray bears to a correct diagnosis, within its limits of course, cannot be underestimated.

Case 1.—This case illustrates very well what was considered a fairly good result in a fractured femur preceding the time of the *x*-ray. Here we have not to exceed one inch of shortening in a lateral union of a square break. This fracture was adjusted by several physicians and thought to be in perfect position. While the patient has a very good result for a fractured femur, yet it is not quite what we should expect with the aid of the *x*-ray.

Case 2.—This case shows how necessary it is to take exposures from two or more directions, in order to have a correct understanding of the existing deformity. This patient was injured in an automobile accident and escaped only with his life. It was thought best not to operate on him and re-adjust the fragments as they should be, owing to the shock and other conditions present, he having received other serious injuries, the main efforts being exerted in an endeavor to save his leg from amputation. This was accomplished by the aid of an ambulatory splint and the application of plaster-of-Paris casts. The patient now, six months after the accident, is walking on the leg without any apparent evidence of shortening. He has discharged some small pieces of bone and has experienced a rather protracted disability, but the result seems as good as we could have obtained by an operation, as far as usefulness is concerned. New bone has bridged across the gap caused by the displaced fragment of bone, the fragment has grown to the new bone, and the whole leg seems strongest at what would appear to be its weakest point.

Case 3.—This is a case of a broken humerus. Both condyles were broken off into the joint. One of the pictures shows the position after being adjusted by two good physicians, the arm being still in splints as they had applied them. This adjustment is, I believe, as good as it could possibly be without an open operation. The arm was opened at the place where the bone protruded, and it was necessary to open it in two other places in order to re-adjust and wire the bones as they should be. The tissues were elevated above the front of the elbow, away from the bones, so that we could see clear through the arm. The boy, four months after operation, has complete use of his arm.

Case 4.—This case is a girl, 8 years old, who swallowed a fence-staple. The first four skiagrams were taken during one hour's time and show the staple after entering the stomach, then at the pylorus, then in the descending duodenum, and then at about the junction of the duodenum and jejunum. The staple was not aided on its progress by any form of treatment, and on account of its rapid progress we obtained a double view of it at one or two exposures. The last two views were taken thirty-six hours after the first four, and show the staple to a better advantage, evidently on account of its being more stationary. Both of these skiagrams were nine-second exposures. After the last two pictures the patient was given an enema and passed the staple. The last two views make it look as though the staple had turned around in the large bowel, but it was evidently proceeding arch first and was about to make the loop of the sigmoid.

Case 5.—This case was that of a boy, 17 years old, who had swallowed a horse-shoe nail, which had passed through the ileocecal valve and had become lodged in the ascending colon. He was having pain and soreness, together with fever and rapid pulse. The

abdomen was opened, and the nail extracted. It was pushed, point first, through the bowel, and the opening in the bowel was closed with reversed mattress suture with a few Lembert sutures additional. The appendix being adherent was also removed. Recovery was uninterrupted.

Case 6.—This was a case of a large vesical calculus resembling a partly used cake of toilet-soap and a cylindrical stone three inches long, partly in the left ureter and partly in the bladder. The free stone was very easily removed by the introduction of a urethral sound introduced into the bladder and an incision made down onto the point of sound. The other stone could only be removed by cutting through the posterior wall of the bladder, and then it was necessary for us to remove it piece-meal. Whenever we touched it with an instrument it would crumble and seemed to be more a pocket of small stones than one solid stone. The patient did not survive the operation, but died one week later. A post-mortem showed us that he had almost a complete atrophy of the left kidney. The traumatism in the posterior wall of the bladder had caused an induration, which produced a partial obstruction of the bowel. I think, were we to meet a similar case, I should advise removing only the large stone through the bladder and attack the cylindrical stone from the outside and posterior surface of the bladder. However, I believe we can always think of some other way we would do any operation that resulted fatally. This patient was not a very good subject to begin with.

Case 7.—This case is that of a man kicked in the head by a horse. The frontal bone was shattered in a dozen places, the frontal sinus being broken loose as a whole, but still remained attached to the scalp. A piece of bone one inch in diameter was removed from the roof of the orbit, and one of an equal size, which

shows in the picture, was removed from the frontal bone. The frontal sinus was replaced, the loose bones removed, wound drained with two cigarette drains, one entering back of the eyebrow to where bone was removed from the roof of the orbit, and the other in the upper angle of the wound. The patient made a perfect recovery without any disturbance to the eye, and the frontal sinus healed back in place perfectly.

Case 8.—This shows how it is apparently impossible to perfectly adjust a fracture where both bones are broken, as in the forearm and leg. If the large bone is in perfect alignment it may be impossible to line up the smaller bone without an operation.

Case 9.—This case is rather deceptive. It appears as though the bone is broken in two places when, in reality, it is a simple fracture.

Case 10.—This is a case of sprained ankle with particles of the tibia broken off. The two views demonstrate how it is possible to develop a negative so that all the soft tissues and even the tendons disappear, the single foot-view showing a shadow of the tendo-Achilles.

Case 11.—This case shows a depression of the parietal bone caused by being struck in the head with a baseball bat; child, four years of age. The bone continued depressed until the incision in the scalp released the underlying blood-clot, when the bone returned to place by pressure outwards of the brain, no trephining being necessary.

Case 12.—This case shows how a small detached piece of bone may give trouble until relieved. Operation was performed to remove a foot that had been crushed in an elevator accident. A small fragment of bone was accidently overlooked in making amputation and may be seen to the inner side of the end of the

fibula. A sinus continued to discharge for four months, when the leg was radiographed and re-operated on and a small piece of bone removed, after which the sinus promptly healed.

Case 13.—This case shows faulty amputation of the leg, which gave trouble for one year until re-operated on, and the bones made even by amputating the fibula higher up.

Case 14.—This is a fractured fibula treated as a sprained ankle until radiographed, showing the break. This is a mistake easily made on account of the absence of deformity, except swelling about the ankle-joint.

Case 15.—This is a fracture at the end of the big toe, easily overlooked without the aid of an *x*-ray.

Case 16.—This is a fracture of the external condyle of the humerus which it was impossible to adjust without operation. The elbow was opened, and the bone replaced and held in place by silver wire with the joint perfectly restored. The joint was not moved until inflammation had entirely subsided, the custom being not to begin motion for at least six weeks in any fracture into a joint.

Case 17.—This is a fracture of the lower end of the humerus with an old dislocation of the elbow never properly reduced. The humerus was wired, and the dislocation reduced, with good result.

Case 18.—This is a backward dislocation of the ulna and radius, which was easily reduced without an anesthetic.

Case 19.—This is a dislocation of the carpal bones treated as a break.

Case 20.—This is a fracture of the radius, the union being in a false position.

Case 21.—This shows the hand trimmed up after coming in contact with a live wire, receiving 2,200 volts. The hand is shown twice on the same negative, one-half of the negative being covered with a lead plate while the other is being taken. No. 22 was taken the same way, and also No. 23. While these are not the best results that can be had, as our machine was not in good working order, yet they show the point I wish to emphasize, and that is, the advantages of taking an *x*-ray in two or more directions, having it on the same negative for comparison. This feature of *x*-ray work has, no doubt, been written about before, but I have never seen any of the skiagrams, and it is for that reason I wish to offer them. The method might be of use in some court cases. The negative will not be blurred if the lead plate is thick enough. The reason these views are poor is no fault of the method. It was the fault of the rectifier on our machine not working properly, and it was too late to have it remedied in time to make the work perfect for this meeting.

Case 22 is a hand and foot taken on the same negative at different times with the aid of a lead protecting plate.

CONCLUSION

The *x*-ray, when in good working order, is one of the most valued adjuncts to good surgical work we have at our command.

It helps to make surgery a more exact science.

It gives us a much clearer understanding of our cases and will eventually lessen to a great extent the vast number of cripples that were unavoidable previous to the time of the *x*-ray.

DISCUSSION

Dr. Daniel N. Eisendrath (Chicago): There are two pictures I want to show you, particularly, which will bring

out the point mentioned by Dr. Sala, and that is the value of the x-ray in detecting conditions we have scarcely any conception of, especially the condition of ureteral calculi. The specimen I show you is one which was obtained at autopsy. This specimen shows the bladder, the ureter, and the left kidney, with dilated pelvis. In dissecting out the specimen there were several phleboliths, and I thought it would be interesting to lay these phleboliths on the x-ray plate and take a picture of them. There is a deep shadow cast by the phleboliths, and that is interesting because they lay right close to the ureter and enter into the posterior wall of the bladder. In the dissected specimen one could find only one phlebolith, but the x-ray showed several of them. I thought I would take the same specimen and take a wire for passing up through the ureteral catheter and insert it through the ureter up into the pelvis of the kidney. It shows prettily.

Another x-ray plate will show still better the relation of phleboliths to wire passed up through the ureteral catheter. It is seldom we have an opportunity to see a specimen which illustrates this point as well as this one does.

Here is a typical x-ray plate showing the progress we are making now in the x-ray diagnosis of ureteral calculi. But you will notice here to the left of this wire, which has been inserted through the ureter and passed up towards the kidney, a little shadow. At first sight this shadow looks as though it might be a stone in the ureter, but on passing the wire through the ureter we find that this shadow is due to a phlebolith in the ureter, as was found in the post-mortem specimen.

Here are several instances of stones in the ureter, and I can only emphasize the point that was brought out by Dr. Sala as to the great value of the x-ray, not only in the treatment of fractures, but in so many other fields.

Here is a beautiful example of a ureteral calculus. It is a single ureteral calculus shown close to where the ureter enters the bladder. It shows why so many show opposite the spine of the ischium in the pelvic shadow.

In connection with the next specimen there is one point to which I have occasion to call attention several times, and that is the necessity of studying x-ray plates of the kidney region, when the plate is entirely dry, in a shadow-box, and also studying them, if necessary, with an opera-glass. In looking at this picture, at first there is nothing to be seen, but if you will look at it more closely you will see a shadow

lying right behind the twelfth rib. It is a little light shadow, which sometimes can be seen at a distance better than at a close point. This turned out to be a calculus lying close to the upper pole of the kidney behind the twelfth rib. We see that frequently calculi are lying behind the rib and the plate is negative when we have not given sufficient study to it.

So many important points were brought out by Dr. Sala in his paper that it is impossible to cover them in a brief discussion. There are several that have impressed themselves upon me, and, first of all, is the necessity of taking *x*-ray pictures in two directions. This is especially true of fractures of the forearm and fractures of the wrist and hand. Very frequently we find an anteroposterior picture will show no displacement and the lateral picture will show a decided displacement. That is one point.

Another point he mentioned was its value in diagnosing obscure fractures or sprains. Especially is this true of fractures of the metacarpal bones, metatarsals, and all the phalanges. It very frequently happens that we see people who have stubbed fingers or toes, who have sustained a slight crushing injury of the hand, and we cannot understand why pain should persist two or three weeks when there is no deformity and no crepitus, unless we examine these cases systematically. Now that we have *x*-ray laboratories which are at our disposal we should make it a rule, as we do, for instance, here in Chicago, that in every suspicious injury an *x*-ray should be taken, because we find fracture in a large percentage, fully sixty to seventy per cent, of the cases of what we call simple sprains of the toes or hands. This picture I show you illustrates the point very well, and I congratulate Dr. Sala, who is not supposed to be a radiographer by profession, upon the excellence of this picture. It shows the type of fracture which is becoming more and more important. I have two of these cases under observation at the present time, one of them will require immediate wiring for the reason that it cannot be reduced. The patient has been put to sleep, and every effort has been made to reduce it, but without avail.

This is a type of fracture known as the spiral fracture. It is not like the ordinary oblique fracture, and it is stated that sixty per cent of all fractures of the femur, of the tibia, fibula, and humerus, are so-called spiral fractures. What do we mean by a spiral fracture? There is a cork-screw arrangement in the line of fracture, and the great difficulty in

spiral fractures is that it is almost impossible to get the apex, of the lower or upper fragment, usually the apex of the lower fragment, into line with the little crevice left in the upper fragment. They usually slip by each other, and a great many cases requiring wiring in fractures of the long bones are cases of spiral fractures which cannot be reduced.

Another important point brought out by Dr. Sala is the advisability of systematically taking pictures of the radius. I find that a great many of our poor results in the treatment of fractures of the lower end of the radius are due to the fact that we overlook the frequency of impacted fractures of the lower end of the radius. When I first read a German article, three years ago, from the *x*-ray institute in which the observer stated that he found the majority of fractures brought to him were fractures of the lower end of the radius, and that these were impacted, I did not believe the statement. However, when I *x*-rayed them and examined them carefully, I found this statement was true. We now make it a rule in every Colles' fracture to take an *x*-ray picture and break up the impacted fractures. If we do not remember to break up the impaction and reduce the fracture properly, we shall get a poor result.

I cannot emphasize too strongly a great many of the points which Dr. Sala has brought out, but especially this, that practitioners who are situated in a moderate-sized town, such as Dr. Sala is located in, should be enterprising enough to keep on and take such excellent pictures as these.

Dr. Willard Bartlett (St. Louis, Mo.): May I make a remark on one phase of this subject? I, like the rest, have admired these *x*-ray plates,—the negatives and positives.

Both the essayist and the gentleman who opened the discussion (Dr. Eisendrath) referred casually to the wiring of certain of these fractures. Now, I may state in connection with wiring, without any reference to the desirability of the open or closed operation in a given case, that given cases in which the open operation is decided upon,—let me speak most emphatically of the Lane plate, having observed Mr. Lane work in London about six months ago. I have had occasion to screw on steel plates in between forty and fifty cases since that time, and with the exception of fractures of the patella, of which I have had one in this series, and with the further exception of fractures very near the ends of the long bones, I believe that wire has been driven out of business by the Lane plate. Out of a series of between forty and fifty cases, I found use for the wire alone in two

cases. In the others the plate has been used. In the future I believe it will be found that an increasingly larger number will use the Lane plate, and a correspondingly decreasing number will use the wire.

Dr. A. H. Levings (Milwaukee, Wis.): I wish to say a few words with reference to the treatment of fractures. I have listened with a good deal of interest to what Dr. Bartlett said about having put the Lane plates on fifty patients, or forty cases, approximately, of fractures since he returned from London six months ago. I had the pleasure of meeting Mr. Lane in Milwaukee a few weeks ago while on a visit to this country, and at that time discussed with him the question of the universal use of these plates. I asked him, and I would like to ask Dr. Bartlett, whether he did not find it somewhat difficult to find patients who would allow him to operate on every case of fracture. I think any man who has operated on forty cases and used the Lane plates in this number of instances within six months has operated on every case that has come under his observation. I think where fixation is required to immobilize bone fragments that cannot be otherwise immobilized, the Lane plates are infinitely better than wiring, because most of the gentlemen here who have examined *x*-ray plates or skiagrams of fractures they have wired, especially of the femur, have found in many instances that the wires failed to hold the fragments in approximation, and in some instances the deformity and displacement of the fragments were even greater after they had wired the fragments than before they undertook the operation. In regard to Dr. Eisendrath's discussion on spiral fractures of the tibia, which I find are very common, especially in children who fall off bicycles, or in men who have been wrestling and fall with the leg under them, or in men who are stepping off of trains and cars, and who get a twisting motion by the sudden starting up of the vehicle while the weight is placed on one foot which does not move: I have encountered several of these cases. Such fractures are quite common. For some four or five years I have been treating these fractures of the lower extremity without any wiring, without any mechanical fixation whatever, and I have yet to find a fracture that cannot be reduced and held in good approximation without the use of either the Lane plate or the wire. With the collaboration of Dr. Mueller, of this city, some five years ago I devised an apparatus for the mechanical extension of the leg while a plaster cast for

the purpose of immobilization was being put on the leg. This apparatus is not well known, because it was a rather expensive thing to build, and I find in Milwaukee, where we have quite a number of surgeons doing emergency surgery, they were unwilling to pay the sum the instrument is worth.

I will say, in speaking to the paper, that it is a very necessary thing in these days, when the *x*-ray is so generally used for the purpose of diagnosis, for surgeons who are treating these cases to take an *x*-ray of these fractures in every instance, because if an *x*-ray is not taken, and the case is treated, and it passes out of one's hands, it may mean trouble to that physician subsequently. We find the public themselves are learning to go to *x*-ray laboratories, and that many suits for malpractice are begun, and we are subjected to the annoyance of having allegations made with reference to the disastrous results which the patient has suffered as the result of malpractice. If in the beginning we took the precaution to take an *x*-ray, especially as has been so well shown here today, in two planes at right angles to each other of these fractures, if a bad result does follow, we shall at least have something to fall back on which will enable us to offer a defense.

Dr. Emerson F. Root (Salt Lake City, Utah): I wish to make one point in connection with this paper and the discussion regarding the *x*-ray. The writer of the paper was able to tell us exactly what these pictures are, and we take his word for it positively. There is no question about it. But if you go before a court of justice, every juror, every person in the court-room has an idea of the picture, and they read it to suit themselves, and not at all as the one who took the picture intended it should read. No man is so wise that he can offhand read every *x*-ray or very many *x*-ray plates without gradually educating himself up to it, and in cases coming before the courts I think the person whose business it is to explain should insist on having his version of the matter taken by the jurors and by the court.

Dr. Sala (closing the discussion): There are a good many points in the paper which I did not read on account of the length of time which it would consume to do so, and in closing the discussion I shall simply explain one plate. I have been misunderstood with regard to the treatment of fractures which require operation. I am a firm believer in the use of the Lane bone-plate, but I do not think it would be a good substitute for the wire in the cases I have men-

tioned on account of the fractures being into or about the joints.

The picture I wish to call to your attention does not show very well at a distance, but close up it shows beautifully an undescended tooth in the antrum of Highmore with a probe reaching up through the process of the jaw-bone. The tooth was subsequently removed by operation.

PRIMARY SUTURE OF SUBPARIETAL RUPTURE OF THE KIDNEY, WITH REPORT OF A CASE

F. Gregory Connell, M. D.

OSHKOSH, WISCONSIN

Melvin M., school-boy, aged 11 years, at about 8:30 in the morning of October 26th, in attempting to alight from a moving bicycle, slipped and fell, striking his right lumbar region against the edge of the street curbing. There was very severe pain in the right loin, but no collapse, shock, or vomiting, although for a period of about five minutes he was unable to walk because of general weakness with dizziness and nausea. After a short rest, in a sitting doubled over posture, he was able to walk a distance of about half a mile to his home, and as he still complained of very severe pain he was put to bed.

Dr. F. W. A. Brown was called and examined the boy very carefully. There was no fractured rib or evidence of serious injury, the tenderness and rigidity in the lumbar region being the only apparent result of the tumble the boy had taken. The severe pain persisted until about 1:30 p. m., when about eight ounces of bloody urine were passed, after which the pain was markedly lessened. Half an hour later vomiting occurred, after which there was a still greater sense of relief. At about 2:30 p. m. I saw the patient in consultation with Dr. Brown, at which time the boy did not complain of much pain other than a severe and constant ache in the left lumbar region. One was impressed at once by the "bad appearance"

of the patient: the skin was sallow or yellowish and the face had a drawn, anxious expression, despite the fact that the boy was making light of his injury and was asking for some chewing gum. The pulse, temperature, and respiration were normal. There was no dyspnea, but deep inspiration caused pain under the left lower ribs. Abdominal palpation revealed marked rigidity and tenderness in the region of the kidney, more marked posteriorly. Deep palpation was impossible, and the tumor-mass could not be made out, either by palpation or percussion. There was no free fluid demonstrable in the peritoneal cavity, nor was there any external evidence of the injury.

Because of the nature of the trauma, hematuria, and rigidity of the muscles in the region of the kidney, rupture of that organ was diagnosed, and exploratory incision advised. This advice was refused. During the following afternoon and evening the boy was better in that the pain was not so severe, but he was unable to rest because of the constant dull ache at the site of the injury, and the passage of bloody urine about every hour. The act of micturition was without pain or tenesmus. The next morning there was an attack of vomiting, the bloody urination continued, and the patient became drowsy and weaker; the parents became alarmed, realized the seriousness of the boy's condition, and sent him to the hospital for operation.

On admission the patient was very weak, unable to sit up, the face was drawn and pinched, and there was a distinct yellowish tinge to the skin. His only complaint was a dull ache in the lumbar region, with a more severe pain on moving. Examination revealed a distinct fullness in the left iliocostal space with marked tenderness on pressure, there was rigidity of the lumbar and abdominal muscles, and on bimanual palpation a mass could be detected, which was dull

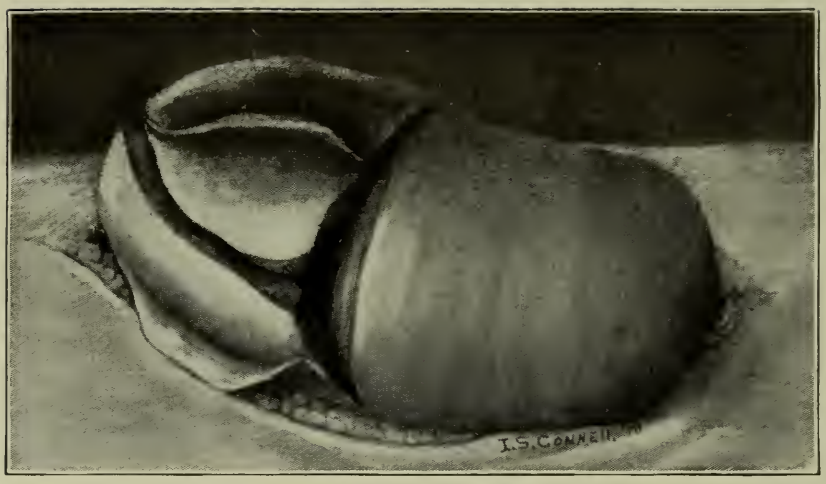

Illustrating the author's case of a stellatic, traumatic rupture of the kidney, extending into the pelvis, in a boy aged 11 years.

on percussion, but there was no free fluid in the peritoneal cavity. The temperature was subnormal; pulse, 130, small and collapsible; and the respirations were 24 and superficial.

Operation was done at St. Mary's Hospital, Oct. 27, 1910, at 2 P. M., under ether anesthesia by Dr. W. P. Wheeler, Dr. F. W. A. Brown assisting. The kidney was approached through the usual lumbar incision, and division of the transversalis fascia revealed the fatty capsule of the kidney through which blood was apparent, similar in appearance to the peritoneum in cases of intra-abdominal hemorrhage. Division of this capsule was followed by the escape of considerable blood and clots. The kidney was promptly delivered through the wound, and examination revealed a stellate tear extending into the pelvis of the organ in the upper pole of the kidney. (Fig. 1.) A transverse tear was situated at about the junction of the upper and middle thirds and extending from side to side, practically separating the upper pole from the remainder of the organ. This upper fragment was divided into two unequal parts by a longitudinal tear extending from the transverse rupture to the upper extremity of the organ. This longitudinal tear was not located in the midline of the convex surface, but was situated about a quarter of an inch behind the midline at its lower part, and about half an inch behind at its upper extremity, on a line probably analogous to the avascular line of Broedel.

After cleansing the margins of the wound of blood-clot by salt sponges that passed into the pelvis, the wounds of the kidney were sutured with chromic catgut mattress stitches, which were inserted deeply into the parenchyma of the organ. Ordinary round-curved needles were employed, and there was no tearing out of the stitches. After these deep mattress stitches were inserted and tied loosely there was ab-

solute control of the bleeding, and a layer of superficial circular or over-and-over stitches were inserted to effect accurate coaptation of the edges of the wound. An effort was made to close the fibrous capsule, but this was found to be impossible. A cigarette-drain was inserted to the lower pole of the kidney, and the lumbar wound was closed except at the passage of the drain.

Recovery was uneventful. There was very little discharge from the wound, no urine, and the drain was removed on Oct. 30th. The patient was discharged with the wound healed, a perfect recovery, on November 13th.

That subparietal rupture of the kidney is not common is shown by the fact that in 1903 Watson[1] was able to collect only 660 cases from the literature. Neilson[2], in 1908, added 34 operated cases, making a total of 694. In the same year Lardennais[3] collected 771 cases (his paper, an inaugural thesis, has not been available in the original).

Since Neilson's report in 1908, I have been able to find either mention or a more or less complete report of 147 additional cases, 79 not operated upon, and 68 operated upon. This rapid recent increase in the number of reported cases would tend to show that the above figures fall far short of the actual number of cases.

The kidney seems to be as well, if not better, protected from injury than other of the abdominal viscera, yet they are the most frequently injured in case of abdominal contusion. The fact that there are two kidneys, one on each side, of course, accounts in a large measure for this frequency.

The theory as to the cause that may explain a majority of the cases is that of Küster, in which the rupture is supposed to be due to hydraulic pressure acting through the full vessels and the pelvis, and

causing the organ to burst along lines radiating from the hilus toward the point of maximum impact against the lower ribs, the opposing resistance being supplied by the vertebral column.

Ruptures of the kidney must be divided into complicated and simple. In the former there are additional injuries to other organs or structures; in the latter the kidney is the only organ damaged. A classification has been based upon the extent of the damage to the kidney, but this is of very little clinical or practical value.

Simple rupture of the kidney is much more common than are the complicated injuries. In Watson's and Neilson's cases 512 were simple and 125 complicated. This approximate proportion is maintained in the report of Frank, in which there were 30 simple and 9 complicated cases.

SYMPTOMATOLOGY

A most important element in the recognition of these cases, is attention to the history of the accident and the nature of the traumatism. Abdominal contusion most liable to cause damage to viscera is that in which there is a sudden, strong impact against the anterior or lateral abdominal wall, often where the patient is taken unawares and the abdominal muscles do not have time to contract in self-defense, such as hoof or fist blows, being struck with a thrown ball, a carriage-pole, a piece of wood from a circular saw, or by a fall against a sharp object. A simple fall upon the feet or muscular action alone may produce rupture of the kidney, and a dozen of the latter variety of cases are on record.

Another type of injury, such as being run over by a wheel or a crush between car-bumpers, more often results in a complicated rupture. There is usually

very little or no external evidence of injury in the former class of cases.

Shock and collapse are often absent or but transitory, and the lack of recognition of this fact has been the cause of mistaken diagnosis and delay in proper treatment in a great many cases.

Pain is usually very severe at the time of the injury. It may be general or localized in the kidney region. Its duration varies greatly, but it is usually present, and is followed by tenderness and a dull ache in the region of the ruptured organ.

Rigidity of the muscles over the kidney, with tenderness on palpation, is practically constant, and is of great importance. Hematuria is generally present. It may be delayed in onset or may occur with the first urination. In cases in which the ureter is blocked with a blood-clot, with a transverse tear of the pelvis or ureter, or with complete pulpification of the organ, hematuria may be absent. It must be remembered that hematuria following trauma in the region of the kidney is not pathognomonic of injury to that organ, as the bleeding may originate in the bladder or urethra, or there may be a hemorrhagic nephritis, idiopathic or other types of bleeding from the kidney.

Tumor in the kidney region may be absent, may develop within a short time, when it is usually due to a perirenal hematoma, or it may be of late development. In such cases it is probably caused by infection or, more rarely, secondary hemorrhage.

The diagnosis of kidney lesion demanding an exploratory incision may generally be based upon a history of a particular abdominal contusion with rigidity, tenderness or tumor, and hematuria.

Treatment may be expectant or operative. A most important feature of the treatment, and of great influence on the result, is a recognition of the indica-

tions for treatment, and the selection of the proper line of treatment for the individual case.

The results are important from this point of view, and Watson's series shows that with expectant treatment 27 per cent of the simple ruptures resulted fatally, and that in the complicated injuries the death-rate was 91 per cent.

Radical operative treatment, i. e., nephrectomy, resulted as follows in Watson's and Neilson's series:

Complicated, 51 cases, with 21 deaths.

Simple, 132 cases, with 30 deaths.

Conservative operative treatment, i. e., gauze packing, drainage, or suture, met with the following results:

Complicated, 18, with 7 deaths.

Simple, 107, with 9 deaths.

In these 125 cases, gauze pack or drainage was done 115 times, with 16 deaths; suture of the renal wound or wounds was done 10 times, with no fatality.

The decision between expectant and operative treatment is a momentous one, as the fate of the patient often rests with this decision.

Neilson says, "So-called expectant treatment is permissible only in cases in which the local symptoms are insignificant, constitutional symptoms absent, and slight hematuria alone directs attention to the probability of renal injury." Yet there are many severely damaged kidneys that, if left alone, will end fatally or cause prolonged illness, in which the local symptoms are insignificant, the constitutional symptoms absent, and with but slight hematuria.

There may be no differential sign or symptom between slight injury and complete rupture, therefore it would seem advisable to expose the kidney and arrive at a positive determination as to the extent of the injury in every case in which we can arrive at a probable diagnosis of injury of the kidney, and not to

guess at the seriousness or the triviality of the injury. By so doing a certain number of unnecessary exposures of the kidney will be made, but, on the other hand, a certain number of deaths will be prevented, and many prolonged illnesses and unsatisfactory results will be replaced by prompt and satisfactory recovery. As it is impossible in certain cases to separate the slight from the extensive injury it behooves one to treat all cases as though they were serious until they have been proven to be otherwise.

All operations for rupture must be exploratory at the onset and may then be either radical or conservative.

Nephrectomy has been employed quite extensively, in the past, but from a theoretical point of view; from the experiments of Dolgoff[4], who found that severe laceration, even tearing the organ in halves, in dogs, did not result fatally, and from the clinical evidence and the frequent satisfactory recovery after conservative measures, it would seem that nephrectomy might be more frequently replaced by packing, drainage or suture.

Gauze packing or drainage is the most common method of conserving damaged kidney—115 times in 125 cases in which conservation was attempted.

Primary suture has been performed on but few occasions, though it is the ideal method of dealing with such injuries. Watson was able to collect 8 cases, and Neilson added 2 that were treated in this manner. Since the report of the latter I have been able to find reports of 3 additional cases in the literature, which, with the case reported in this contribution, makes a total of 14. In these 14 cases there was no death, and only two unsatisfactory results, in one, Delbet, a secondary nephrectomy was necessary, and in the second, Watson, a pseudohydronephrosis

and fistula resulted. In every case the sutures, when placed, caused satisfactory hemostasis.

In one of Griffith's cases, a man 48 years of age, the mattress sutures pulled through the very friable organ, and the fibrofatty capsule was sutured enclosing the kidney as in a bag, with a satisfactory outcome. Dolgoff found that wounds of the kidney healed much more rapidly if the capsule was preserved, and especially if its cut edges were united. In the writer's personal case the capsule of the upper third of the organ could not be united, yet the result was entirely satisfactory. In this case the wound was closed with interrupted mattress stitches that passed deeply into the parenchyma, and the margins of the wound were then accurately coapted by over-and-over superficial stitches.

In Fredet's case the patient had a nephritis, and it was for this reason that nephrectomy was not done. As a consequence of the most encouraging result in this case Fredet, in his enthusiasm, says, "Nephrectomy is only indicated as a late operation where there is widespread infection."

Synopsis of cases collected from the literature since Neilson's article:

Griffith: Male, 22, running, slipped and fell, striking left side below the ribs against the sharp edge of a piece of coal. Was able to walk some distance and climb two ladders; felt generally bad, but had no particular pain in side. Five minutes after injury urinated what seemed to be pure blood, after which he felt much worse and nearly fainted. On admission to the hospital, he complained of pain all over the abdomen, but more especially in the left lumbar region. One and three-quarters hours after admission, the kidney was delivered through oblique lumbar incision and was found to be torn on its posterior aspect at about the middle, extending from the convex surface to the

hilum. The wound was sutured with catgut, which controlled hemorrhage, a gauze wick was inserted to the kidney, and the lumbar wound was closed. The patient was discharged well on the eighteenth day.

Griffith: Male, 48, was struck on the left loin by one end of a heavy timber. On admission to the hospital shortly after the injury, the patient was in a kneeling posture, being unable to either sit or lie down because of the intense pain. Pulse was good, but there was vomiting of bile, tenderness, and dullness in the region of the kidney with hematuria. Exploration revealed the lower third of the kidney nearly detached, with a longitudinal tear extending along the midline of the convex surface of the upper portion. Mattress sutures were inserted to close the wounds, but many of them cut through the abnormally friable organ. The fibrofatty capsule was then sutured, enclosing the kidney as in a bag. The lumbar wound was closed with a tube drain reaching to the capsule. The patient was discharged well on the twenty-third day.

Fredet: Male, was struck in left flank by a heavy falling body; there was brief loss of consciousness, followed by severe pain in the left side with a hematoma, no free fluid in the peritoneal cavity, catheterization revealed hematuria. Exploration revealed lesions on anterior and posterior surfaces of the kidney. Nephrectomy was thought to be indicated, but because of a nephritis it was deemed safer to suture the tears in the organ. Recovery.

CONCLUSIONS

1. Owing to the rapid recent increase in the number of reported cases, there is reason to believe that subparietal rupture of the kidney is more frequent than the literature would lead one to believe.

2. Shock, injury to other organs, and external evidence of trauma are frequently absent.

3. History of an abdominal contusion, followed by rigidity and hematuria, is sufficient to lead to an exposure of the organ.

4. Slight lesions and complete rupture of the kidney cannot be differentiated by clinical signs or symptoms.

5. Proof of the absence of serious rupture is called for before instituting the so-called expectant treatment.

6. Nephrectomy should be reserved for very extensive disintegration of the organ.

7. Conservative treatment, preferably by suture, is indicated in the majority of cases.

LITERATURE

1. Watson: Boston M. & S. J., 1903, vol. CXLIX, Nos. 2 and 3, p. 29.
2. Neilson: Am. Jour. M. Sci. 1908, vol. CXXXV, No. 1, p. 54.
3. Lardennais: These de Paris, March, 1908.
Lardennais: Zeit. f. Chir., 1908, No. 45, p. 1328.
Lardennais: Jour. de Chir., May, 1908.
4. Dolgoff: N. Y. Med. Jour., 1900, Vol. 73, p. 311.

COLLECTED CASES

Operated cases:
Tilton: Ann. of Surg., 1909, Vol. 50, p. 812.
Nassau: Ann. of Surg., 1907, Vol. 45, p. 792.
Eisendrath and Herzog: Ann. of Surg., 1908, Vol. 48, p. 709.
Bauman and Lower: Jour. A. M. A., May 1, 1909, Vol. LII, p. 1401.
Fredet: Rev. de Gyn. et de Chir. Abd., 1909, No. 2.
Surg. Gyn. and Obst. 1909, Vol. 9, p. 696.
Bugbee: Medical Record, Nov. 5, 1910.
Connell:
Reporting one case each.
Griffith: Brit. Med. Jour., April 25, 1908, p. 979.
Kaarsberger: Jour. A. M. A., August 21, 1909, Vol. LIII.
Fischer: Zeit. f. Chir., 1909, No. 33, p. 1156.
Martin: Old Dom. Jour. Med. and Chir., 1910, Vol. X.
Reporting two cases each:
Rossi: Zeit. f. Chir., 1908, No. 16, p. 510.
Ponomarew: Zeit. f. Chir., 1909, No. 13, p. 477.
Reporting three cases each:
Gibson: In a personal communication reports four cases.
Yoshikawa: Zeit. f. Chir., 1909, No. 18, p. 655.
Frank: Archiv. f. Klin. Chir., 1907, No. 2.
Frank: Year Book, Murphy, 1908, p. 535.
Reporting five cases each:
Brewer: Am. J. M. Sci., May, 1908, Vol. CXXXV, No. 5, p. 635.
Reporting six cases each:
Johnson: Ann. Surg., 1909, Vol. 50, p. 715.
Reporting and citing seven cases:
Tromifow: Zeit. f. Chir., 1908, No. 10, p. 312.
Cites twenty cases from the Russian literature.
The non-operative cases were reported by Frank, 34; Ponomarew, 29; Trofimow, 13; and Rossi, 3.

DISCUSSION

Dr. William J. Frick (Kansas City, Mo.): I have listened to Dr. Connell's paper with much interest. I wish to emphasize the fact that heavy blows or falls, striking on or about the lumbar region, should always be regarded as serious. The appearance of hematuria following such injuries, is sufficient evidence upon which to make a diagnosis of rupture of the kidney, although the absence of hematuria following such injuries is not always absolute proof that the kidney has not been injured.

In one complicated case of subparietal rupture of the kidney, hematuria was very slight, although the damage to the kidney was beyond repair. The kidney wound was packed, and the patient died after eight hours. Injuries to the kidney, I am sure, are nearly always followed by hematuria, but this is not invariably true. In a case of gunshot wound of the kidney there was not a trace of blood in the urine, although a tumor in the lumbar region was apparent, and incision showed that the perirenal space was filled with blood. When a diagnosis of rupture of the kidney is made that kidney should be exposed by a lumbar incision, especially if it be an uncomplicated case, as this is the only means we have of determining the extent of damage done to that kidney. We cannot depend upon the amount of hematuria or any other sign.

The question of whether a conservative operation or a nephrectomy should be done must be decided. The well-recognized ability of kidney-tissue to repair itself is sufficient reason to attempt conservative surgery in these cases. Nephrectomy should not be done unless the kidney parenchyma is so injured as to preclude the possibility of saving enough of it to be of functional value, or perhaps unless the injury to the renal vessels is so great as seriously to interfere with the nutrition of the organ. I agree with Dr. Connell that conservative surgery by suture methods is preferable in the majority of cases. The treatment by gauze packing, especially in cases of severe hemorrhage, serves very well. It is probably the only way we can control some very severe hemorrhages, but the continued presence of gauze in the wound may lead to infection, or, if the gauze should be packed into the kidney wound, it may lead to a permanent fistula. The removal of the gauze later on may cause secondary hemorrhage. The suture described by Dr. Connell seems to me to meet the demands of the conditions encountered in these cases.

Dr. George N. Krieder (Springfield, Ill.): If I may combine a remark referring to Dr. Sala's paper and this one, I should say that with the latest development of the *x*-ray picture, it is possible to get an excellent view of the kidney. We have a picture taken by the Snook type of ray machine showing very definitely the outline of the kidney, differentiating the pelvis from the substance of the kidney.

Another valuable help I made use of in one case, and might be of advantage also in connection with the *x*-ray, is to give the patient methylene blue. This would undoubtedly cause a staining of the tissues about the injured kidney, and with this an improvement in the radiogram. I am sure it will be of great assistance in the diagnosis of these cases.

Dr. B. B. Davis (Omaha, Neb.): I feel like confirming as strongly as I can the points made by Dr. Connell, because I believe that a kidney when injured is a very much-abused organ. I think a great many unnecessary nephrectomies have been done. I think we are beginning to realize something of the wonderful reparative power that the kidney possesses, and if we stop to consider the amount of manipulation done the kidney in the light of operations that have been performed upon it, the fixation of kidneys, where stones have been removed and the kidney almost cut in two in doing it, we must admit the ability of the kidney to repair is very great. I have had one case in which I amputated the lower end of the kidney, removing about one-third of the organ, and putting in a mattress suture below, with recovery of the patient. I believe that in many of these cases the suture is very much to be preferred to gauze drainage or gauze used to control hemorrhage.

If it is permissible, I would like to place on record one case which shows that some kidneys cannot be retained. A few months ago, a bridge-carpenter at work on a railroad bridge got down by the side of the bridge between pieces of timber to allow the train to pass by. The train started at Plattsmouth, where they loaded it with coal, and a large piece of coal weighing one hundred pounds struck this man in the back, on the right side of the spine, extending to the right lumbar region. He was precipitated from the bridge eight or ten feet, picked up unconscious, as Dr. Livingston of Plattsmouth reported to me. He had a fracture of the third and fourth ribs on the right side, with a penetrating wound of the lung, as demonstrated by a large amount of frothy blood which he spat up for the next three or four days, and

five hours after the operation he passed bloody urine. This was the first intimation of injury to the kidney. His condition on the second day was serious, and it was determined to bring him to Omaha, and this was done on the morning of the third day, or forty-eight hours from the time of the hematuria. At that time he was spitting up the frothy blood. He had a very extensive emphysema, due to the lung injury. In addition to that, he had an extremely rigid abdominal wall, especially on the right side, with dullness on percussion from about the median line over to the right flank. It was determined that this man had sustained a severe injury. I made an incision along the right linea semilunaris, and immediately met with a large amount of blood-clots in the abdominal cavity, which were scooped out, but I saw no fresh hemorrhage within the abdominal cavity, and reaching over toward the ascending colon and drawing it inward, I found that blood was coming from behind. I stripped off the peritoneum over to that side, got at the kidney, the kidney being torn in two parts, with lacerated wounds up and down, and on raising it up found there was nothing holding the kidney except the ureter and small nerve. Both the renal artery and vein had been crushed entirely in two. It was a mystery that this man did not bleed to death. He was extremely weak, and was absolutely pulseless at the radial artery, but the reason he did not die probably was that quick coagulation had taken place due to the weak heart. But it struck me as an extreme case; and another thing about it was the extremely rapid recovery. This man was up and about three weeks from the time of the accident and made a perfect recovery so far as I know—at least he did after he settled with the railroad company.

Dr. F. A. Dunsmoor (Minneapolis, Minn.): There is one point which might be added to what has been brought out, and that is, it is probably not the escape of blood which produces death in these cases. I am sure it is a mixture with the urine, and its absorption into the tissues which produce it, unless it is a complicated case in which the abdominal cavity is contaminated.

I have seen cases of laceration of the kidney which have progressed to operation, particularly those which related to calculus or tumor. I have seen cases which have worried me considerably when the kidney was at first exposed, and the terrific gush of blood which escaped seemed alarming. Pressure against the kidney itself, when the tissues of the

kidney were widely lacerated, would usually control the hemorrhage, and these cases do not, as a rule, require suture of the mattress type to hold the parts so well together, if you put in a drainage tube to remove the deleterious matter without making ligation.

It has been very rare, with one exception, that I have ever had to put a suture through the kidney substance. There are these other exceptions, when the afferent or efferent vessels which supply the kidney are torn across, and we must take care of those by ligation, but so far as hemorrhage from the substance of the kidney itself or the cortex, or even from the tubules, is concerned, I have never seen a failure to control hemorrhage, if the kidney tissue was pulled back and held for a time with forceps, with a pad on the inside, or by packing the external capsule and putting it tightly around it, so that the collections do not communicate with the abdominal cavity.

Dr. Arnold Schwyzer (St. Paul, Minn.): There are several points of interest which might be discussed in connection with this paper, but the one I would like to mention first is the diagnosis. The diagnosis depends mainly on the history of blood in the urine. The gentleman who opened the discussion (Dr. Frick) stated that the blood in the urine may be very scant. That reminds me of a very interesting case I have had in that line. The first urine that was passed was drawn with catheter in the hospital. It was clear but not examined microscopically. When we examined the urine for blood we found absolutely none, and that was a few hours after the patient sustained the injury. In such cases I think the first urine ought to be examined both macroscopically and microscopically. This particular case was interesting for a number of reasons. The patient was run over by a wagon and brought to the hospital with no external injury, but with the most intense dyspnea I have ever seen in my life. There was no cyanosis that we could detect. The individual was very pale (here Dr. Schwyzer illustrated the patient's method of intense and rapid breathing). This condition continued for about two hours, during which time the patient was watched carefully, shortly after which he died. Autopsy showed that the kidney was crushed and partly torn. There was also a thrombus in the renal vein which extended up near the right auricle. A long embolus could be pulled out from the pulmonary artery. It was comparatively thin. It was caught at the bifurcation of the pulmonary artery and

apparently blocked the pulmonary artery, but not quite completely, so that life was preserved for two or three hours. Today we could in a case like this try Trendelenburg's operation, i. e., tying temporarily the pulmonary artery at the base of the heart, and from a slit in the pulmonary artery one could attempt to extract the thrombus.

As to the treatment in the more favorable cases it was stated that we should either treat them conservatively or excise the kidney. I would like to mention the fact that there are quite a number of cases on record where only one pole or one-half of the kidney was crushed, and when the crushed parts are lying hopelessly loose, resection of that part of the kidney would be quite feasible.

Dr. A. W. Abbott (Minneapolis, Minn.): I wish to say a word or two in confirmation of what Dr. Connell has said, but my remarks will have reference more particularly to the ultimate results. I wish to speak of some experiments made by Dr. J. Frank Corbett, of Minneapolis, for the purpose of determining the ultimate results of injury to the kidney. In the first place, he showed that where the kidney has been incised and the capsule only sewed together, there was bleeding in the kidney which was followed by inflammatory trouble, and then by the formation of a scar, and a large part of the kidney was rendered useless. The same results followed the use of packing. The best results were obtained by sutures which were passed through the kidney above the upper limits of the pyramids. These sutures were followed by less scar-formation and less injury to the kidney structure.

Dr. Daniel N. Eisendrath (Chicago): Nothing stimulates discussion like difference of opinion. I want to endorse the stand taken in this discussion by Dr. Davis in contradistinction to that taken by Drs. Connell and Frick, and my experience is based on a personal observation of fifteen cases of subparietal rupture of the kidney. The conclusion has been forced more and more upon me from a study of these cases that the more conservative we are in the treatment of subparietal rupture of the kidney, the greater will be our percentage of recoveries; and I think this tendency is reflected in the foreign literature on this subject. With the exception of cases like the one mentioned by Dr. Davis, where there is a communication at the point of rupture with the peritoneal cavity, and hemorrhage takes place into the free peritoneal cavity, and the clinical signs are similar to those of rupture of the spleen or liver. or where a tumor is forming so rapidly that it looks as if an almost fatal hemorrhage is taking

place in the extra-peritoneal tissues, or there is elevation of temperature due to infection, the more frequently we leave such cases alone, the better off we shall be.

With regard to nephrectomy: Let us take the second case mentioned by Dr. Connell. I have seen some extremely severe cases in which I thought I should have to do nephrectomy, but I have watched these patients bleed and bleed, have simply left them alone, and they have made complete recoveries. Why do they recover? Granted the kidney is extensively destroyed, we know that these patients are not good subjects for operation. They are suffering from considerable shock, and the manipulation necessary to grasp the bleeding artery, which perhaps has already become occluded by blood-clot, would doubtless start bleeding in a field which is all torn up by blood-clots, and pierce the tissues where it is difficult to see where the renal artery is, and we can oftentimes do more harm by that interference than if we left these patients alone. We know from our experimental work on the kidney that if we block the ureter, or tie off the renal vessels, and leave the kidney *in situ,* that kidney undergoes complete atrophy, and within a comparatively short period of a few months the kidney will be simply a mass of cicatricial tissue. That undoubtedly takes place in a certain proportion of cases where the kidney has been severely injured. All of the cases were not grouped under this series of fifteen cases because rupture of the kidney was accidental, the patients having died from rupture of the spleen, and there was one case of rupture of the liver. One case shows particularly the value of simple conservative treatment. This patient entered the Cook County Hospital on another service about six months before I saw him. He had all the symptoms of rupture of the kidney. A swelling of considerable size, which appeared in the loin, was incised and urine escaped. The urine escaped for six months from that time until I saw the patient when, on account of urinary fistula following the rupture, I drained the kidney region, and the patient got well. This case was reported and published in the Annals of Surgery three years ago. I believe there are a great many of these cases which, if we simply watch them, will tampon themselves, and the patients will be better off.

Dr. E. Wyllys Andrews (Chicago): I missed the opportunity of hearing Dr. Connell's paper, although Dr. Connell was good enough to furnish me in advance a complete abstract of it.

I have seen a man with a ruptured kidney on whom I

had operated and declined to remove the kidney, because I thought I had successfully ligated the bleeding points, but about three days afterwards he got another profuse hemorrhage and death in a few minutes. We cannot get away altogether from the old teaching and experience, that a ruptured kidney is apt to terminate fatally if treated conservatively, that is, nothing being done in the way of interference. I suppose that many of these cases would get well if left alone. It becomes a question of how far we are justified in allowing a percentage of them to perish before our eyes, just as a bleeding typhoid patient dies from intestinal perforation, doing nothing, letting one violent hemorrhage occur after another. But it does not necessarily follow that nephrectomy is the only operation of choice, for sometimes we can, as I have done in the spleen and liver, make a closure operation. I see no reason why one may not, in addition to ligating points which do not bleed at the time we operate, always close the kidney with rows of mattress sutures, as we do when we split the kidney, and the operation under aseptic surroundings might easily give a percentage of successful results, which would rank with nephrectomy as a life-saving operation.

The argument of the last speaker (Dr. Eisendrath) that the kidney becomes atrophic, seems to me to carry weight in favor of extirpation rather than against it, unless we take the ground that extirpation, *per se,* in a patient so weakened is to be considered highly dangerous. Nephrectomy is a reasonably simple and quick operation if done through the loin. I have not had personally quite as many as fifteen cases of subparietal rupture of the kidney, but out of the number I have treated by nephrectomy I have lost one, and I have seen at least two which I felt reasonably certain would have recovered had I not practiced conservatism.

Dr. Walter Courtney (Brainerd, Minn.): I realize that discussion of this subject has now been pretty well drawn out, but as most of us see comparatively few of these cases, perhaps full discussion will be profitable to all of us.

With reference to the question of diagnosis: What impressed me rather forcibly, both in the paper and in the discussion, was the omission of the differential diagnosis between contusion and rupture of the kidney. On this point must hang the question of delay or immediate operation. I have seen a good many cases of injury of the kidney where it did not seem necessary to resort to immediate operation, and by waiting a few days the hemorrhage would disappear from

the urine and other symptoms clear up, thus showing that the injury had been practically nothing more than a contusion. In the absence of symptoms of alarming hemorrhage, there is scarcely likely to be any necessity for immediate operation.

The one point in diagnosis that has guided me more than any other in regard to serious injury of the kidney, is enlargement and extended regional dullness. If these are not present, and there is no well-marked evidence of internal hemorrhage, we can afford to wait, some hours or days at least, before undertaking operation.

A secondary anemia may be quite pronounced at a late date in the case. I have seen several of these and where operation had not been performed early. In one of my cases, I received the patient at the end of a month when he was profoundly anemic and had a large amount of blood appearing daily in the urine. At operation, I found the middle third of the kidney entirely necrotic. This portion was exexcised, and the remaining portions, the two poles, were sutured together. The patient recovered in three weeks.

I may say, as regards operative procedure, I have never yet seen in my own work a case where I thought nephrectomy was necessary. Most of my cases have recovered by simpler means: opening, draining, tamponing and suturing, or, as the case might indicate, anything short of nephrectomy.

Of course, I realize that the class of cases mentioned by Dr. Eisendrath, those with severe complications, may require nephrectomy, but I think we should be very conservative in our treatment of injuries of this organ. Someone, in discussion, has said the kidney will stand an immense amount of tinkering and abuse; experience in operation shows us that the organ has an immense amount of vitality.

Dr. James E. Moore (Minneapolis, Minn.): Some little time ago, when we learned we could remove the kidney, we were prone to remove it under comparatively slight provocation. It seems to me that it is only in exceptional cases when a nephrectomy is justified for ruptured kidney.

The possibility of a mistake in diagnosis from hemorrhage with an unruptured kidney was well illustrated by a patient brought into the University Hospital recently, thirteen days after he had been thrown in a runaway accident, and presumably had sustained a rupture of the kidney. At any rate, he came to us in a moribund condition, with his bladder full

of clotted blood. At the post-mortem we found that he had sustained a rupture of one of the terminal branches of the renal artery just before it entered the kidney, and that the presence of blood in the urine was accounted for from the fact that the pressure of the blood had been transmitted along and broken through into the pelvis of the kidney at a point below, allowing the blood to get through into the pelvis and down the ureter into the bladder.

Dr. Donald Macrae (Council Bluffs, Iowa): I want to ask one question. The doctor has gone through the various stages of the treatment. Two or three cases I have seen have puzzled me, for the reason that there was no tumefaction of any kind in the loin, and yet the symptom of hematuria and shock pointed to rupture or, at least, contusion of the kidney. The essayist said himself that this tumefaction is sometimes late in appearing. The question arises as to whether or not it is not difficult to differentiate between a post-peritoneal or subperitoneal rupture of the kidney and an intra-peritoneal rupture. It is not always possible to find a small opening in the peritoneum, and the distinguishing feature is sometimes difficult, even at operation. I am not much afraid of allowing these cases to remain quiescent if I am positive that the injury is subperitoneal. If the injury is intra-peritoneal, then the case requires immediate treatment. If the contusion is posterior to the peritoneum, a few hours' or a few days' delay is a matter of little moment. I recall two cases on which I operated about six days after rupture of the kidney, one due to a horse kick, and the other to falling off of a freight-car. In both of these cases an immense amount of pus and urine gushed out after free incision; drainage was instituted, and both recovered. One patient had a urinary fistula for six or eight months before complete healing occurred. It seems to me that the middle ground is best to take in the consideration of these cases. If we can make a positive diagnosis of post-peritoneal rupture or contusion, delay is not dangerous. On the other hand, if we find a patient is going to the bad, we should resort to simple incision with drainage, or whatever is necessary to be done. I take the middle ground, that it is better not to fuss with the organ. It is unnecessary to destroy the vitality of the surrounding parts, thus making a beautiful medium through which infection may take place. I think it is very much like a large abscess of the kidney, drain and get out. We should find the point of hemorrhage, put in drainage, and pack if necessary, let

the patient alone, and doubtless he or she, as the case may be, will recover.

So far as suturing the kidney is concerned the records show that the results are exceptionally good in experienced hands; but we have not all got the surgical dexterity that our friend from Oshkosh (Dr. Connell) has, and as a great many of these cases occur in the country where I live, we have to operate sometimes under the most unfavorable circumstances. For us fellows it is better to resort simply to drainage and let nature take care of the rest. It seems to me, however, that the great question to determine is, Have we to deal with an intra- or extra-peritoneal rupture. In one delay is best; in the latter immediate interference, both posteriorly and anteriorly, is imperative.

INTUSSUSCEPTION, WITH SPECIAL REFERENCE TO ADULTS

Ellsworth Eliot, M. D.

AND

James A. Corscaden, M. D.

NEW YORK CITY, N. Y.

The discussion of changes in peristaltic activity leading to the development of intussusception, and the results of observation in physiological laboratories of a symmetrical stimulation of different segments of the intestinal tract, have been so fully presented by different writers that further consideration of that part of the subject is unnecessary.

While intussusception in infants and children is carefully and exhaustively described in both text-books and the current literature, the consideration of the same lesion in adults is almost universally neglected. That intussusception in adults is uncommon cannot be denied, but the fact that it is sufficiently frequent to warrant careful consideration is amply proved by an analysis of the cases admitted to the service of any general hospital in a stated period of time, such as twenty or twenty-five years. Such a tabulated list of 115 cases from the records of St. Thomas's Hospital in London, from 1875 to 1900, was published by Pitts in the *Brit. Med. Journal* (1901-2; p. 574), and of these about 10 per cent occurred in adults over fifteen. In a similar series of 59 cases observed in the *Scot. Med. and Surg. Journal,* 1906, xix, during a period of ten years prior to 1905, reported by Mc-

Gregor, four were in adults over twenty-one. Codman, in the *Boston Med. and Surg. Journal* for 1908, 158, pages 439-446, states that of 27 cases of intussusception in the Massachusetts General Hospital during the ten years prior to 1908, nine occurred in adults. In this connection the older statistics of Leichtenstern (*Prag. Monat.,* 1874), based upon the study of more than 500 cases and showing a percentage of 45 in adults, must be discarded, for they were evidently gathered from current literature at a time when intussusception in infants was frequently unrecognized, or discovered only at autopsy, and similarly the statistics of Gibson, published in the *Med. Record* for 1897, in which of 239 cases 60 occurred in adults over seventeen, are of comparatively little value in demonstrating the relative frequency of intussusception in adults and children.

Of very considerable interest is a comparison of what may be termed the exciting causes in children and in adults. In the former the different kinds of acute intestinal disturbance resulting from improper food preponderate. In infants any inflammation or other pathological change in the vermiform appendix, contributes very slightly, if at all, to the development of intussusception. In young children, however, the writer has collected 18 instances between the years of two and seven in which an inverted appendix was probably the cause of a cecal intussusception, while only three instances of the same condition could be found in adults.

Trauma is frequently mentioned as a possible cause of intussusception. In infants it obtains only in the sense that the muscular effort of crying and straining unquestionably increases a pre-existing intussusception, and may even be considered responsible for its initial formation. In adults, on the other hand, trauma is infrequent, and even when mentioned as a

cause may, by some, be regarded as a mere coincidence. Moreover, it is not always received in the same way. Usually a history of some sudden excessive exertion, as in heavy lifting, is said to have directly preceded the onset of the acute obstruction, while less frequently the intussusception is ascribed to a blow on some part of the anterior abdominal wall. In Case 163, that of an actor in vaudeville, the patient had daily held a number of men on the rigid abdomen. After one of these performances, acute obstruction developed, and operation disclosed an intussusception due to an inverted Meckel's diverticulum with a subserous lipoma at its apex, an unusual combination of three so-called exciting causes. A lateral anastomosis after resection was done, and on recovery the patient was advised to change his occupation. In a number of instances such as the preceding, trauma might be regarded as a contributing cause, for either benign neoplasm or a Meckel's diverticulum might alone be responsible for an intussusception. This interpretation must obtain in Case 49, in which after a fall on the left side a subserous lipoma was found at the apex of an intussusception. In the three following cases, however, no cause was found either at operation or at autopsy, and the previous history of trauma assumes a correspondingly greater importance. In Case 25 wrestling had preceded an intussusception, which terminated fatally from peritonitis after the discharge of a necrotic intussusceptum from the bowel. A similar case, No. 37, may be cited, in which a slough composed of the transverse colon was discharged from the bowel after an obstruction of a week's duration, preceded by a history of lifting a heavy weight. In Case 193, an enteric intussusception, a history of playing football is mentioned. An analysis of the 300 cases cited in this paper gives 23 instances in which some form of trauma was associated with the intus-

susception, and a glance at Table I shows that, of all the different forms of trauma, that one in which there is some form of violent muscular exertion is by far the most frequent.

TABLE I

Trauma, not classified	2
Blow	2
Crush	1
Fall	3
Violent muscular movement, football (1), riding (2)	7
Lifting heavy weight	7
Puerperium	1
Typhoid	5
Dysentery	6
Tuberculosis	6
Simple inflammatory ulcers	3

Tumors of the intestine are a comparatively frequent cause of intussusception in adults, occurring rarely in infants and children. Of the 300 cases here cited there were 60 instances of benign tumor and 40 instances of the malignant type. Of the former class, the majority had their origin in the inner layers of the intestinal wall, usually by a constricted or forming by that means a more natural form of irri-
pedunculated base, and projected into the lumen,
tation than the less frequent growths which were sub-
serous and projected toward the peritoneal cavity. Histologically, polyp, lipoma, myoadenoma, fibroma, myxofibroma, myofibroma, myxoma, cyst of the ileocecal valve, and papilloma are all mentioned, the polyp being the most frequent and occasionally multiple. In four instances the benign tumor was associated with a Meckel's diverticulum: in Case 152, a fibrous polyp at its apex; in Case 151, a similar growth in its interior; in Case 163, a subserous lipoma at its apex;

and in Case 97, a plum-sized fibrous tumor near its base. In almost every instance the tumor occupied the apex of the invagination, but in Case 96 it was at its base, a situation in which the question of its being an exciting cause might well be open to argument.

The malignant growths include different varieties of carcinoma, sarcoma, myxosarcoma, melanotic epithelioma, and in Case 111 a sessile polyp in the sigmoid which had become malignant. The location of the growth may be studied in Table II. No part of the alimentary tract seems to be immune, but, as is the case with growths of the intestine independent of intussusception, benign varieties are more frequent in the small, while malignant growths more frequently invade the large, intestine. Moreover, attention may be directed to the fact that intussusceptions occurring in connection with benign growths in the large intestine are situated in either the sigmoid or rectum.

Ulceration of the intestine other than that associated with malignant growths is a well-recognized cause of intussusception in adults. Ulceration associated with typhoid fever, dysentery, tuberculosis, and simple ulcers, possibly of stercoraceous origin, preponderate. The writer has reported, in Vol. xxiv of the *Transactions of the American Surgical Society,* a case of enteric intussusception associated with the convalescent period of typhoid fever in a young girl of seven. A study of the 300 adult cases here reported shows 5 instances of intussusception due to typhoid ulceration, 6 instances of intussusception in connection with dysenteric ulcers, 5 instances of intussusception associated with tuberculosis, and at least 3 instances of intussusception associated with what are described as simple inflammatory ulcers. In intussusception due to tuberculosis, the lesion may be a tuberculous infiltration of the serosa or subserosa

of the intestine without ulceration of its mucous membrane.

TABLE II

	Benign	Malignant
Enteric, not stated	4	3
Duodenum	0	1
Upper jejunum	1	0
Lower jejunum	0	0
Not stated, jejunum	4	2
Upper ileum	0	1
Lower ileum	5	1
Not stated, ileum	5	2
Total	19	10
Ileocecal valve	13	9
Total	13	9
Colon, not stated	5	2
Ascending colon	0	1
Transverse colon	0	0
Descending colon	2	0
Sigmoid	6	5
Rectum	1	1
Cecum	3	9
Total	17	18

Meckel's diverticulum is associated with intussusception in both adults and children. In 29 cases of this particular variety, 15 occurred in patients under 10, five between 10 and 20, four between 20 and 30 and four in patients between 30 and 49, and in one the age is not given. In the different varieties of acute obstruction directly due to this appendage without intussusception, a similar age relationship obtains, and cases occur even as late as in the sixth decade. The exact nature of the irritation which brings about the initial inversion of a diverticulum in intussuscep-

tion, is rather difficult of explanation. Reference has already been made to the occasional presence of a polyp or other benign growth in this connection. In the majority of cases, however, in irritation or inflammation from inadequate drainage of its secretion, lies the probable explanation of this unusual lesion.

Foreign bodies within the alimentary canal, impacted or free, rarely cause intussusception. In Case 33, however, a rusty darning-needle, and in Case 180 a date-stone, may have been contributing factors.

Some writers believe that intussusception may be due to the irritation of intestinal parasites such as ascarides or lumbricoides. Whether the presence of such parasites is a mere coincidence or an actual contributing cause, is largely conjectural.

Attention is directed to a considerable number of acute, subacute, or chronic cases of intussusception in which no cause is mentioned. That cases occur without discoverable cause must be admitted. On the other hand, the lack of mention of a cause is not infrequently due to omissions in the published report of the case.

The uniformity of the clinical picture of intussusception in infants and young children has been emphasized by Clubbe, Codman, and many other writers. In this group of cases the symptoms, both local and constitutional, are so characteristic that a correct diagnosis should be promptly made. On the other hand, that the clinical picture of intussusception in adults varies widely is well illustrated in the histories of the following cases, in both of which the cause was a polyp attached to the intestinal wall by a constricted base. As a matter of fact, the great contrast presented by these histories suggested to the writer the desirability of investigating the subject of acute intussusception of adults as a whole, with the object of arranging if possible the different groups into which,

in accordance with their varied courses, the cases might justifiably be divided.

Case I.—Male, aged forty Referred by Dr. Fer-

Ever since childhood and until a short time ago the patient has suffered from occasional abdominal cramps; three or four months ago he was seized by slight cramp-like pains in the left lower quadrant, occurring either before or after eating. They were of from 10 to 15 minutes in duration and were relieved by simple measures. Twenty-nine hours ago, he was seized by a sudden, severe, cramp-like pain in the left lower quadrant, which did not radiate. Shortly after the onset the bowels moved spontaneously, the movement consisting of blackish material. At the same time vomiting occurred and has been repeated at frequent intervals up to the time of admission into the hospital. About eight hours after the invasion, patient felt a hard lump in the right lower quadrant, which shortly afterward moved to the left side. The tumor and its change in position was confirmed by the family physician. In addition there was a history of the frequent passage of mucus and blood from the rectum.

Physical examination, on admission to the hospital, showed that the abdomen moved with respiration. There was a localized distention in the midumbilical region extending more to the right than to the left side. On palpation, two loops of elastic distended intestine separated by a groove, could be distinctly felt in the distended area. These loops were movable from side to side and tympanitic on percussion. The overlying abdominal wall was moderately rigid. There was slight dulness in the flanks half way up to the navel. There was no evidence of increased or focal peristalsis. Apart from the presence of blood and mucus in an enema, examination of the rectum was negative. The temperature was 100°, the pulse 92,

and respiration 22. The general condition appeared excellent.

Under anesthesia, an incision was made along the outer border of the right rectus muscle, and on opening the peritoneal cavity a small amount of serous fluid issued from the wound. The distended loops above mentioned proved to be those of an enteric intussusception, which was about 12 inches long and curved like an enormous sausage upon its mesenteric axis. It was completely irreducible. A resection of what proved to be about four feet of small intestine was then carried out, and the divided ends united by circular suture. The abdomen was closed without drainage. The patient reacted well from the operation and recovered without complication. An examination of the intussusception showed a polyp about the size of an English walnut at the apex of the invagination. The intussuscipiens was in a condition of incipient gangrene and the mesenteric veins were thrombosed.

Case II.—Female, aged sixty-seven. Referred by Dr. Niesley.

Patient has always enjoyed excellent health until four months ago, when she suffered from several attacks of epigastric pain and vomiting. These quickly subsided, and patient was quite well until several weeks before her admission into the Nassau Hospital, when the epigastric pain recurred and, on abdominal palpation, a mass was found occupying the position of the transverse colon. This mass was doughy, insensitive, and, owing to a long pre-existing constipation, was supposed to be due to a possible fecal impaction. A high enema was given and the mass almost totally disappeared, only a small portion remaining in the right lower quadrant. At the same time the enema brought away only a small amount of ordinary fecal material. From time to time recurrence

of the tumor took place, always without pain and without discomfort to the patient, only to disappear with an enema or after abdominal massage. At no time was there even subacute obstruction, and operation was delayed merely with the idea of improving the patient's general condition. Rectal examination was negative.

Under ether the peritoneal cavity was opened by a right pararectal incision and the intussusception exposed. It was of the ileocolic variety and extended as far as the splenic flexure. Disinvagination was quickly accomplished until the cecum was reached, and with a little pressure something was felt to slip through the ileocecal valve and for a distance of six inches above it. From this point the intussusception about six inches in length, was totally irreducible and was resected, followed by end-to-end suture. After the removal of the appendix, which was edematous and thickened, the abdomen was closed without drainage, the patient making an excellent recovery. Examination of the specimen removed showed a polyp the size of a lemon and attached by a constricted base to the apex of the invagination.

Through the courtesy of the gentlemen mentioned below I am permitted to present notes of five more hitherto unpublished cases.

Cases of Dr. John Gibbon, Philadelphia, Pa.

Case III.—A male, aged fifty-eight, was operated upon in the Presbyterian Hospital July 27, 1900, after a history indicating intestinal obstruction. He was in bad condition when operated upon. Eight to ten inches of the ileum had passed into the cecum and could be withdrawn. Three feet eleven inches of ileum were resected to get above gangrenous portion. The end of small bowel and cecum opening were sutured in the wound. Drainage. Death on the same day.

Case IV.—A male, aged nineteen, previously in good health, his bowels having moved twice that morning, was seized by sudden severe abdominal pain and vomiting. The pain gradually became worse and several hours later he consulted Dr. Graham, who gave him a hypodermic and could distinguish a mass in the right lower quadrant when the boy became quiet. Seen by Dr. Gibbon shortly afterward, at Dr. Graham's office, patient was pale and without pain. Temperature was subnormal, abdomen was scaphoid and a little rigid. In the right lower quadrant was a distinct, oblong, slightly tender and movable mass. One hour later temperature was subnormal and mass was thought to have changed somewhat. Operation was refused until next day. Enemata had been ineffectual, and vomiting had occurred several times. There had been no tenesmus or rectal bleeding.

Operation twenty-four hours after onset. Under ether anesthesia examination showed that mass had moved further up on right side. Through incision, through right rectus sheath, presented a large intussusception. Reduction was impossible. Incision made through ant. long. band of colon, which was filled with bloody exudate and 18 inches of ileum. It was impossible to draw ileum further into lumen of large bowel for purposes of resection. The contained ileum was tied off inside colon near ileocolic junction, and two rows of sutures applied outside to prevent leakage. Lateral anastomosis between ileum and colon was made, utilizing the slit in the colon. Catgut was used for all inner rows of sutures and linen on the outside. Bowel was washed with saline and iodoform drainage was inserted

Post-operation, a small quantity of flatus and bloody fecal matter was passed. There was a short post-operative rise of temperature. Feeding was be-

gun immediately and convalescence was uninterrupted.

Cases of Dr. W. J. Mayo, Rochester, Minn.

Case V.—In an adult having colicky symptoms for several months. There was an adenofibroma in the ileum.

Case VI.—Age fourteen, with no previous symptoms. There was a myoma 6 inches above ileum into cecum and ascending colon. Both cases recovered after resection.

Case of Dr. James E. Moore, Minneapolis, Minn.

Case VII.—Age twenty-five, had repeated attacks of colic through several years, diagnosed appendicitis. Present attack 24 hours. Variety, ileum into colon about 18 inches. Condition, dark color of both outer and inner coats, but no gangrene. Operation, reduction and resection of a Meckel's diverticulum. Result, prompt cure. Patient had one attack of colic after the operation.

Returning to the above-mentioned classification, we find that Table A, including cases of intussusception associated with benign tumors, is the largest, comprising one-fifth of all cases here tabulated, and may be divided into four groups as follows:

(*a*) Those in which, as in the first case reported, the onset of the obstruction is acute and without warning, the patient having previously enjoyed perfect health.

(*b*) Those in which the acute onset is preceded by a history of previous attacks of obstruction relieved without operation, or a history of chronic constipation, indigestion, or of both extending over many years, or a history of intermittent attacks of colic, with or without vomiting, concurrent with constipation and separated by intervals of complete freedom from all abdominal discomfort.

(*c*) An infrequent group in which the intussusception is essentially chronic, without marked pain, with no vomiting, and with only moderate constipation easily relieved by enema. The second patient herewith reported belongs to this group.

(*d*) An occasional group comprises those patients who give a history simulating some other abdominal lesion, in whom the intussusception is discovered only in the course of an exploratory laparotomy. Thus, in Case 80, symptoms of three years' duration pointed either to cholelithiasis or peptic ulcer, yet on operation an enteric intussusception with a polyp at its apex was discovered and removed.

Of the patients suffering from this form of intussusception, the youngest was fifteen with the exception of Case 52, a male of four reported by Brunner, in which the cause of the intussusception is given, "as an accessory pancreas tumor in the blind end of a diverticulum forming a pedunculated tumor in the lower ileum." The oldest occurred in a patient of eighty-four, and it is worthy of note that in four patients over seventy three polyps presented in the rectum and the fourth in the descending colon.

The fragmentary way in which a number of these cases are reported renders useless the computation of any percentages of individual symptoms, such as abdominal tumor, the frequency of rectal discharges of blood and mucus, the absence of constipation, the frequency of vomiting, etc. In 22 cases the presence of an abdominal tumor is mentioned; in one no tumor could be detected. In the remainder no statement regarding the presence or absence of a tumor is made. In 15 cases note is made of the discharge of either blood or mucus; of the remainder only in one is it mentioned that rectal examination was negative. It is worthy of note in this connection that in at least two cases, Nos. 52 and 67, the discharge of blood

from the rectum was sufficiently abundant to constitute actual hemorrhage. Attention should also be directed to the occasional mention of rectal tenesmus. This symptom is evidently most frequently associated with benign growths below the level of the splenic flexure.

Table B includes 40 cases of intussusception with malignant tumor, which may be conveniently divided into the following groups:

(*a*) Those in which the onset is acute, occurring without warning in patients who have always enjoyed excellent health. Such cases are uncommon. Case 141, an enteric intussusception due to multiple sarcoma with mesenteric glandular involvement, may be cited as an example. In Case 119, symptoms of acute appendicitis were followed after ten days by those of subacute obstruction in what proved to be an intussusception associated with a sarcoma of the ileum.

(*b*) In this group the development of the intussusception is preceded by a history of a primary growth, usually sarcoma, in some distant part of the body.

(*c*) By far the most frequent are cases belonging to this group, in which the symptoms pointing to an intussusception are preceded by those due to malignant stricture. In cases of this character the obstruction due to the intussusception is essentially chronic, and in its later stages cannot easily be distinguished from the terminal obstruction so frequently seen in malignant stricture of the large intestine. The alternating constipation and diarrhea, the blood and at times pus in the stool, the presence of focal distention and of visible peristalsis, together with the recurrent attacks of subacute obstruction, relieved by enemata, are all classic symptoms of that condition. It is only by the discovery of the characteristic tumor that the diagnosis of intussusception can be made, and even

then the diagnosis may be erroneous, since the tumor may be due to a temporary fecal impaction on the proximal side of the stricture.

Table C comprises those cases of acute intussusception either without discoverable cause or at least without the mention of any cause in the history. They may be conveniently divided into two groups:

(*a*) Cases with acute onset, without warning, in patients previously healthy.

(*b*) Cases with acute onset, preceded by a history, extending over weeks or months, of some abdominal disturbance. Of this group Case 213 may be cited, in which the patient suffered from intermittent attacks of sharp colicky pain for six months prior to operation for an irreducible enteric intussusception, three feet below the pylorus. The patient, a woman of fifty, died shortly after the resection of the invagination and the suturing of both ends of the divided intestine into the abdominal wound. Case 218 is also of interest. The patient, a male of twenty-two, gave a history of three attacks of acute cramps of short duration, with the formation of a tumor occurring within the three weeks prior to operation. On each day there was diarrhea, and at operation an ileocecal invagination extending to the splenic flexure was found. The patient made an excellent recovery after resection followed by end-to-end suture.

Table D comprises those cases of acute intussusception, exclusive of tumors, in which some other specific cause was found. They may conveniently be divided into two groups:

(*a*) Those with an acute onset preceded only by the symptoms of the actual exciting cause.

(*b*) Those in which the acute onset is preceded by a history of some abdominal disturbance. Of this type Case 190, in which the patient suffered from two attacks of abdominal pain 16 years and 10 weeks prior

to the invasion of the intussusception, seems to be the only example. At operation an intussusception was found with a well-defined ulcer at its apex. On the other hand, Group *a* includes cases following various kinds of trauma (which have already been discussed under the etiology), cases occurring in connection with typhoid fever (one on the twenty-fifth, two on the twenty-sixth, one on the fortieth day, and one during convalescence), and a case associated with colitis.

Table E comprises those cases of subacute and chronic intussusception for which no cause is mentioned in the history. In nearly all the cases of this group of which the history is not fragmentary, there is a story of intermittent attacks of colic, with the appearance of a tumor or of a distended loop of intestine, which in many instances are noted by the patients themselves.

Table F comprises cases of subacute or chronic intussusception, in the histories of which a distinct cause is mentioned, and may conveniently be divided into two groups:

(*a*) Those in which the actual cause is recognized prior to the operation, including cases of chronic intussusception associated with dysentery or persistent typhoid or tubercular ulceration. In this group the symptoms and physical signs of intussusception modify those which are due to the pre-existing lesion.

(*b*) Those in which the actual cause is revealed only by the operation or autopsy. This group includes cases of chronic intussusception associated with subserous tubercular infiltration of the intestine, as well as those due to chronic ulceration of the cecum or colon which is probably of stercoraceous origin. In this group the history does not differ materially from the history of a case of chronic or subacute intussus-

ception in which the actual cause can never be ascertained.

Table G includes all cases of intussusception, irrespective of the age of the patient, due to Meckel's diverticulum. These may conveniently be divided into two groups:

(*a*) Those in which the invasion is acute without previous history of abdominal trouble.

(*b*) Those in which the invasion of the terminal obstruction is preceded either by one or more attacks of obstruction which have subsided spontaneously, or by some other minor abdominal or digestive disturbance. Thus in Case 170, in a woman aged thirty-nine, there was a history of attacks of sub-acute obstruction occurring several times in the course of each year for a period of 12 years. In Case 162, on the other hand, there was merely a history of poor digestion with occasional colic, and in Case 145 a history of sudden unexplained hemorrhage from the bowel one month before the symptoms of acute obstruction appeared.

Considerable variation is also observed in the individual symptoms of the acute terminal obstruction in intussusception due to Meckel's diverticulum. While complete constipation is the rule, either the passage of one or more normal stools or actual diarrhea is not an infrequent exception. Blood and mucous discharges from the bowel are mentioned in six cases, once with tenesmus. In four instances it is stated that neither blood nor mucus was discharged from the rectum, and in the remaining thirteen cases no mention is made of this symptom. The presence of a tumor was almost always observed.

The clinical course is usually exceptionally severe; in fact, analysis of the cases of this lesion shows that the inverted Meckel's diverticulum is, with but two exceptions, irreducible, and that gangrene of the in-

tussusception occurs so promptly that early operative interference is urgently demanded.

In all the different forms of intussusception, both acute and chronic, and irrespective of the actual contributing or exciting cause, the presence of an abdominal tumor and its variation in size, position, and consistency, either during or independent of the attacks of colicky pain, are especially characteristic. The clinical picture of a tumor quickly appearing or increasing in size during the attacks of colic, and disappearing or decreasing in size with their cessation, renders the diagnosis of intussusception certain. The writer has referred in a previous paper to the fact that the overlapping of the spleen or liver may conceal an intussusception at the hepatic or splenic flexures of the colon, and also to the fact that an intussusception gravitating or moving into the depths of the pelvis may be especially difficult to palpate. The possibility of such contingencies emphasizes the importance of making a bimanual examination in either ileocostal space, as well as through the rectum, by means of which, either with or without the assistance of an anesthetic the tumor mass may usually be detected. The writer wishes also to emphasize the increase in the consistency of the mass formed by the intussusception, either with the advent of a cramp or even as the result of the mechanical stimulation in the course of routine palpation. This change in consistency, although it does not always occur, differentiates the tumor of an intussusception from either a neoplasm or a fecal impaction.

The presence of an abdominal tumor, together with the similarity of the symptoms of the two conditions, accounts for the occasional confusion of intussusception with appendicitis. A correct diagnosis is usually possible by noting that the tumor associated with appendicitis is almost invariably fixed and enjoys little,

if any, respiratory movement. Moreover, the associated muscular rigidity is of great importance. In appendicitis it is almost always most marked in the lower right quadrant, while in intussusception the symptom, if present, is generally more marked to one side or the other of the umbilicus, while the intervening abdomen between this area and either inguinal region is either less rigid or entirely free from any rigidity whatever. This proved to be the fact in the first case reported in this paper. Both iliac and both hypochondriac regions were free from rigidity, and, although the enteric intussusception was of 28 hours' duration, the abdominal wall over the large tumor was not sufficiently rigid to interfere with its satisfactory palpation.

The course of acute intussusception in adults is more prolonged than in infants or children. The latter quickly succumb to the intestinal toxemia, the result of obstruction, before the advent of peritonitis. In adults, on the other hand, the course may be so protracted that, the intussuscipiens remaining viable, the obstruction may be relieved by the spontaneous discharge of the necrotic intussusceptum through the rectum. Of the 43 cases of this character included in Table H only three occurred in patients less than four years old; the remainder include cases of intussusception associated with Meckel's diverticulum, with benign tumors, and many others in which the actual cause could not be recognized in the discharge slough.

It is self-evident that, owing to the primary risk, the possibility of relief through the discharge of the necrotic intussusceptum should not encourage conservative measures in the treatment of this condition, and it is emphasized by Raven, as well as shown by a study of the end-results in the additional cases reported in Table H that, although temporary relief is usually afforded by nature's method, yet within eight-

een months and usually much earlier, secondary obstruction develops from cicatricial contraction at the point of the original invagination and is rapidly fatal. Such an unfortunate termination appears so common that, after the subsidence of the abdominal symptoms associated with the discharge of the slough in these neglected cases, the writer suggests the advisability of providing against the contingency of subsequent obstruction by establishing a lateral anastomosis between the intestinal canal on either side of the site of the invagination.

The principles which govern the treatment of intussusception in adults do not differ essentially from those in children. The fallacy of palliative measures is just as pronounced in the one as the other, although, owing to their greater resistance, the risk incurred by delay in adults is not so great as in children. It must be admitted that in both a temporary, if not a permanent, reduction is sometimes effected by rectal injections of either air or water. On the other hand, at the expense of possible repetition, it must be emphasized that experience has amply demonstrated that the disappearance of the tumor as a result of either of these measures of treatment may mean but partial disinvagination and that, after a brief respite, the symptoms of acute obstruction may recur with renewed virulence, the tumor being again palpaple through the abdominal wall or rectum, and the general condition of the patient, especially in an infant, less capable of overcoming the shock of inevitable operation.

The earlier the operation in infants the easier and the more quickly accomplished is the disinvagination, and if this takes place within the first twelve or even twenty-four hours after the onset of obstruction, the total operative time should not exceed from ten to fifteen minutes. Under such favorable conditions the

chances of recovery, even in a young infant, are excellent.

With the exposure of the intussusception, disinvagination is to be accomplished by a combination of expression and traction. In the paper already referred to, the writer has called attention to the danger of rupture of the intestine if dependence is placed upon either of these measures alone. Usually in the first stages of reduction, expression only is necessary. In the last part of reduction, however, in which the greatest difficulty is experienced, a combination of both measures is indicated. With the completion of reduction when that has proved feasible, the cause of the intussusception is to be removed if possible; thus a Meckel's diverticulum or an appendix may be resected while a benign tumor may be removed through a linear incision of the intestinal wall or even, as is always the case with a malignant growth, by complete resection. The cause having been removed, a recurrence of the intussusception is best prevented by anchoring the affected loop to the lateral parietal peritoneum. This method is more reliable and can be more quickly accomplished than the reefing of the mesentery, than the more radical measure of resection of the affected loop, or the ingenious reefing of the large intestine suggested by Passagi (Case 292), in which two parallel rows of Lembert sutures are placed on either side of its anterior longitudinal band (endoplication of the cecum).

TABLE III

	No.	Cured	Died	Not Stated
Resection	84	41	34	9
Splitting sheath and resecting intussusceptum from within	9	7	2	
Partial reduction followed by resection	18	11	5	2

Reduction complete, resection of tumor or Meckel's diverticulum	17	6	7	4
Reduction complete, resection for stricture or to prevent recurrence	2	1	1	
Reduction	37	23	7	7
Bimanual reduction (one hand in bowel)	2	2		
Attempted reduction, tear, resection	10	3	7	
Ileocolostomy, entero-enterostomy	13	5	6	2
Enterotomy	3	1		2
Enterostomy	4	1	3	
Resection and removal rectally	5	3		2
Incision of constricting band, reduction	3	2	1	
Artificial anus	12	1	8	3
	217	107	81	29

The treatment of irreducible or gangrenous intussusception depends upon the condition of the intussuscipiens and the intussusceptum. If both are necrotic, resection is imperative. In infants of less than a year, such a drastic measure is usually fatal but is without alternative. The subsequent continuity of the intestine must be established in the quickest possible infant's condition. In adults, on the other hand, a way, for a temporary enterostomy rarely improves the temporary enterostomy is frequently of great advantage, if not situated too near the pylorus, the subsequent anastomosis being done after the symptoms of the acute obstruction have subsided.

If the intussuscipiens is viable, the removal of the intussusceptum has been accomplished with considerable success through a linear incision in its wall. Ref-

erence to Table III shows nine such operations with seven recoveries and two deaths. The relatively low mortality may be partially accounted for by the fact that all nine cases were reported during the past ten years, and that with two exceptions the intussusception was either of the subacute or chronic variety.

The viability of the intussuscipiens also permits of intussusception being treated by enterostomy or by ileocolostomy. If the intussusceptum is necrotic, the slough is eventually discharged through the bowel. If, as is the case with many subacute or chronic intussusceptions, the intussusceptum is viable, an ileocolostomy relieves the obstruction, and by deflection of the fecal current exerts a beneficial effect upon any benign ulceration that may have been responsible for the intussusception. In such cases secondary reaction should follow as soon as the patient's condition permits. Reference to Table III shows 13 operations of this character with 5 recoveries and 6 deaths. In the two remaining cases the result is not mentioned.

Of greater value than either of the preceding methods is the treatment of irreducible intussusception in adults by resection. This is the method of choice in all suitable cases in which attempted reduction, carried on for a few minutes, is unsuccessful. How often too energetic or too persistent attempts at reduction result in tearing the intestine need not be stated, but it is quite evident that the results of resection are most satisfactory in the absence of any such additional source of contamination, and that any leakage subsequent to anastomosis is less likely to occur if the intestine is divided at a point where it is free from inflammatory changes. Such a resection must invariably be preceded by as much disingavination as can easily and quickly be accomplished. Exceptionally, as in the first case reported by the writer, the intussusception is totally irreducible. Usually,

however, reduction is possible to such an extent that subsequent resection is limited to a segment of intestine not exceeding 6 to 18 inches in length. After the removal of the affected segment, the risk of intestinal toxemia should be diminished by evacuating the contents of the intestine above the point of suggested anastomosis. Frequently, however, if the operation is done sufficiently early, the upper intestine is empty and this step of the operation may be omitted. Reference to Table III shows 84 cases treated by resection, with 41 recoveries, 34 deaths, and 9 cases in which the result is not stated. It must be noted, however, that the majority of fatal cases were reported in the literature at a time when the technic of resection had not been perfected and when the operation itself was frequently delayed until peritonitis had developed.

The discussion of the treatment of intussusception in adults is not complete without referring to a series of 19 cases mentioned in Table III which were treated by the method of complete reduction followed by resection with 7 recoveries, 8 deaths, and 4 cases in which the result is not stated. This method seems to have been adopted chiefly in cases of intussusception associated with tumors. In this group of cases partial disinvagination is usually possible until the segment containing the tumor is reached. At this stage, the removal of the growth by enterotomy is sometimes possible, but in all malignant tumors as well as in those benign tumors in which the wall of the intestine is extensively involved, resection is imperative. Resection after reduction in other varieties of intussusception than those associated with neoplasms is contraindicated, for it means, first, the unnecessary prolonging of the operative time and, second, in the event of a gangrenous intussusceptum, the exposure of the

patient to unnecessary risk of peritoneal contamination.

Table III also mentions five cases in which the growth was removed through the rectum, with three recoveries and two cases in which the result is not stated. Although the small number of cases admits of no definite conclusion, the satisfactory results here reported would indicate the application of this method of treatment to all forms of benign neoplasm associated with intussusception in the lower part of the intestinal canal where the tumor presents in the rectum. In some cases of this group the removal of the growth must be followed by immediate laparotomy to establish the continuity of the colon, as well as to prevent leakage into the peritoneal cavity.

Finally, reference to Table III shows four cases of intussusception treated by enterostomy with three deaths and one recovery, and 12 cases in which an artificial anus was established, with one recovery, eight deaths, and three cases in which the result is not stated. Either measure is purely palliative, and it is scarcely necessary to call attention to the fact that the obstruction rather than the operation was the actual cause of the associated high mortality. That relief is frequently afforded by this method of treatment in all forms of both acute and chronic obstruction in which there is no impairment of circulation is well established. On the other hand, it is equally true that no benefit can be expected if gangrene is threatened or has actually taken place.

In the cases given below, a tabulation of the following factors was made: sex; age; prior history; onset, whether acute or chronic, together with its symptoms; the condition of the bowels; objective signs in rectum: blood, mucus, etc.; abdominal signs: tumor, distention, rigidity, etc.; the operation if any; the var-

iety of intussusception; the result; and any remarks on pathology, end-results; etc.

Abstracts of Reported Cases of Intussusception in Adults

Table A

Due to Traction of Benign Tumors

Case 44 (Bryant, *Brit. Med. Jour.*, 1894, i, p. 353).—Female, age 84. Operation: Intussusception filling rectum with papilloma attached to orifice. Growth drawn down; ligated. Recovered.

Case 45 (*Ibid.*).—Female, age 50. Similar to Case 44.

Case 46 (Lockwood, *Path. Rep.*, London, 1892).—Female, age 30. Operation: Irreducible invagination; resection; suture end-to-end. Variety: Enteric, 5 inches long. Pathological remarks: Polyp pedunculated 2½ feet from cecum.

Case 47 (Steiner, *Cent. f. Ch.*, 1896, p. 310).—Female, age 49. Prior history: Frequent attacks of obstruction. Onset: Complete obstruction. Operation: Enterotomy; removal of polyp size of plum. Position: Colon, descending. Recovered. Pathological remarks: Myxoma.

Case 48 (Greig Smith, *Lancet*, 1896, i, p. 31).—Female, age 31. Prior history: Complete obstruction two years ago with mass in right iliac fossa. Onset: Lately intermittent frequent pain, with constipation. Operation: Partial reduction; resection of remainder, after removal of tumor size of hen's egg; end-to-end with Murphy button. Variety: Ileac into colon. Recovered. Pathological remarks: Fibromyxoma.

Case 49 (Marchand, *Berl. klin. Woch.*, 1896, No. 6).—Male, age 23. Prior history of trauma: Fall on left side, next day dancing. Onset: Acute, pain and vomiting, symptoms of obstruction. Operation: Fifth day; enterostomy for supposed obstruction. Ileocolic into descending colon. Died. Pathological remarks: Subserous lipoma of cecum.

Case 50 (Sprengel, *Archives Surg.*, Bd. 61, p. 1032).—Female, age 15. Prior history: Periodic attacks of pain with vomiting for eleven years. Onset: Painful period for month. Bowels: Stools always present. Thick transverse tumor above navel. Operation: Disinvagination; resection of 10 cm. large and 6 cm. small intestine; end-to-end with Murphy button. Variety: Ileocecal. Recovered. Pathological remarks: Cyst of valvula Bauhini.

Case 51 (Brunner, C., *Beitrage*, xxv, p. 344).—Male, age 51.

Onset: Six days pain. Bowels: No stool, no flatus. Rectal examination: Rectal tenesmus; tumor within sphincter. Operation: Sphincter dilated and divided posteriorly; tumor removed with invagination. Pathological remarks: Submucous lipoma.

Case 52 (*Ibid.*).—Male, age 4. Onset: Pain and vomiting three days. Bowels: One normal stool, then constipation. Rectal examination: Sharp hemorrhage. Operation: Resection with side implantation. Variety: Ileocecal. Pathological remarks: Accessory pancreas in blind end of diverticulum had formed pendunculated tumor in lower ileum.

Case 53 (Hiller, *Beitrage,* xxiv, p. 509).—Male, age 51. Onset: Occasional pain and vomiting. Bowels: Little stool. Rectal examination: tenesmus; otherwise negative. Distention: Moderate. Operation: Reduction, tear in process; resection, end-to-end by suture. Ileac invagination. Died. Pathological remarks: Submucous lipoma.

Case 54 (Studsgaard, *Nord. Med. Arkiv.,* 1894).—Female, age 42. Operation: Irreducible; resection. Variety; Jejunal. Death in five days from peritonitis. Pathological remarks: Polyp, lipoma.

Case 55 (Castelain, *Gaz. Hebd.,* 1870, No. 20).—Male, age 43. Prior history: Habitual constipation. Onset: Loss of appetite, nausea. Bowels: Constipation. Rectal examination: Blood and mucus; tenesmus. (Case also made discharge of slough.) Fourth week, discharged large tumor, with thin pedicle. Recovered. Pathological remarks: Lipoma.

Case 56 (Vois, *Norsk. Mag, fur Lageviderl,* 1881).—Operation: Invagination of lipoma into rectum; resection; reducton of intussusception by water injection.

Case 57 (Brohl-Tuffier, see Hiller).—Female, age 43. Prior history: Nine months constipation and pain. Tumor felt per rectum. Operation: Irreducible; artificial anus. Variety: Sigmoid. Died. Pathological remarks: Submucous pedunculated polyp in lower sigmoid.

Case 58 (Clos, *These,* Paris, 1883; see Hiller).—Female, age 45. Onset: Acute obstruction. Operation: Artificial anus. Died. Pathological remarks: Pedunculated lipoma in invaginated sigmoid.

Case 59 (Brohl, *Dissert. Würz.,* 1886).—Female, age 40. Prior history: Fifteen years abdominal pain. Onset: Past year sense of something coming down. Rectal examination:

Descent of invaginated lipoma in rectum. Pathological remarks: Lipoma.

Case 60 (Treves, Leipzig, 1888).—Female, age 83. Prior history: One year indigestion, colicky pain. Bowels: Diarrhea and constipation. Finally discharge of lipomatous polyp. Pathological remarks: Lipoma.

Case 61 (Link, *Wien. k. Woch.,* 1890, No. 13).—Male, age 45. Prior history: For five years attacks of obstruction. Tumor: Elastic, soft tumor size of man's fist in left hypochondrium for one year. Operation: Tumor evacuated with sudden gush of blood through rectum. Recovered. Pathological remarks: Tumor, pedunculated.

Case 62 (Michaux, *Bull. Soc. Chir.,* 1900, p. 734).—Female, age 23. Onset: Sudden pain and vomiting. No distention; tenderness. Operation: Fifth day; invaginated upper jejunum; irreducible; jejunum opened; resection of tumor and intestine. Died. Pathological remarks: Polyp "adenoma" was cause of irreducibility.

Case 63 (*Ibid.*).—Female, age 56. Onset: Five days' obstruction. Bowels; No stools. Mass in left lower quadrant. Distention; visible coils. Operation: Irreducible; artificial anus after incision of tumor and discovery of polyp. Variety: Descending colon into sigmoid. Died. Pathological remarks: Resection of polyp.

Case 64 (Pitts, *Brit. Med. Jour.,* 1901, ii, 574).—Male, age 32. Onset: Acute, one day. Operation: Reduction; removal of growth; subsequent fecal fistula. Variety: Enteric. Died. Pathological remarks: Resection of gangrenous bowel; papilloma.

Case 65 (*Ibid.*).—Female, age 32. Prior history: Thirteen weeks' duration. No operation. Chronic ileocecal. Pathological remarks: Fibroid growth in cecum.

Case 66 (Maurice, *Lancet,* 1901, i, p. 248).—Female, age 23. Prior history: Anemic; vague abdominal pain, vomiting after eating. Onset: Sudden pain. Rigidity: General. Operation: Reduced; polyp removed; excision, circular suture. Variety: Jejunal. Died. Pathological remarks: Intussusception; segment 34 inches from pylorus gangrenous; 10 polypi between it and pylorus.

Case 67 (Jenly, *Wien. k. Woch.,* 1901, p. 1177).—Male, age 70. Onset: Four days' duration, pain. Bowels: Stool scant. Rectal examination: Hemorrhage, repeated. Prolapsing tumor, especially on coughing. Operation: Resection through anus.

Variety: Colonic. Recovered. Pathological remarks: Polyp.

Case 68 (Marchand, *L'Inde. Med.*, 1901, p. 86).—Male, age 27. Prior history: Habitual constipation. Onset: Symptoms of appendicitis. Variety: Ileum into ascending colon; ileum into ileum. Pathological remarks: Polypi in ileum.

Case 69 (Bishop, *Med. Chron.*, 1900-01, p. 350).—Male, age 43. Prior history: Lifting, followed by protrusion, seven months ago; occasional pain. Rectal examination: Constant mucus and blood; tenesmus; long tubular mass. Operation: Preliminary anastomosis followed by resection of intussusceptum, by Maunsell. Variety: Colonic. Recovered. Pathological remarks: Adenoma.

Case 70 (Ludloff, *Grenz. Gebiet.*, 1898, iii, p. 600).—Female, age 20. Prior history: Typhoid at 12; four years, occasional cramps. Onset: Chronic obstruction, especially loud splashing sounds. Bowels: Pain followed by diarrheal stools. Tumor: Size of fist over cecum. Distention: Vomiting and pain. Operation: Irreducible; resection, end-to-end by suture. Variety: Ileocecal. Recovered; four years after, well. Pathological remarks: Polyp size of bean in invagination; multiple polypi in cecum.

Case 71 (Von Eiselberg, *Arch. f. klin. Chir.*, Bd. 69).—Female, age 19. Prior history: Obstipation for years, especially last eight days; two days severe colic and vomiting. Rectal examination: Blood last twenty-four hours. Tumor: Below navel on right ride, long tumor, disappearing later. Distention: Slight. Operation: Tear in attempted reduction; resection; end-to-end suture. Variety: Ileac. Died. Pathological remarks: Polyp.

Case 72 (*Ibid.*).—Male, aged 54. Prior history: Six weeks standing; onset with obstruction, relieved, with colic still persisting. Transverse movable tumor to right of navel. Operation: Reduction; resection of affected segment; end-to-end suture. Variety: Ileocecal. Recovered. Pathological remarks: Numerous polypi; one month later patient died from intercurrent disease.

Case 73 (Ray, *Lancet*, 1905, i, 567).—Female, age 30. Prior history: Pain for past six months, chiefly at and after defecation, in left iliac and lumbar; forty-eight hours, severe pain and vomiting. Rectal examination: Protrusion of tumor with enema. Operation: Reduction; removal of growth through enterotomy. Variety: Sigmoid. Recovered. Pathological remarkes: Subserous lipoma.

Case 74 (Willard, *Tr. Chicago Path. Soc.,* 1907, 7, p. 174).—Male, age 30. Prior history: Two mild attacks of obstruction twelve and six months ago; one week ago, absolute constipation, increasing pain and tympanites, vomiting; cathartic only. Bowels: Constipation. Rectal examination: Negative. Distention: Great; visible peristalsis. Operation: Resection; end-to-end suture. Variety: Jejunal. Recovered.

Case 75 (Chassignac, *Bull. de la Soc. Anatomique,* 1859, 2 s, iv, p. 205).—Male, age 39. Onset: Three months; sudden pain. Bowels: Constipation. Operation: Artificial anus. Variety: Ileocolic. Died. Pathological remarks: Polyp at apex.

Case 76 (Hulke, *Lancet,* 1879, vi, 810).—Female, age 16. Prior history: Similar attack two years ago. Onset: Sudden pain and vomiting. Abdominal tumor. Operation: Artificial anus. Variety: Ileocecal. Died. Pathological remarks. Lipomatous polyp at apex.

Case 77 (Marchand, *Le Progrès Med.,* 1882, No. 11, p. 202).—Female, adult. Onset: Nine months recurrent. Bowels: Constipation becoming absolute. Rectal examination: Tumor 8 cm. from anus. Operation: Artificial anus. Variety: Sigmoidal. Died. Pathologcal remarks. Lipoma at apex.

Case 78 (Whipham, *Clin. Soc. Trans.,* 1891, xxiv, p. 95.—Female, age 29. Prior history: Many years umbilical pain, indigestion. Onset: Three weeks; pain. Bowels: Constipation. Rectal examination: Blood. Distention. Operation: Reduction of volvulus; jejunal intussusception. Died. Pathological remarks: Autopsy: Axial and jejunal looped volvulus; above this a thumb-sized polyp, about 5 ft. from pylorus.

Case 79 (Nothnagel, *Spezielle Path. and Chir.,* 17 p. 316).—Male, age 50. Prior history: Fourteen months ago similar attacks lasting four months; one to three days' duration. Onset: Sudden pain and vomiting. Bowels: Increased peristalsis. Tumor: Epigastric. Rigidity: Right lower quadrant. Operation: Resection. Variety: Ileocecal. Cured. Pathological remarks: Polyp at apex.

Case 80 (Fenger, *Hospitolsted,* 1904, No. 26).—Age 17. Prior history: Three years; diagnosis, peptic ulcer, gallstones; exploratory operation, negative. Onset: Symptoms of obstruction. Tumor: Intermittent, appearing after previous operation. Operation: Resection. Variety: Enteric. Cured. Pathological remarks: Polyp at apex.

Case 81 (Rydygier, *Deut. Zeit. f. Chir.,* 1895, xlii, 113).—Male, age 32. Onset: Three weeks. Operation: Descending invagination because of walnut-sized fibromyoma; resection;

artificial anus. Died. Pathological remarks: Perforative peritonitis.

Case 82 (*Ibid.*).—Male, age 22. Onset: Three years; acute, twenty days ago. Bowels: Constipation. Rectal examination: Bloody stools. Operation: Colic to anus; suture of perforation; artificial anus. Died. Pathological remarks: Polyp at apex.

Case 83 (Delore, *Rev. de Gyn. and Chir. Abdom.,* 1905, 9, 641).—Male, age 42. Onset: Sudden pain. Tumor. Operation: Reduction, resection. Variety: Ileocolic. Cured. Pathological remarks: Fibromyxoma at apex.

Case 84 (Hughes, *Lancet,* 1905, ii, 829).—Male, age 23. Prior history: Four years, typhoid; one year, four days of pain in right lower quadrant. Onset: Sudden, two days of pain and vomiting. Rectal examination: Blood. Tumor: In pelvis by rectal. Distention: Signs of peritonitis. Operation: Peritonitis. Variety: Ileac. Resection. Pathological remarks: Polyp at apex.

Case 85 (Andrews, *Annals of Surgery,* xliii, 473).—Male, young adult. Prior history of trauma: Jumped 5 ft. Onset: Immediately, sudden pain. Operation: Gangrenous ileocolic; resection. Died. Pathological remarks: Pedunculated fibropapilloma.

Case 86 (Royster, *N. Albany Med. Herald,* 1905, 24, 258-260).—Male, age 42. Prior history: Six months, occasional indigestion and vomiting. Onset: Four months, recurring attacks abdominal pain. Bowels: Constipation. Rectal examination: Mucus. Tumor: Sigmoid region. Distention. Operation: Reduction; excision of tumor. Variety: Ileac, looking as if tied in knot. Cured. Pathological remarks: Tumor pure fibroma.

Case 87 (Salzer, *Annals of Surgery,* 1907, xlv, 730-732).—Female, age 16. Onset: Sudden, four days of pain, vomited during examination. Tumor: Right of umbilicus, size of orange. Rigidity: Right rectus muscle. Operation: Ileocolic, reduced; excision of pedunculated tumor. Pathological remarks: Myoadenoma of ileum.

Case 88 (Lorenz, *Jahr. d. zw. Ch. klinik. Wies.,* 1906-07, 41-44).—Male, aged 58. Onset: Gradual; symptoms of chronic intestinal stenosis. Tumor: Sausage-shaped, transverse, alternately hard and soft; at left extremity hard, egg-shaped tumor. Operation: Ileocecal invagination; tumor on ileocecal valve; hard nodes in mesentery; resection of lower ileum,

cecum, ascending colon. Cured. Pathological remarks: Lipoma.

Case 89 (Shetton, *Brit. Med. Jour.*, 1908, i, 190).—Female, age 25. Onset: Acute pain and vomiting. Tumor: Indefinite; right inguinal region. Operation: Enteric, irreducible; resection. Pathological remarks: Sessile polyp at apex.

Case 90 (Leuret, *Bull. et N. Anat.*, 1907, v. 82, p. 652).—Female, age 45. Onset: Acute pain and vomiting. Bowels: No stool or gas passed for four days. Distention. Operation: Ileac, ½ metre above cecum; reduction; excision of tumor. Died. Pathological remarks: Sessile myxofibroma.

Case 91 (Haeberlin, *Cor. Bl. f. Schw. Aertz.*, 1908, 38, 211, 248).—Female, age 66. Prior history: Two months, diarrhea and emaciation. Onset: Ten days, pain and vomiting. Bowels: Partial occlusion. Distention. Operation: Enteric, with hard body at apex; attempt to reduce caused tear; resection. Cured. Pathological remarks: Fibroma; fecal fistula twelfth day.

Case 92 (*Ibid.*).—Female, age 58. Prior history: Gallstones. Onset: Sudden pain and vomiting. Bowels: Constipation. Rectal examination: Blood. Tumor: Firm, kidney-shaped, movable. Distention: Right side. Operation: Ileocecal; irreducible; enterostomy. Died. Pathological remarks: Autopsy: Pedunculated hard fibroma in lumen of intestine.

Case 93 (Delore, *Rev. de Chir.*, 1908, vol. 38, 39-67).—Female, age 36. Prior history: Four months, pain in right lower quadrant with tumor; constipation. Onset: Three days, acute. Bowels: Absolute constipation. Rectal examination: Blood. Tumor: Right lower quadrant. Distention. Operation: Ileocecal; irreducible; end-to-end suture. Died on seventh day. Pathological remarks: Pedunculated myoma at apex.

Case 94 (*Ibid.*).—Male, age 42. Onset: Five months, colic and vomiting. Bowels: Constipation. Rectal examination: Negative. Tumor: Negative. Distention: Negative. Operation: Ileocecal; incision of colon, through opening resection intussusceptum and tumor at apex. Cured. Pathological remarks: Fibromyoma.

Case 95.—Male, age 39. Onset: Eleven weeks, recurrent pain. Bowels: Tenesmus. Rectal examination: Blood and mucus. Tumor: Left hypochondrium. Operation: Resection. Pathological remarks: Benign, variety not stated.

Case 96 (Haasler, *V. Langenbeck Arch.*, 1902, Bd. 68, p.

817).—Male, age 26. Prior history: Acute abdominal pain; recurred in nine days; continuous vomiting (fecaloid). Onset: Acute pain, hiccough. Bowels: Constipation. Rectal examination: Mucus. Tumor: Left lower quadrant, movable. Operation: Resection; rupture; necrotic bowel. Died. Pathological remarks: Polyp at base of intussusception.

Case 97 (*Ibid.*).—Male, age 35. Prior history: One year, rumbling in abdomen, with occasional sudden onset of constipation, meteorism and pain about umbilicus. Onset: Seven weeks, severe pain; more frequent pain and vomiting (fecal). Bowels: Diarrhea. Rectal examination: Hard mass. Distention. Operation: Peritonitis, enteric; reduction; resection Meckel's diverticulum; artificial anus. Died. Pathological remarks: Autopsy showed Meckel's diverticulum 2.18 m. from ileocecal valve, invaginated; at its base a plum-sized fibrous tumor.

Case 98 (*Ibid.*).—Male, age 25. Onset: One week, sudden pain and vomiting. Bowels: Diarrhea. Rectal examination: Pus. Tumor: Left of umbilicus, moving to left. Operation: Colic; resection of mass size of three fists. Pathological remarks: Polyp (lipoma) at apex.

Case 99 (Herbung, *Arch. f. klin. Chir.*, 1902, vol. 68, xliii, p. 1009).—Female, age 52. Prior history: Eleven months, pain, bloody mucus, constipation. Onset: Eleven days, pain and vomiting. Bowels: Constipation absolute. Rectal examination: Rectal tumor. Operation: (1) Incision of rectum (posterior route), artificial anus; (2) resection of tumor. Cured. Pathological remarks: Variety not given.

Case 100 (Don, *Lancet*, 1909, i, 1107).—Female, age 44. Onset: Vomiting, chronic course. Rectal examination: Blood and mucus; prolapse of tumor with movement. Operation: Resection through anus, followed by reduction through laparotomy. Sigmoid. Recovered. Pathological remarks: Papilloma.

Case 101 (Riedel, *Deut. med. Woch.*, 1909, 35, 1654).—Male, age 15. Prior history: Periodic pain from seventh year; frequent vomiting; attacks in morning and of one hour's duration. Bowels: Normal. Tumor: In right abdomen, during cramps only. Operation: Partial reduction; resection of segment containing growth. Ileac. Recovered. Pathological remarks: Character not stated.

Case 102 (*Ibid.*).—Female, age 48. Onset: Acute; fecal vomiting in twelve hours. Rectal examination: Invagination felt. Tumor: Size of two fists, in left abdomen. Distention

marked. Operation: Artificial anus, followed by resection through rectum. Sigmoid. Recovered. Pathological remarks: Character not stated.

Case 102a (Mayo Bros., personal communication).—Adult. Onset: Several months, colic. Operation: Resection. Ileac. Recovered. Pathological remarks: Adenofibroma.

Case 102b (Mayo Bros., personal communication).—Age 14. Operation: Resection. Ileac into cecum and ascending colon. Recovered. Pathological remarks: Myoma.

Case 102c (McWilliams).—Female, age 45. Onset: Four weeks, attacks of abdominal pain at intervals. Bowels. Diarrhea. Rectal examination. Blood and mucus; tenesmus; rectal mass and tumor in addition on the apex. Tumor: In left lower quadrant. Operation: Attempted reduction; incision of bowel; resection. Sigmoid. Recovered. Pathological remarks; Papilloma, possibly malignant but not invading muscularis.

Table B

Associated with Malignant Tumors.

Case 103 (Decker, *Bull. de la Soc. med. de la Suisse Romande,* 1880, May, No. 5).—Female, age 58. Onset: Thirteen months, pain (two days ago) and vomiting (three days ago). Tumor: Right upper quadrant. Distention: Visible peristalsis. Operation: Ileocecal. Died. Pathological remarks: Autopsy, malignant tumor of cecum.

Case 104 (Czerny, *Arch. f. path. Anat. Virchow,* ci, 48, 1885).—Male, age 52. Onset: Two months, pain and vomiting. Bowels: Diarrhea. Tumor: Right upper quadrant. Operation: Ileocecal, reduction; resection of tumor. Cured. Pathological remarks: Malignant tumor at apex, sloughing muscle wall hypertrophied (microscopically).

Case 105 (Koenig, *Arch. f. klin. Chir.,* 1890, xl, 911).—Female, age 18. Prior history: One year ago, sarcoma of lower jaw. Onset: Sudden pain and vomiting. Bowels: Constipation. Tumor. Distention: Asymmetrical. Operation: Colic, ulcerating tumor at apex.

Case 106 (Koenig, *Ibid.*).—Prior history: Tuberculosis. Onset: Sudden pain. Rectal examination: Bloody stools; tumor palpated in rectum, level of internal sphincter. Operation: Rectal, sacral route; excision. Cured, three years. Pathological remarks: Carcinoma.

Case 107 (Rydygier, *Deut. Zeit. f. Chir.,* 1895-6, 42, 113).—

Male, age 47. Onset: Nine months. Operation: Carcinoma at apex. Entero-anastomosis. Died.

Case 108.—Age 40. Onset: Six months. Tumor. Operation. Ileocecal; resection. Cured. Pathological remarks: Adenocarcinoma.

Case 109 (Paetzold, *Deut. med. Woch.*, 1906, 32, 34).—Adult. Onset: Pain. Bowels: Diarrhea. Tumor. Variety: Ileocecal. Pathological remarks: Adenocarcinoma, ileocecal valve.

Case 110 (*Ibid.*).—Adult. Onset: Pain. Bowels: Diarrhea. Tumor. Variety: Ileocecal. Pathological remarks: Alveolar sarcoma, ileocecal valve.

Case 111 (Shetton, *Brit. Med. Jour.*, 1908, i, 190).—Male, age 50. Prior history: Six months, similar attack. Onset: Acute; absolute constipation. Mass in rectum. Reduced by rectal manipulation under ether. One week later rectal tenesmus. Blood and mucus. Ulcerated intussusception protruding from anus. Operation: Reduction and resection of colic variety. Pathological remarks: Malignant sessile polyp in sigmoid.

Case 112 (Haeberlin, *Corr. Bl. f. Schw. Aert.*, 1908, 38, 211-248).—Female, age 56. Prior history: Seventeen years ago, colicky pains; six months, loss of appetite and weight. Onset: Six months. Bowels: Diarrhea. Tumor: Area of transverse colon. Visible peristalsis. Operation: Cecal in ascending colon, reduced; resection of tumor. Pathological remarks: Gelatinous carcinoma.

Case 113 (Combs, *Wis. Med. Jour.*, 1907-8, vi, 251-255).—Male, age 68. Prior history: Four years, primary growth in left malar region. Onset: Latterly pain. Bowels: Constipation, alternating with fetid diarrhea. Rectal examination: Sense of tumor high in rectum. Distention: Slight. Operation: Enteric; reduction; resection of tumor. Cured. Pathological remarks: "Melanotic epithelioma."

Case 114 (*Ibid.*).—Female, adult. Onset: Three months, no vomiting. Bowels: Finally absolute constipation. Rectal examination: Apex of invagination felt in rectum with irregular mass in its centre. Operation: Sigmoid, reducible; resection of tumor. Cured. Pathological remarks: Malignant with glandular enlargement.

Case 115 (Coffey, *Annals of Surgery*, 1907, xlv, 39-42).—Male, age 50. Onset: Thirteen days, "condition extreme." Rectal examination: Apex protruded through anus. Oper-

ation: Anastomosis. Died. Pathological remarks: Carcinoma of sigmoid.

Case 116 (Riess, *Am. Jour. Med. Sc.*, 1907, n. s. 134, 841-849).—Male, age 40. Prior history: Sarcoma of iris removed nine months ago; melanosarcomatosis present. Onset: Sudden pain and vomiting. Bowels: Stools small. Tumor. Variety: Ileac, 1 foot long; marked involvement by sarcoma.

Case 117 (Mayo, *Annals of Surgery*, 1896, 733).—Female, age 36. Prior history: Two years, movements difficult and with pain; six months, vomiting. Onset: For few days obstruction pronounced. Bowels: Constipated, occasional blood. Tumor: Size of egg, can be brought into pelvis under anesthetic; continuing with soft tumor above. Rectal examination: Blood. Distention, tenderness. Operation: Reduced with some difficulty, especially apex; resection; end-to-end with Murphy button. Ileac, upper, 15 inches in length. Recovered. Pathological remarks: Adenoma, with carcinomatous degeneration.

Case 118 (McBurney, *Annals of Surgery*, i, 1896, p. 411.)—Female, age 40. Onset: Sharp pain, in almost daily attacks; no vomiting. Bowels: No constipation. Smooth tumor in left pelvis. Rectal examination: Normal. Distention frequent; tenderness. Operation: Reduction; excision; end-to-end with Murphy button. Enteric. Recovered. Pathological remarks: Myxosarcoma.

Case 119 (Meyer, *Annals of Surgery*, 1896, i, 443).—Female, age 46. Prior history: Symptoms of subacute appendix for ten days; sudden obstruction shortly after. Operation: Reduced; a second one at end of first also reduced; sessile tumor felt; resection; end-to-end with Murphy button. Ileac. Recovered. Pathological remarks: Fecal fistula for few days; sarcoma.

Case 120 (*Ibid.*).—Boy. Prior history: Chronic obstruction; loud gurgling. Visible peristalsis. Operation: Reduced; resection; end-to-end with Murphy button. Ascending and transverse colon. Recovered. Pathological remarks: Sarcoma, lower end of ascending colon; subsequent death.

Case 121 (Deichert, *Dissert. Gött.*, 1895).—Male, age 46. Prior history: No symptoms. Operation: Several enteric invaginations. Pathological remarks: Metastatic lymphosarcoma in stomach and intestine.

Case 122 (Marchand, *Berl. klin. Woch.*, 1896, No. 6).—Male, old. Prior history: Primary parotid sarcoma. Oper-

ation: Jejunal into cecum. Pathological remarks: Melanosarcoma.

Case 123 (Brunner, C., *Beitrag,* v 25, p. 344).—Male, age 56. Prior history: Digestion disturbed for years; one year ago, bloody diarrhea. Rectal examination: Tumor advances in straining. Operation: Sacral resection for invaginated carcinoma. Pathological remarks: In part colloid, in part cylindrical.

Case 124 (Fleiner, *Virchow, Arch.,* Bd. 101, p. 484).—Male, age 45. Prior history: Pain, irregular stool, and tumor for one year. Very movable tumor. Rectal examination: Fourteen days, blood. Operation: Partial reduction; resection; circular enterorrhaphy. Ileocecal. Died. Pathological remarks: Carcinoma of cecum and ascending colon.

Case 125 (Billroth, *Arch. Ch.,* 1888, Bd. 43)—Male, age 40. Prior history: Eight months, pain and vomiting. Tumor: Variable, hard tumor under umbilicus. Rectal examination: Blood, two months. Operation: Irreducible; torn in attempt; resection; circular suture. Cecal. Recovered. Pathological remarks: Carcinoma.

Case 126 (Senn, *Jour. Am. Med. Ass.,* 1890, p. 845).—Female, age 53. Prior history: Vomiting for one year. Tumor: Very variable, size of orange, above and to right of navel. Operation: Disinvagination; resection; lateral implantation. Variety: Cecum into transverse colon. Died. Pathological remarks: Carcinoma, valve of Bauhini.

Case 127 (Billroth, 1890).—Male, age 32. Prior history: Colic three months in navel region. Tumor: Sausage-shaped, above and to right of navel. Operation: Partial reduction; resection of ileum and cecum; circular suture. Variety: Cecum into transverse colon. Died. Pathological remarks: Carcinoma of cecum.

Case 128 (König, *Arch. klin. Chir.,* 1890, Bd. 40).—Female, age 18. Prior history: Primary sarcoma of tonsil; violent colic since. Tumor: Size of fist, above and to left of navel. Rectal examination: Blood and mucus. Operation: Resection of intussusceptum through cut in intussuscipiens. Colon. Died. Pathological remarks: Sarcoma, valve of Bauhini.

Case 129 (Von Baracz, *Arch. klin. Chir.,* 1891).—Male, age 2. Prior history: Painful abdominal crises, thirteen weeks. Tumor: Oval, ventral, movable in upper left hypochondrium. Rectal examination: Blood in stools. Operation: Irreducible,

ileocecal into descending colon; enterostomy. Died. Pathological remarks: Sarcoma, valve of Bauhini.

Case 130 (MacCormac, *Lancet,* 1892, p. 310).—Male, age 36. Prior history: Painful abdominal crises for fifteen months. Tumor: Intermittent, cylindrical, immovable, in right iliac fossa. Operation: Reduced to end of colon; resection; artificial anus, subsequently closed. Ileocecal. Recovered. Pathological remarks: Carcinoma of valve of Bauhini.

Case 131 (Barton, *Annals of Surgery,* 1893, p. 322).—Male, age 27. Prior history: Occasional obstruction for some weeks. Operation: Irreducible; resection; artificial anus. Ileocecal. Recovered. Pathological remarks: Epithelioma of valve of Bauhini; death in operation for closure of artificial anus.

Case 132 (Körte, *Beitrag Bruns,* Bd. 40, p. 523).—Male, age 49. Prior history: Eighteen months, pain in right hypogastrium with constipation. Tumor: Transverse, sausage-shaped, below navel, slightly movable. Operation: Resection without attempt at reduction; end-to-end with Murphy button. Ileocecal. Recovered. Pathological remarks: Lymphadenoma of valve Bauhini.

Case 133 (Lowenstein, *Ver. d. Deut. G. Ch.,* 1890, 94-97). —Male, age 56. Prior history: Occasional abdominal pain for three months with emaciation. Bowels: Persistent constipation; occasional diarrhea. Tumor: In left upper segment, elastic, size of several fists. Rectal examination: Tenesmus. Operation: Resection; end-to-end with suture. Ileum into colon. Recovered. Pathological remarks: Carcinoma, cecum.

Case 134 (Lejars, *Rev. de Gyn. e. Chir. abd.,* 1897, i, 1029). —Female, age 40. Prior history: Two years, emaciation; six months, colicky attacks of pain; finally obstruction and vomiting. Bowels: First glairy stools, then diarrhea. Tumor: Firm, very movable to left navel. Visible peristalsis. Operation: Irreducible; resection after division; end-to-end with Murphy button. Ileocecal to ascending colon. Recovered. Pathological remarks: Lymphadenoma of valve of Bauhini.

Case 135 (Wallenberg, *Berl. klin. Woch.,* 1864, p. 497).—Female, age 21. Prior history: Three days, constipation, followed by vomiting, cramps and diarrhea. Distention for one week. Operation: Discharge of slough, one foot long, of small intestine without relief. Died. Pathological remarks: Five and one-half weeks after, autopsy showed sarcoma of cecum.

Case 136 (Pitts, *Brit. Med. Jour.,* 1901, ii, 574).—Male, age 32. Prior history: Ill four months. Operation: Resection; lateral implantation. Cecal. Recovered. Pathological remarks: Malignant growth at starting point.

Case 137 (Ludloff, *Grenz. Gebeit.,* 1898, 3, 600).—Male, age 6. Prior history: Five weeks after short attack of pain, subsiding with splashing sound, lately including pain; emaciated. Bowels: Constipation; lately diarrhea. Tumor: Size of fist, below right border of ribs. Visible peristalsis on rubbing abdomen. Operation: Resection; end-to-end circular suture. Ileocecal to one-half transverse colon. Recovered. Pathological remarks: Tumor at neck; lymphosarcoma; glandular enlargement; well four and one-half years later.

Case 138 (Von Eiselsberg, *Archiv. klin. Chir.,* Bd. 69, p. 1). —Female, age 40. Prior history: Colic eleven weeks, eleven days' constipation. Bowels: Tenesmus, three weeks. Rectal examination: Blood and mucus eleven days, tumor in rectum fourteen days. Some distention. Operation: Resection; end-to-end suture. Sigmoid. Pathological remarks: Carcinoma.

Case 139 (Krecke, *Munch. med. Woch.,* 1900, i, p. 42).—Female, age 63. Prior history: Dysentery sixteen years ago; one year, irregular stools, vomiting, pain in right side in attacks; tender tumor. Tumor: Egg tumor in left lower abdomen, intermittent in appearance. Vaginal and rectal examination negative. Visible peristalsis. Operation: Resection, after preliminary division of colon; end-to-end suture. Ileum into ascending colon. Recovered. Pathological remarks: Carcinoma of cecum; well one year after operation.

Case 140 (Rowlands, *Med. Press and Circ.,* 1909, 88, p. 348). —Male, middle age. Prior history: Eighteen months, occasional pain and bleeding from anus; acute for past three days; vomiting. Bowels: No stool. Rectal examination: Invagination in rectum. Distention increasing. Operation: Removed through anus, followed by reduction and suture through laparotomy. Sigmoid. Recovered. Pathological remarks: Carcinoma.

Case 141 (Reidel, *Deut. med. Woch.,* 1909, 35, 1654).—Male, age 43. Onset: Acute, vomiting. Bowels: Dark, nonbloody stool with enema. No tumor. Distention marked. Operation: Small multiple tumors felt in intestinal wall. Ileac. Died. Pathological remarks: Invagination 10 inches above ileocecal valve; multiple sarcoma in Peyer's patches with mesenteric glands involved.

Case 142 (Dujon, *Bull. et mem. Soc. Anat.,* 1909, 84, 515-

533).—Male, age 54. Prior history: Chronic obstruction for two months. Operation: Resection; lateral anastomosis with Murphy button. Near cecum. Died. Pathological remarks: Second invagination at duodenum, both due to annular cancer.

Case 143 (Kammerer, *Annals of Surgery,* Aug. 1898).—Female, age 50. Prior history: Occasional pain and vomiting. Bowels: Alternately constipation and diarrhea. Tumor: In pelvis, left side, somewhat changeable. Rectal examination: Tip of rounded mass felt. Operation: Reduced, enterostomy; wide excision of growth. Enteric. Recovered. Pathological remarks: Sarcoma.

Table C

Acute Cases without Cause

Case 195 (Elliot, *Tr. Am. Surg. Ass.,* 1905, 23, 295).—Male, age 38. Onset: Two weeks, vomiting. Bowels: Diarrhea. Tumor: Left lower quadrant, movable. Distention and rigidity. Operation: (1) Incised colon to relieve constriction; two attempts to close artificial anus. Cured.

Case 196 (Hall, *St. L. Clinic,* 1906, 19, 39-47).—Female, age 52. Prior history: Indigestion, occasional nausea and vomiting. Onset: Two hours, pain and vomiting. Tumor: Right lower quadrant. Operation: Ileocecal; reduction. Cured.

Case 197 (Riley, *Den. M. Times,* 1905-6, 25, 447-451).—Female, age 35. Prior history: Ten years, neuralgia of stomach. Onset: Sudden pain. Tumor: Felt under anesthesia. Operation: Ileac, reduced. Cured. Following operation, good health but for hyperchlorhydria. One year after first attack, same symptoms, with vomiting, Tumor: Not found. Distention: Extreme peristalsis. Operation: Ileac, higher up, reduced. Cured.

Case 198 (Third, *Queen's M. Quart.,* 1905-6, 10, 70-73).—Female, age 52. Prior history: Recurring attacks July, 1903, to Nov., 1905, with progressively worse symptoms. Onset: Last attack sudden, pain and vomiting. Bowels: Diarrhea and constipation, irregular. Rectal examination: Large tumor: Left lower quadrant. Distention: marked peristalsis. Died. Pathological remarks: Autopsy: remainder of colon and all but 8 ft. of small bowel in descending colon, sigmoid, and rectum protruding.

Case 199 (Sherran, *Clin. J. Lond.,* 27, 184-187).—Female, age 49. Prior history: Umbilical hernia. Onset: One day, sudden pain and vomiting. (Hernia swollen, easily reduced.)

Rectal examination: Blood. Tumor: Hernia (umbilical). Operation: Free fluid; relief of strangulated hernia. Cured. Pathological remarks: Nine days after operation passed section of intestine 3½ inches long; eighteen months later, signs of obstruction; operation, mass of adhesions at transverse colon; ileocolostomy.

Case 200 (Ware, *Lancet,* 1906, ii, 1721).—Female, age 27. Onset: Sudden pain. Bowels: Constipation. Tumor: Ill-defined, right lower quadrant. No distention. Operation: Ileac, irreducible; resection; suture. Cured. Pathological remarks: Twenty-two months later, symptoms of acute obstruction; rigid abdomen; operation; gangrenous lump, composed of small intestine twisted on itself; resection with Murphy button; cured.

Case 201 (Thompson, *Brit. Med. Jour.,* 1907, i, 1867).—Male, age 52. Onset: Sudden, five days, vomiting. Bowels: Constipation. Operation: Lower ileac; reduced. Died same evening.

Case 202 (Combs, *Wis. Med. Jour.,* 1907-08, 6, 251-255).—Female, age 54. Onset: Acute, pain and vomiting relieved by enemas; recurred in two days with fecal vomiting. Tumor: Right pelvis. Operation: Ileac, 9 inches above ileocecal valve; attempt at reduction, tear; resection. Cured.

Case 203 (Riess, *Am. Jour. Med. Sc.,* 1907, n. s. 134, 841). —Male, age 27. Onset: Acute, forty-eight hours, pain and vomiting. Operation: Ileocolic, irreducible; ileocolostomy. Died.

Case 204 (Codman, *Bost. Med. and Surg. Journ.,* 1908, 158, 439-446).—Male, age 43. Onset: Acute, five days, pain and vomiting. Rectal examination: Blood. Tenderness in right lower quadrant. Operation: Ileocecal, irreducible; Mixter tube in ileum, neck of mass left in wound after ligation of mesocolon; ten days later, attempt at enterocolostomy; second attempt caused death.

Case 205 (*Ibid.*).—Male, age 24. Onset: Sudden, vomiting three days. Bowels: Moved. Rectal examination: Tenderness in whole pelvis, especially in right. Tumor: Right lower quadrant. Distention: Tenderness in right lower quadrant. Operation: Colic; resection. Cured.

Case 206 (*Ibid.*).—Male, age 38. Onset: Two weeks, vomiting and pain. Bowels: Diarrhea, seven to twenty stools a day. Oval tumor in left side, doughy, firm. Rigidity, considerable. Distention, moderate. Operation: Colic, intussus-

ception removed through long slit in colon; Mixter tube in same opening. Cured.

Case 207 (Elgart, *Wein. klin. Woch.*, 1903, p. 923).—Female, age 31. Prior history: Ten days ago, bloody stool. Onset: Acute, pain and vomiting. Bowels: Stool at beginning. Tumor: Oblique in right hypochondrium. Rectal examination: Blood. Operation: Reduction to 5 cm. above ileocecal valve; then resection with end-to-end by Murphy button. Ileocecal half way up ascending colon. Recovered. Pathological remarks: No tumor or ulcer.

Case 208 (Chirat, *La Prov. Med.*, 1896, p. 604).—Female, age 19. Prior history: Peritonitis five years ago. Onset: Acute, pain and vomiting for thirty-six hours. Bowels: No stools or gas. Rectal examination: Blood from second day on. Distention moderate. Death seven days after onset without operation. Pathological remarks: Enteric invagination, upper jejunum and ileum, easily reduced; no cause.

Case 209 (Knotz, *Prag. med. Woch.*, 1896, 779).—Female, age 29. Prior history: Round worms. Onset: Acute, paroxysms of pain and vomiting. Bowels: No flatus. Tumor: Sausage-shaped, left side, not movable. Rectal examination: Mucus and blood; apex felt per rectum. Distention beginning in right side. Operation: Complete reduction by injection of water.

Case 210 (Bruner, C., *Beitrag*, 25, p. 344).—Male, age 20. Onset: Acute pain and vomiting. Tumor: Cylindrical, in right lower quadrant. Operation: Reduction only after incision of neck of invagination; resection; end-to-end with suture. Ileocecal. Died. Pathological remarks: No special cause.

Case 211 (Michaux, *Bull. Soc. Chir.*, 1900, p. 734).—Male, age 29. Onset: Acute pain and vomiting. Tumor: Sense of tumefaction. Rectal examination: No blood or mucus. Distention moderate; rigidity. Operation: Reduced. Enteric. Recovered. Pathological remarks: No cause.

Case 212 (*Ibid.*).—Female, age 28. Onset: Acute pain and vomiting. Tumor: Mobile tumor in right lower quadrant, intermittent with pain. Tenderness and rigidity in right lower quadrant. Operation: Thirteen days after onset, irreducible; resection; lateral implantation. Ileocecal.

Case 213 (Pringle, *Brist. Med. Chir. Jour.*, Dec., 1899).—Female, age 50. Prior history: Sharp colicky pain, intermittent, six months' duration. Tumor: Firm mass below navel, during pain. Distention. Operation: Irreducible; resection;

end-to-end into abdominal wall. Enteric. Died. Pathological remarks: Intussusception 3 feet from pylorus.

Case 214 (Helbring, *Cent. f. Ch.,* 1901, 672).—Female, age 39. Onset: Acute pain and vomiting. Tumor: Movable, felt per vaginam. No distention. Operation: Irreducible; resection; lateral implantation. Ileocolic. Recovered. Pathological remarks: No mention of cause.

Case 215 (Pitts, *Brit. Med. Jour.,* 1901, ii, 574).—Male, age 31. Onset: Acute, eight days' duration. Operation: Resection; enterostomy. Enteric. Died. Pathological remarks: Death from peritonitis.

Case 216 (Jenly, *Wien. klin. Woch.,* 1901, p. 1177).—Male, age 28. Onset: Acute, vomiting and hiccough. Bowels: No stool, no flatus. Abdomen retracted. Operation; lateral implantation. Iliac, gangrenous. Recovered. Pathological remarks: No special cause.

Case 217 (*Ibid.*).—Female, age 27. Onset: Acute, six days' pain and vomiting. Bowels: Daily stool. Tumor: Above and to left of navel, hard tumor, sausage-shaped. Rectal examination: No blood, no mucus; rectum negative. Distention: Moderate. Operation: Ileocolostomy, followed by subsequent resection. Ileocolic to splenic flexure. Recovered. Pathological remarks: Edematous condition of ileocecal valve.

Case 218 (Ludloff, *Grenz. Gebiet.,* 1898, iii, p. 600).—Male, age 22. Prior history: Three attacks in three weeks with acute cramps of short duration, and tumor. Bowels: Daily diarrheal stool. Tumor. Sausage-shape, above navel. Distention: Slight. Operation: Complete resection with end-to-end by suture. Ileocecal to splenic flexure. Recovered. Pathological remarks: No cause.

Case 219 (Roberts, *Kentucky Med. Jour.,* 1909, viii, p. 1212). —Female, age 25. Prior history: Constipation and indigestion for months. Onset: Acute, colicky pain; no vomiting at first. Bowels: No stools. Oblong tumor below umbilicus. Rectal examination: Tenesmus. Rigidity: Slight. Operation: Gangrenous; resection with end-to-end suture. Ileac. Died. Pathological remarks: Death from peritonitis.

Case 220 (Poitan, *Pedriat., Lille,* 1909, vii, 63-66).—Male, age 18. Onset: Acute, pain and vomiting, subsiding. Symptoms of peritonitis on sixteenth day. Bowels: No stool or flatus. Distention and rigidity: Slight, right side. Operation: Five feet above ileocecal valve; resection; end-to-end by suture. Ileac. Recovered. Pathological remarks: No cause.

Case 221 (Sherran, *Annals of Surgery,* 1909, i, 875-878).—Male, age 30. Onset: Acute, pain and vomiting. Bowels: Two loose stools followed by complete constipation. Rectal examination: Blood. Distention: "Rectovesical pouch filled with fluid." Operation: Reduced with difficulty. Ileocolic. Recovered. Pathological remarks: No cause.

Case 222 (Gibbon, personal communication).—Male, age 19. Prior history: Previous good health. Onset: Sudden pain and vomiting. Bowels: Constipation. Tumor: Right lower quadrant. Rectal examination: Negative. Rigidity. Operation: Split colon; resection of intussusceptum; lateral ileocolic anastomosis. Ileocolic. Recovered.

Case 222a (*Ibid.*).—Male, age 59. Onset: History indicating intestinal obstruction. Operation: Resection; ileostomy; colostomy. Ileocecal. Died. Pathological remarks: Patient in bad condition; bowels gangrenous.

Case 223 (Kersten, *Deut. Zeit. f. Chir.,* 1899, Bd. 51, Hft. 56).—Male, age 39. Prior history: Two months ago, following lifting heavy weight, abdominal pain and constipation. Onset: Four days, pain. Tumor: Left side. Distention. Operation: Ileocolic, split intussuscipiens; resection of intussusceptum, including perforation. Recovered. Pathological remarks: Intussusceptum gangrenous; bloody purulent abdominal fluid; perforation.

Case 224 (Wilson, *Transylvania Jour. Med.,* 1835, viii, 486).—Male, age 18. Onset: Seventeen days. Bowels: Intestinal obstruction symptoms one hundred and eighty-one days. Cured. Pathological remarks: Gangrenous bowel.

Case 225 (Howse, *Med. Chi. Trans.,* 1876, lix, 85).—Male, age 33. Onset: Eighteen days. Operation: Mass taken outside abdomen and reduced, replaced. Cured.

Case 226 (Bellamy, *Brit. Med. Jour.,* 1879).—Female, age 34. Onset: Pain and vomiting (fecal). Rectal examination: Ileum and colon protruding. Abdominal tumor. Operation: Ileocecal; bimanual reduction. Cured.

Case 227 (Kleberg, *Arch. f. klin. Chir.,* 1879, xxiv, 387.)—Male, age 40. Prior history: Hernia one year before; intestinal obstruction; operation, cure. Onset: Few hours. Variety: Double, from above down and from below up, in a common intussuscipiens.

Case 228 (Mikulicz, Braun, *l. c.,* 690, No. 188).—Adult. Prior history: Constipation. Onset: Pain. Bowels: Constipation, followed by bloody stool. Tumor: Right lower

quadrant, moved to epigastrium then to left lower quadrant. Operation: Colic into sigmoid.

Case 229 (Braun, *Verh. d. Deut. Gesell. f. Chir.,* 1885, 501). Female, age 36. Prior history: Slight pain in right lower quadrant. Onset: Eight days, pain and vomiting. Distention. Operation: Ileocecal; resection; suture of perforation. Died. Pathological remarks: Autopsy: General peritonitis, gangrenous bowel.

Case 230 (Kuster, *Verh. d. Deut. Gesell. f. Chir.,* 1879, i, 81).—Male, age 42. Six days, pain and vomiting (fecal). Rectal examination: Blood. Operation: Ileocecal; resection. Died. Pathological remarks: Gangrenous bowel, peritonitis.

Case 231 (Wahl, Braun, *l. c.*).—Age, 44. Onset: Gradual for nine days, vomiting. Bowels: Constipation. Rectal examination: Prolapse from anus, size of child's head on ninth day. Rigidity: At localized spot, inferred to be tumor. Operation: Artificial anus; ileocecal. Died. Pathological remarks; 29 cm. ileum, ascending colon, and transverse colon in descending colon; ileocecal valve at anus.

Case 232 (Winniwarter, *Mitt. auf. d. XIV Cong. d. Deut. Gesell. f. Chir. Brieflich. Notiz.*)—Male, age 60. Onset: Sudden, while at stool, pain. Bowels: Constipation absolute. Tumor: Left lower quadrant. Operation: Artificial anus. Pathological remarks: Bloody serum in abdomen.

Case 233 (Carrier, *Gaz. med. de Lyon,* 1866, No. 4).—Male, age 23. Onset: Sudden. Tumor: Right lower quadrant. Operation: Artificial anus. Ileocecal. Died.

Case 234 (Braun, *Verh. d. Deut. Gesell. f. Chir.,* 1885, 501). —Male, age 63. Onset: Sudden pain and vomiting (fecal). Tumor: Parallel to Poupart's left lower quadrant. Distention. Operation: Resection, ileocecal. Died. Pathological remarks: Necrosis, peritonitis.

Case 235 (Pilgrim, *Indian Med. Gazette, 29,* 1894, 297).—Male, age 29. Onset: Sudden pain and vomiting. Rectal examination: Rectal prolapse. Operation. Cured.

Case 236 (Rydygier, *Deut. Zeit. f. Chir.,* 1895, 6, xlii, 113). Male, age 31. Onset: Five days. Operation: Ileocecal into rectum; attempt at reduction, rupture; resection; entero-anastomosis. Died.

Case 237 (*Ibid.*).—Male, age 20. Onset: Sixty hours. Operation: Ileac; resection. Cured.

Case 238 (*Ibid.*).—Female, age 43. Onset: Eight days. Operation: (1) Artificial anus; (2) resection; (3) closure

of artificial anus; separate operations. Cured. Pathological remarks: One year later, 50 cm. piece of bowel passed.

Case 239 (*Ibid.*).—Male, age 26. Onset: Ten days. Operation: Cecal; resection. Died. Pathological remarks: Gangrenous bowel.

Case 240 (*Ibid.*).—Male, age 43. Onset: Fourteen days. Operation: Reduced. Variety not stated. Died. Pathological remarks: Pseudodiphtheria.

Case 241 (*Ibid.*).—Male, age 60. Onset: Ten days. Operation: Ileocecal; artificial anus.

Case 242 (*Ibid.*).—Male, age 68. Onset: Three Days. Operation: Colic; reduction.

Case 243 (*Ibid.*).—Female, age 56. Onset: Eight days. Operation: Ileocecal; resection; removal of mass per anum because of difficulty of bringing it up into abdomen. Died.

Case 244 (Bell, *Montr. Med. Jour.*, 1905, 34, 619).—Male, age 18. Onset: Sudden pain and vomiting. Bowels: Absolute constipation. Operation: Ileac; resection. Died.

Table D

Acute Cases With Known Cause

Case 174 (Burckhardt, *Bericht ü. d. Chir. Abteil. d. Ludwig's Spitalis Charlottenhilfe im Jaarh,* 1884, p. 23).—Male, age 24. Prior history: Swallowed nail four months ago. Onset: Sudden pain. Operation: Ileocecal; reduction. Cured.

Case 175 (Saltzmann, *Leichenstern Prag. Monat.*, 1874).—Male, age 29. Prior history of trauma: Directly after lifting heavy weight. Onset: Sudden pain and vomiting (fecal). Tumor: Right lower quadrant, size of fetal head. Distention. Operation: Artificial anus, after attempt at reduction with resulting rupture. Died.

Case 176 (Alglave, *Bull. et mem. Anat.*, 82, 445-452).—Male, age 40. Onset: Acute, three days pain and vomiting. Bowels: Constipation and tenesmus. Rectal examination: Blood. Distention. Operation: Ileocecal, irreducible: ileosigmoidostomy. Died. Pathological remarks: Autopsy, large ulcer at apex of invagination.

Case 177 (Reiss, *Am. Jour. Med. Sc.*, 1907, n. s. 134, 841-849).—Male, age 17. Prior history: Twenty-sixth day of typhoid. Onset: Acute (diagnosis, perforation). Operation: Jejunal, 3 inches below duodenum; reduced. Cured.

Case 178 (*Ibid.*).—Female, age 19. Prior history: Fortieth day of typhoid. Onset: Pain and vomiting. Bowels: Ten-

esmus. Rectal examination: Blood and mucus. Operation: Ileocolic, reduced. Cured.

Case 179 (*Ibid.*)—Male, age 36. Prior history of trauma: Struck just above crest of ilium by heavy beam; shock twenty-four hours, then pain and vomiting. Pelvic examination: Twelve ounces bloody urine. Rigidity. Operation: Small intestine contracted in many places as if ligatured, at one point enteric invagination for 2 inches; reduction. Died. Pathological remarks: Shock.

Case 180 (Haasler, V. Langenbeck, *Arch.,* Bd. 68, p. 817). —Female, age 26. Onset: Seven days, pain and vomiting. Bowels: Constipation absolute at first; bowels moved later. Distention. Variety: Ileac. Pathological remarks: Tuberculosis of intestine.

Case 181 (Ash, *Brit. Med. Jour.,* 1902, May 3).—Male, age 25. Prior history: Twenty-fifth day, normal temperature following typhoid; relapse fortieth to fifty-seventh day. Onset: Ninth day of relapse; sudden pain and vomiting; collapse. Rigidity: Right lower quadrant. Operation: Ileocolic; reduction. Cured.

Case 182 (Ross, *Annals of Surgery,* 1904, xxxix, p. 604).—Male, age 17. Prior history: Typhoid; on twenty-first and twenty-fifth days, hemorrhages. Onset: Twenty-sixth day, sudden pain. Operation: Three feet from duodenojejunal juncture 3 inches of intussusception; reduction. Cured. Pathological remarks: Diagnosis, perforation.

Case 183 (Watkins-Pitchford, *Brit. Med. Jour.,* Sept. 6, 1902).—Male, age 29. Prior history: Convalescent from typhoid. Onset: Sudden pain and vomiting (blood); collapse. Rectal examination: Black stools. Signs of peritoneal irritation. Intussusceptions in small intestine. Pathological remarks: Mucosa injected.

Case 184 (Fuschius, *Hufeland Jour.,* Bd. lx, 42).—Male, age 28. Prior history of trauma: While on a walking trip suddenly bent and recovered. Onset: Immediate, of pain, vomiting becoming fecaloid; eighteen days, acute symptoms with eructations. Tumor: Upper umbilical region. Distention: Appeared late. Operation: Laparotomy, ileocolic or colic; incised colon; reduction bimanually (in and outside colon); suture of opening; sutured ends carried out of abdomen and removed thirteen days after operation. Cured. Pathological remarks: Stool four days after operation; complete recovery in thirteen days.

Case 185 (Pridmore, *Cent. f. Med.*, xviii, p. 890).—Male, age 40. Prior history: Dysentery. Onset: Peritonitis, fever. Bowels: Pus in stools. Rectal examination: Blood. Tumor: Soft, under right hypochondrium. Died. Pathological remarks: Gangrenous ileocecal invagination; dysenteric ulcer in large intestine.

Case 186 (Stretton, *Lancet*, 1894, ii, 797).—Male, age 20. Prior history of heavy lifting. Onset: Acute pain and vomiting. Bowels: Natural movement; flatus at intervals. Rigidity; no distention; tenderness. Operation: Forty-eighth hour; invagination of lower ileum; reduced with difficulty. Recovered.

Case 187 (Michaux, *Kor. Bl. Schw. Aert.*, 1896, No. 26, p. 148).—Male, age 8. Prior history: Fell 12 feet, and walked home bent over. Onset: Twenty-four hours after, signs of peritonitis. (At end of week, prolapse of intestine, with signs of obstruction; death on eighteenth day.) Operation: Showed retroperitoneal hematoma. Died. Pathological remarks: Autopsy showed enteric invagination with ascarides above.

Case 188 (Steiner, *Cent. f. Chir.*, 1896, 310).—Female, age 21. Onset: Acute, six days' duration. Rigidity and tenderness in iliac region. Operation: Enteric, lower ileum, gangrenous; resection; end-to-end suture with Murphy button. Recovered. Pathological remarks: Date stone found in specimen.

Case 189 (Batul, *Prov. Med.*, 1901, p. 317).—Male, adult. Prior history of trauma: Strenuous ride. Onset: Acute, pain and vomiting. Bowels: No gas or stools for two days. Rigidity and tenderness over spleen; no visible peristalsis. Operation: Tubercular ileum. Died. Pathological remarks: Multiple ulcers in end of jejunum; tuberculous ulcer at apex of invagination; small cavity in lung.

Case 190 (Ludloff, *Grenz. Gebiet.*, 1898, iii, p. 600.)—Female, age 47. Prior history: First attack sixteen years ago. Onset: Pain ten weeks ago, becoming more frequent and ending in acute attack three days ago; vomiting. Rectal examination: Once blood; nothing per rectum. Tumor: Sausage-shaped, intermittent, with pain. Visible peristalsis; distention general; tenderness. Operation: Ileocecal into lower sigmoid, ulcer at apex; ileum and sigmoid anastomosis. Died. Pathological remarks: Secondary obstruction on eighteenth day from extension of invagination; perforation; peritonitis.

Case 191 (Von Eiselsberg, *Archives*, 69).—Female, age 48. Prior history: Two weeks colic, more frequent of late. On-

set: Past two days fecal vomiting. Bowels: Constipation. Distention very great; visible peristalsis. Operation: Ileocecal into middle descending colon; reduction; resection of circular stricture of ileum; end-to-end by suture. Death from cardiac complication after wound was nearly healed.

Case 192 (Vignard, *Lyon. Med.*, 1905, i, 215).—Female, age 23. Prior history: Abdominal trauma fifteen days ago. Onset: One attack six weeks ago with tumor subsiding; no vomiting; after ten days, recurrence. Bowels: Serous, not bloody diarrhea. Tumor: Irregular, sausage-shaped, in right upper quadrant; tumor on left with recurrence. Operation: Partially reduced ileocecal; lateral implantation after resection. Died. Pathological remarks: No leakage had occurred.

Case 193 (Ainsley, *Brit. Med. Jour.*, 1897, ii, p. 82).—Male, age 15. While playing football, sudden pain and vomiting on kicking the ball. Bowels: Constipation; always acted to enema. Rectal examination. Mucus and blood after three days. No tumor. Operation: Gangrenous; resection by Maunsell's method. Cured. Enteric, 3 inches long. Remarks: In perfect health fifteen months after.

Case 194 (Clubbe, *Brit. Med. Jour.*, 1897, ii).—Male, age 10. Prior history of trauma: After pulling cart. Onset: Pain and vomiting, three days' duration. Bowels: Constipation after action. Tumor: Elongated below navel. Operation: Reduction easy. Cecum into descending colon. Recovered.

Table E

Chronic Cases without Cause

Case 264 (Braun, Hanff, *Verh. der Deut. Gesellsch. f. Chir.*, 1885, 501).—Adult. Onset: Seven months, recurrent colic. Rectal examination: Mass in anus; foul mucoid discharges. Operation: Artificial anus. Died. Remarks: Type not given.

Case 265 (Besnier, *Etud. s. l. diagn. et s. l. Trait. de l'Intestin dans la cavite de l'abdomen,* Paris, 1857, p. 62).—Age 23. Onset: Two months, sudden pain; three days, vomiting (fecal). Bowels: Constipation followed by bloody stools. Rectal examination: Blood. Variety: Ascending, sigmoid into colon. Died.

Case 266 (Vergely).—Female, age 19. Prior history: Digestive disturbances one year. Onset: One year pain, vomiting two weeks. Bowels: One year constipation. Rectal examination: Blood; fetid mucus. Operation: Sigmoidorectal, reducible. Pathological remarks: Gangrenous perforation.

Case 267 (Riedel, *Mitt. a. d. Grenz. Geb.*, xiv, 1, 2).—

Female, age 50. Onset: Beginning ten days after last child; fourteen years, recurrent ataacks; acute onset; pain and vomiting sudden, three days' duration. Bowels: Diarrhea, constipation absolute. Rectal examination: Blood. Tumor: Epigastric, varying in size. Distention. Operation: Ileo-ileocecal; resection. Died. Pathological remarks: Venous thrombosis; pneumonia.

Case 268 (Rydygier, *Deut. Zeit. f. Chir.,* 1895-6, xlii, 113). —Female, age 47. Onset: Eight weeks. Operation: Resection; ileocecal. Cured.

Case 269 (*Ibid.*).—Female, age 25. Onset: Five weeks. Operation: Resection; ileocecal. Cured.

Case 270 (*Ibid.*).—Male, age 33. Onset: Four weeks. Operation: Ileocecal; entero-anastomosis. Cured.

Case 271 (*Ibid.*).—Female, age 22. Onset: Six months Operation: Ileocecal; reduction. Cured. Pathological remarks: 20 cm. long.

Case 272 (*Ibid.*).—Female, age 38. Attacks: Twenty-one days ago, eight days ago. Operation: Colic; artificial anus. Died. Pathological remarks: Peritonitis at operation.

Case 273 (*Ibid.*).—Male, age 26. Onset: Thirty-five days. Operation: Ileocecal; reduction. Died. Pathological remarks: Suspicious spot in bowel at operation.

Case 274 (*Ibid.*).—Male, age 30. Onset: Six weeks: Operation: Ileocecal; reduction; anchorage of bowel to abdominal wall. Cured.

Case 275 (Delore, *Rev. de Gyn. et Chir. Abd.,* 1905, 9, 641-658).—Male, age 20. Onset: Two to three years, pain and vomiting. Bowels: Diarrhea. Rectal examination: Blood. Tumor: Left lower quadrant. Operation: Cut intussuscipiens; resection of intussusceptum from inside; ileocecal. Cured.

Case 276 (Kronbach, *Deut. med. Woch.,* 1905, i, 1782).—Age 41. Onset: Seven weeks, sudden onset of pain and vomiting. Rectal examination: Blood. Operation: Ileocecal; reduction; resection.

Case 277 (Hartmann, *Bull. M. Soc. Chir.,* 1908, 34, 563-566).—Male, age 18. Onset: Four months, pain. Bowels: Gurgling. Rectal examination: Blood, gross and microscopically. Tumor: Mobile, felt bimanually. Rigidity: Right upper quadrant. Operation: Ileac; resection.

Case 278 (Batchelor, *N. Orl. M. & S. J.,* i, 1905, 58, 570). —Male, age 54. Onset: Sixty days, pain and vomiting.

Tumor: Fluctuating mass above umbilicus. Operation: Abandoned; ileocecal. Died. Pathological remarks: Gangrenous bowel.

Case 279 (Miller, *Am. Jour. Obst.,* N. Y., 1906, 54, 869).—Female, age 26. Prior history: Four years, attacks. Onset: Pain and vomiting. Bowels: Diarrhea. Tumor: Size small kidney, right lower quadrant, firm, tender, freely movable. Operation: Ileocolic to splenic flexure; irreducible; ileocolostomy.

Case 280 (Jahonlay, *Lyon Med.,* 1907, 108, 1714).—Male, age 52. Onset: Two to three months, pain. Bowels: Constipation. Tumor: Hard, slightly movable, right lower quadrant. Operation: Ileocecal, with supposed cancer; lateral anastomosis; excision. Died. Pathological remarks: Pneumonia; autopsy showed no tumor.

Case 281 (Poisson, *Gaz. med. d. Nantes,* 1908, ii, 26, 336-338).—Female, age 13. Prior history: Forty days ago occasional vomiting with bloody stools; tumor felt below and to left of umbilicus. Onset: Present attack, continuous vomiting. Rectal examination: Forty-five days ago passed slough of small intestine. Distention and visible peristalsis in present attack. Operation: Jejunal, 1 m. below pylorus; below this intestine contracted; intestine at site of former invagination makes angle.

Case 283 (Haasler, V. Langenbeck's *Arch.,* 1902, Bd. 68, 817).—Female, age 32. Onset: Three months, pain becoming severe. Bowels: Eight weeks' constipation followed by diarrhea, some flatus. Rectal examination: Protrusion from anus easily removed by knife. Tumor: Fourteen days. Distention: Asymmetrical. Variety: Ileocecal; cecum and appendix at anus. Died.

Case 284 (Hofmeister, *Zentbl. f. Chir.,* No. 48).—Male, age 32. Onset: Ten weeks, typical invagination symptoms. Rectal examination: 25 cm. mass protruded from anus. Operation: Resection 140 cm. Cured.

Case 285 (Majewski).—Female, age 56. Prior history: Several years hard, tender swelling in cecal region; six months ago sudden pain, vomiting, and diarrhea; subsidence of acute symptoms with increase in size of tumor. Operation: Reduction. Ileum into cecum and ascending colon. Recovered.

Case 286 (Elgart, *Wien. klin. Woch.,* 1903, p. 923).—Female, age 33. Prior history: Four months tumor in abdomen, gradual increase in size; pain in abdomen and back.

Bowels: Normal. Tumor: Sausage-shaped tumor in left flank, smooth, movable. Operation: Reduced with difficulty; cecum anchored. Ileocecal. Recovered. Pathological remarks: No ulcer or tumor.

Case 287 (Stead, *Brit. Med. Jour.,* 1901, ii, 1458).—Female, age 72. Prior history: Chronic constipation with several attacks of colic and flatulence. Rectal examination: Protrusion of "tumor" from anus. Operation: Sphincter divided; reduction. Colon. Recovered. Pathological remarks: No mention of tumor.

Case 288 (Von Eiselsberg, *Archive,* Bd. 69).—Male, age 31. History: Eighteen days' colic, collowed by diarrhea; vomiting after eating. Rectal examination: Blood for two days. Tumor: Long, hard, movable tumor in right side. Distention: Moderate. Operation: Irreducible; ileocecal to hepatic flexure; end-to-end suture. Recovered. Remarks: Three years after, occasional pain, stools normal.

Case 289 (*Ibid.*).—Male, age 35. Prior history: Three years, two years and six weeks ago, severe colic disappearing with enema. Bowels: Stools and gas, scant. Tumor: Sausage-shaped transverse, in upper abdomen. Operation: Reduction; resection to prevent recurrence. Ileocolic. Recovered. Pathological remarks: Three years later in excellent health.

Case 290 (*Ibid.*)—Male, age 36. Prior history: Three months, short colicky attacks; two and a half weeks ago, noticed distended loop. Bowels: Movement to enema for two and a half weeks. Distention: Two and a half weeks. Operation: Reduction; resection with end-to-end anastomosis by suture. Enteric. Recovered. Pathological remarks: Swelling, probably inflammatory, above a stricture of unknown character.

Case 291 (Baracz, *Cent. f. Chir.,* 1894, p. 622).—Male, age 19. Prior history: Three attacks of pain and vomiting, with constipation in past twenty-nine months; diarrhea after last attack. Hard tumor in cecal region for past year. Operation: Ileocolostomy with resection and end-to-end circular suture. Ileocecal, irreducible. Recovered. Pathological remarks: Swelling only inflammatory.

Case 292 (Passagi, *Il Policlinico,* 1905, p. 10).—Male, age 30. Prior history: Intermittent colic, with variable tumor, vomiting over a period of nine months. Bowels: Constipation. Rectal examination: Mucus but no blood. Tumor: Right upper quadrant. Operation: Reduction; endoplication

of cecum by two parallel rows on either side anterior longitudinal band. Ileocecal. Recovered.

Case 293 (Battle, *Med. Presse,* 1897).—Male, age 50. Prior history: Constipation, vomiting for fourteen days. Rectal examination: Blood. Tumor: Sausage-shaped, in left lower quadrant. Operation: Irreducible; cecum anastomosed to colon. Colonic.

Case 282 (Schiller, *Beitrag,* v, 17, p. 635).—Female, age 49. Prior history: For fifteen weeks daily attacks of pain, with no stools or gas lasting fifteen minutes, followed by normal stool. Tumor: Sausage-shaped, elastic, slightly movable. Visible peristalsis. Operation: Reduced. Ileum into colon. Recovered.

Table F

Chronic Cases With Known Cause

Case 245 (Müller, *Arch. f. klin. Chir.,* 1879, xxiv, 183).—Male, age 33. Prior history: Dysentery four months. Onset: Three months, pain and vomiting. Bowels: Irregular, with constipation, becoming absolute. Rectal examination: Blood and mucus. Tumor: Left lower quadrant. Variety: Ileocecal to rectum. Died.

Case 246 (Durante, *Bull. de la Soc. Anat.,* 1879).—Male, age 29. Prior history of trauma: Crushed between two wagons. Onset: Sudden, immediate; vomiting. Bowels: Diarrhea. Rectal examination: Blood. Tumor: Left lower quadrant. Variety: Ileocecal.

Case 247 (Rydygier, *Deutsche Zeitschrift f. Chir.,* 1895, xlii, 113).—Female, age 18. Prior history: Ten years ago appendicitis. Onset: Chronic. Operation: Ileocecal; enterocolic anastomosis. Pathological remarks: Inflammatory stricture of cecum.

Case 247a (*Ibid.*).—Male, age 23. Onset: Two months. Operation: Ileocecal, resection. Died. Pathological remarks: General tuberculosis; invagination began at tuberculous ulcerated stricture.

Case 248 (Haasler, V. Langenbeck *Arch.,* 1902, Bd. 68, 817).—Female, age 42. Prior history of trauma: Six weeks ago fell from electric car; concussion of brain. Onset: Few days later vomiting (constant), and pain in right lower quadrant. Bowels: Constipation. Tumor: Three weeks; right lower quadrant. Distention. Variety: Ileocolic.

Case 249 (V. Braman, *Münch. M. Woch.,* 1900, p. 1712).

—Male, age 25. Prior history: Family and personal history, tubercular. Onset: First attack ten months ago; colicky pain; attacks more frequent last 3 months; vomiting. Bowels: Diarrhea. Distention slight; visible peristalsis; tenderness excessive. Operation: Irreducible; coils firmly bound together; resection; enteric. Recovered. Pathological remarks: Probably tubercular.

Case 250 (Cavaillon, *La Prov. Med.*, 1901, No. 24).—Male, age 46. Prior history with onset: Three weeks; occasional severe pain after eating. Bowels: Alternating diarrhea and constipation. Rectal examination: No blood. Tumor: In cecal region, extending into epigastrium. No rigidity; visible peristalsis. Operation: Reduction; ileocecal to splenic flexure. Pathological remarks: Serosa of cecum studded with miliary tubercles.

Case 251 (Quadflieg, *Münch. med. Woch.*, 1901, p. 1093). —Male, age 28. Prior history with onset: Occasional cramps followed by intermittent attacks of acute obstruction for two and a half months, with pain and vomiting. Bowels: Stools normal; occasional constipation. Rectal examination: No blood or mucus. Tumor: Size of fist; changeable position, according to pain. Operation: Partial reduction; resection with lateral implantation; ileocecal to transverse colon. Recovery. Pathological remarks: Broad, deep, circular ulcer in cecum; cause unknown.

Case 252—Male, age 36. Prior history with onset: Typhoid fever one year ago; one attack mild, followed by free interval of six months; latterly constant attacks with vomiting. Bowels: Alternating constipation and diarrhea. Rectal examination: Mucus; rectum negative. Tumor: Movable, size of fist, to right of navel; disappears with cessation of pain. Abdomen: Distention; tenderness. Operation: Complete resection; ileum to colon by suture. Variety: Ileocecal to middle of transverse colon. Recovery. Pathological remarks: Ulcer on invagination.

Case 253 (Maxwell, *St. Barth. Hosp. Rep.*, 1908-1909, 44, 153, 160).—Male, age 28. Prior history: Dysentery for two months. Rectal examination: Mucus and blood. Tumor absent. Retracted abdomen; tenderness over ascending colon. Operation: Irreducible in ascending colon; resection, end-to-end by suture; ileocecal. Died promptly.

Case 254 (*Ibid.*).—Male, age 56. Prior history: Dysentery for one month. Rectal examination: Mucus and blood. Tumor absent. Operation: Partially reducible; lateral anas-

tomosis by Murphy button; ileocecal. Death. Pathological remarks: Seventy-two hours; no tendency to repair.

Case 255 (*Ibid.*).—Male, age 19. Prior history with onset: Trauma, followed in five days by dysentery. Attack, one month duration; pain severe over tumor. Tumor: Sausage-shaped over curve of colon. Operation: Reduced to size of small orange; then lateral anastomosis by suture. Recovery.

Case 256 (*Ibid.*).—Male, age 29. Prior history with onset: Four months ago, lump in right upper quadrant, followed by severe pain; no vomiting. Rectal examination: Blood three months ago on two occasions. Tumor: Sausage-shaped over hepatic flexure, could be seen crossing abdomen from right to left with paroxysms of pain. Operation: Irreducible; covered over surface with miliary tubercles; lateral anastomosis; ileocecal. Pathological remarks: Tubercular.

Case 257 (*Ibid.*).—Male, age 14. Prior history with onset: One month stools small with little blood; eleven days ago pain on right side; vomiting. Bowels: Constipation. Tumor: Indefinite lump over hepatic flexure. Operation: Reduced; lateral anastomosis with suture; ileocecal. Recovery. Pathological remarks: Miliary tubercles on outside.

Case 258 (*Ibid.*).—Female, age 13. Prior history with onset: Dysentery for two months; very emaciated. Tumor: Sausage-shaped over transverse colon, with paroxysmal pain. Operation: Reduced with great difficulty, revealing lump in cecum; excision with lateral implantation; ileocecal. Died in four days from peritonitis. Pathological remarks: lump probably tubercular.

Case 259 (Brin, *Bull. et Mem. Soc. de Chir.*, 1908, 34, 1257-1279).—Male, age 34. Prior history with onset: Three attacks in seven weeks of obstruction with pain and vomiting. Bowels: Bloody diarrhea. Tumor: In right upper quadrant, disappearing with subsidence of pain. Operation: Reduced; ileocecal to transverse colon. Recovery. Pathological remarks: Cecal tuberculosis.

Case 260 (Schiller, *Beitrag*, xvii, p. 635).—Female, age 35. Prior history with onset: Short, severe attacks of vomiting and colic for nine weeks; between attacks normal. Bowels: Diarrhea; frequent tenesmus. Rectal examination: Blood and mucus. Sausage-shaped tumor over transverse colon. Operation: Irreducible; resection, with ileocolostomy; ileocecal. Recovery. Pathological remarks: Ulcer in cecum.

Case 261 (Pridmore, *Brit. Med. Jour.*, 1897).—Male, age

40. Prior history with onset: Supposed malaria, then dysentery with abdominal pains. Bowels: Watery and blood-stained stools. Rectal examination: Offensive stools, with blood and pus before death. Sausage-shaped tumor shifting in position; tender. Variety: Ileocecal. Death. Pathological remarks: Intestine in places gangrenous with old dysenteric ulcers.

Case 262 (Boyce-Barrow, *Lancet,* 1897, i, 1411).—Male, age 11. Prior history with onset: Attacks of abdominal pain for two months; often vomiting solid food. Bowels: No diarrhea. Rectal examination: Blood and mucus past week. Tumor: Size of hen's egg in right upper quadrant; movable; changeable with pain. Operation: Irreducible; resection, end-to-end with Murphy button; ileocecal. Recovery. Pathological remarks: Tubercular ulcer at apex of intussusception.

Case 263 (Orton, *Brit. Med. Jour.,* 1898, i, 489).—Male, age 58. Prior history with onset: For six months pain with offensive stools. Tumor: Soft doughy mass in right lower quadrant, thought to be feces; diminished by enema. Variety: Jejunum into rectum. Death from exhaustion three and a half years after onset. Pathological remarks: Intussusception irreducible; cecal segment occupied by ulcerating mass, size of small egg, thought to be inflammatory.

Table G

Meckel's Diverticulum

Case 144 (Struthers, *Lancet,* 1906, ii, 1345).—Female, age 5. Onset: Two months abdominal pain; two days repeated vomiting. Rectal examination: Prolapse two months, having at apex (reappearing two days ago) a polypoid mass (appendix, one and a half inches long, inverted). Tumor: Left lower quadrant. Distention. Operation: Ileocecal reduced; appendix removed through incision in cecum.

Case 145 (Bridwell, *Lancet,* 1907, ii, 682-684).—Male, age three and a half. Prior history: Four months before, acute onset with hemorrhage from bowel without known cause. Onset: Five weeks pain and vomiting at intervals. Bowels: Complete constipation. Hard tumor in right lumbar region and hypochondrium. Rigidity. Operation: Ileocolic from six inches above ileocecal valve to middle of colon; reduced. Recurrence of pain after one week and two months later. Tumor in umbilical region. At operation an enteric invagination with Meckel's diverticulum at apex. Resection.

Case 146 (Van Mandach, *Corr. Bl. f. Schw. Aertz,* 1907, 37, 729-732.)—Male, age two and a half. Onset: Sudden

vomiting. Bowels: Diarrhea. Tumor in umbilical region. Distention. Operation: Ileocolic reduced; inverted diverticulum reduced itself spontaneously. With reduction several purse string sutures about Meckel's diverticulum to occlude lumen. Cured.

Case 147 (Kothe, *Deut. m. Woch.*, 1908, 34, 2409).—Male, age 23. Prior history: Six months ago abdominal pain. Onset: Three days acute obstruction; pain and vomiting. Operation: Ileocecal; partial reduction; resection; end-to-end by Murphy button. Pathological remarks: Meckel's diverticulum inverted at apex.

Case 148 (Binnie, *Anat. Med. Gaz.*, 1908, 27, 356-358).—Female, age two. Onset: Colic one week, followed by acute obstruction. Tumor: Sausage-shaped; disappeared under anesthesia. Operation: Transverse colon; resection. Cured. Pathological remarks: Appendix inverted; felt through cecal wall.

Case 149 (Delore, *Rev. d. Chir.*, 1908, 38, 39-62).—Male, age six. Prior history: Three or four previous attacks. Onset: Three days, acute. Tumor: Right lower quadrant. Visible coils. Operation: Enteric; irreducible; resection. Death. Pathological remarks: Inverted Meckel's diverticulum.

Case 150 (Coffey, *Annals of Surgery*, 1907, xv, p. 42-48).—Male, age seven. Prior history: At two years severe cramps with vomiting monthly, with bloody stool; at four years similar attack and jaundice. Onset of present attack, acute; pain and vomiting. Bowels: Tenderness of bowel. Rectal examination: Blackberry seeds and later black stool. Tumor: Large in right side. Operation: Ileocecal; irreducible; resection after opening sheath. Cured. Pathological remarks: Inverted Meckel's diverticulum.

Case 151 (Moroni, *Virchow. Hirsch. Jahres Bericht.*, 21, 1898, 289).—Male, age 26. Prior history: Operation for ileus; axial torsion. Onset: Recurrent obstruction. Death. Pathological remarks: Complete enteric invagination caused by turning inside out of Meckel's diverticulum, caused by cherry-shaped fibrous polyp in Meckel's diverticulum.

Case 152 (Ryan, *Intercolonial M. J. Austral.*, 1907, xii, 459-461).—Male, age 9. Onset: Acute; pain and vomiting. Operation: Lower ileac (6 inches from ileocecal valve); resected 12 inches gangrenous gut; ends sutured in wound. Death. Pathological remarks: Starting of intussusception was firm polyp at apex.

Case 153 (Cheyne, *Annals of Surgery*, xl, 1904, p. 796).—

Male, age 19. Prior history: Two years indefinite abdominal pain. Onset: Nine months acute; vomiting recurrent. Operation: Triple: two reduced; third resected, showed Meckel's diverticulum as cause. Pathological remarks: Mucous membrane greatly prolapsed and hypertrophied.

Case 154 (Cowardine, *Lancet,* 1904, Feb. 29).— Age fourteen months. Onset: Collapsed. Operation: Double ileac with Meckel's diverticulum. Death. Pathological remarks: Gangrene.

Case 156 (Robinson, *B. M. J.,* 1899, ii, 1417).—Male, age 5. Onset: Pain and vomiting. Bowels: One stool. Distention; no rigidity; no tenderness; no tumor. Rectal examination: Blood with enema; lump in Douglas's pouch on bimanual examination. Operation: Reduced to inverted Meckel's diverticulum; excision; Lembert suture; enteric four inches long. Death.

Case 157 (Eve, *B. M. J.,* 1901, ii, 582).—Refers to a case of inverted Meckel's diverticulum without clinical notes.

Case 158 (Von Stubenrauch, *Cent. f. Ch.,* 1898, No. 26, p. 137).—Female, age 5½. Onset: Acute for five days; vomiting. Tumor: Moderate distention on fifth day; tenderness; sausage-shaped tumor in midline between anterior superior spines. Rectal examination: Blood and mucus; otherwise negative. Operation: Tear during attempted reduction; resection; circular suture; enteric. Death. Pathological remarks: Inverted Meckel's diverticulum at apex of invagination, in gangrenous condition.

Case 159 (Erdmann, *Annals,* 1900, p. 186).—Male, age 9. Onset: Acute; pain and vomiting. Distention and tenderness; tumor from right iliac fossa to costal margin. Rectal examination: Blood and mucus; tenesmus. Operation fifty-eight hours after onset; irreducible and gangrenous; resection; end-to-end with Murphy button; enteric to within six inches of cecum. Death. Pathological remarks: Inverted Meckel's diverticulum at apex.

Case 160 (Adams, *Tr. Path. Soc.,* London, 1892, p. 75).—Male, age 42. Prior history: Three weeks' duration; obstruction first week; subsidence. Onset: Recurrence with vomiting. Tumor: None; fulness in right lower quadrant. Rectal examination: Blood once with enema. Operation: Ileocolic; gangrenous. Death. Pathological remarks: Inverted Meckel's diverticulum at apex.

Case 161 (Küttner, *Beitrag,* No. 21, p. 289).—Female, age 49. Prior history: Acute attack eight weeks ago, lasting five

days. Onset: Similar attack three days' duration. Operation: Anastomosis between distended and collapsed intestine. Death. Pathological remarks: Meckel's diverticulum intussusception, with three small perforations at base.

Case 162 (Strauch, *Zeit. f. klin. Med.,* 38, p. 465).—Female, age 6. Prior history: Poor digestion; colic from time to time. Onset: Acute, vomiting. Bowels: Diarrhea, followed by constipation. Tumor: Hard and elastic, below navel; tenderness. Operation: Reduction partial, then resection; circular suture; enteric. Death. Pathological remarks: Invaginated Meckel's diverticulum.

Case 163 (Zum Busch, *Cent. f. Chir.,* 1903, p. 733).—Male, age 21. Prior history: Fourteen months dull pain about navel, with alternating constipation and diarrhea; patient being an athlete, accustomed to holding many men on abdomen. Onset: Acute vomiting. Bowels: Several fluid stools with great tenesmus. Tumor and rigidity in right lower quadrant. Rectal examination: Frequently blood. Operation: Reduction difficult; gangrenous; resection, side-to-side; "tumor" in intussusception; ileocolic. Recovery. Pathological remarks: Tumor proved an inverted Meckel's diverticulum, with subserous lipoma at apex; abscess in abdominal wall.

Case 164 (Hohlbeck, *Archives Chir.,* Bd. 61, p. 1).—Male, age 18. Onset: Acute pain and vomiting. Bowels: No gas or stool. Tumor: Sausage-shaped, under anesthesia in right lower quadrant. Rectal examination: No blood. Operation: Third day; reduction, showing Meckel's diverticulum at apex; resection of Meckel's diverticulum; ileocolic. Died.

Case 165 (Travers, *Lancet,* 1902, ii, 146).—Male, age 10. Onset: Acute; vomiting. Bowels: Moved; slight tenesmus. Tumor: Over appendix, firm, tender and dull; no tumor in rectum. Rectal examination: No blood, mucus or flatus since primary attack. Operation: Reduction, except Meckel's diverticulum, which was partially reduced, so as not to obstruct gut; ileocolic into ascending colon. Recovery.

Case 166 (Pitts, *B. M. J.,* 1901, ii, p. 578).—Male, age 15. Prior history: Had eaten pint of cherries. Onset: Pain and vomiting, becoming worse on fifth day. Tumor: None; distention great on fifth day. Rectal examination: No blood or mucus. Operation: Enterostomy; evacuation gas and contents; suture; reduction to inverted Meckel's diverticulum, removed by enterotomy; ileocolic to hepatic flexure. Recovery.

Case 167 (Dobson, *Lancet,* 1903, i, 1161).—Male, age 4½.

Onset: Pain and vomiting. Tumor: In right iliac fossa; soft; mobile. Rectal examination: Blood and mucus. Operation: Reduced to apex, where inverted Meckel's diverticulum projected into gut; resection of Meckel's diverticulum segment, not including mesentery; ileocolic. Recovery. Pathological remarks: No fecal fistula.

Case 168 (Wainwright, *Annals of Surgery,* 1902, 1).—Male, age 17. Gradual onset of six days; pain and vomiting twenty-four hours. Bowels: Constipation obstinate. No tumor; abdomen retracted; tenderness below. Rectal examination. Operation: Thirty-six hours after acute onset; complete reduction, including an inverted Meckel's diverticulum which was removed; enteric, three inches long. Recovery.

Case 169 (Weil and Frankel, *Soc. Anat.,* 1896, p. 918).—Female, age 4½. Onset: Acute; pain and vomiting thirty-six hours. Bowels: Constipation. Cylindrical, tender tumor over appendix. Rectal examination: Blood. Operation: Reduction; gangrenous; resection; circular suture; ileocolic. Died. Pathological remarks: Meckel's diverticulum at apex.

Case 170 (Brin, *Bull. Mem. Soc. d. Chir.,* 1908, 34, p. 1267-1279).—Female, age 39. Prior history: Attacks two or three times yearly for twelve years. Onset: During past year, tenderness between attacks. Pelvic tumor, thought to be salpingitis. Operation: Supravaginal hysterectomy; acute obstruction eight days later; reduced; evagination and resection of Meckel's diverticulum; ileac. Recovery. Pathological remarks: Inverted Meckel's diverticulum.

Case 171 (Riedel, *Deut. Med. W.,* 1909, 1654).—Female, age 25. Onset: Acute pain. Bowels: Constipation; no stool or flatus. No tumor; tenderness over navel; distention slight. Operation: Resection; enteric. Died. Pathological remarks: Meckel's diverticulum inverted and gangrenous.

Case 172 (De Quervain, *Cent. f. Ch.,* 1898).—Male, age 16. Onset: Acute; pain and vomiting. Bowels: Several movements; one black stool. No tumor; distention moderate. Rectal examination: Negative. Operation: Resection; fixation of ends in wound; ileac. Died. Pathological remarks: Meckel's diverticulum; inner layers gangrenous.

Case 173 (Ewald, *Berl. K. W.,* 1897, p. 169).—Female, age 42. Prior history: Repeated attacks of obstruction in seven months. Visible peristalsis. Death sudden, without operation. Pathological remarks: Intussusception of Meckel's diverticulum, with stricture of small intestine and perforation.

Case 173a (Moore, per communication).—Twenty-five. Prior history: Several years abdominal colic; diagnosis, appendicitis. Onset: Twenty-four hours; acute. Operation: Reduction; resection of diverticulum; ileocolic. Recovery. Pathological remarks: Bowel dark but not gangrenous; one slight attack of colic since operation.

Table H

Discharge of Necrotic Intussusceptum Per Rectum

Case 1 (Catterina, *Clin. Chir.,* 1898).—Female, age 47. Onset: Acute; strangulation. Tumor: Round, oval, size of fist, slightly movable; para-umbilical. Operation: Irreducible invagination; anastomosis with Murphy button. Subsequent discharge of slough.

Case 2 (Pozza, *Clinica Ch.,* 1901).—Female, age 37. Onset: Sudden; pain right side; vomiting, at length fecal. Rectal examination: Bloody mucus fourth day. Tenderness. Operation: Sixth day; entero-anastomosis, Murphy button. Discharged slough thirteenth day, 60 cm. long. Recovery. Slough consisted of ileum, cecum and ascending colon; no vermiform appendix.

Case 3 (Wechsberg, *Cent. f. All. Path.,* etc., 1900, p. 193). —Age, 18. Prior history: Acute gastritis; round worms. Onset: signs of peritonitis and fever. Bowels: Discharge of worms not followed by relief. Tumor: Variable position: (a) above navel; (b) right iliac fossa. Tenderness. Operation refused; discharge of slough, composed of cecum and small intestine in second week. Recovery. End result: Fourteen months later, after several attacks of pain, acute obstruction; death; autopsy showed small intestine terminating in colon below hepatic flexure, with stricture and scars in ascending colon and splenic flexure.

Case 4 (Schridde, *Münch. Med. Woch.,* Bd. 50).—Female, age 60. Prior history: Tubercular; signs of late stage. Onset: Pain lower right side; vomiting. Bowels: Stool at onset, afterward constipation. Rectal examination: First stool fifth day. Tenderness and distention; visible peristalsis. Discharge of slough on twelfth day; three months later death from acute pulmonary process. Recovery. End result: Autopsy showed annular stricture 36½ cm. above ileocecal valve; visceral lesions.

Case 5 (Hallmann, *St. Peter's Med. Wo.,* Bd. 28, 1903).—Male, age 49. Three months ago onset; pain and vomiting, followed by loss of appetite. Bowels: Very fluid stools.

Rectal examination: Mucus and blood. Tumor: In left iliac region, disappearing on inflation. Discharge of slough at end of third month. Recovery. Slough consisted of ileum, cecum and large intestine, with tape-worm still attached.

Case 6 (Polya, *Owosi Hetilap,* 1905).—Male, age 44. Onset: Sudden; incomplete obstruction. Rectal examination: Tumor protruded from anus. Tumor: Beneath right border ribs. Slough 42 cm. long. Recovery. Cecum, appendix and ileum. End result: Occasional recurrence of meteorism suddenly relieving itself.

Case 7 (Hermes, *D. Zeit. für Chir.,* Bd. 77).—Male, age 23. Onset: Sudden; colic; pain on micturition; eight days' duration. Distention and tenderness over bladder. Discharge of slough fourteenth day; secondary stricture of rectum cured by artificial anus and subsequent dilation. Recovery.

Case 8 (Camhours, *Bull. Soc. Anat.,* 1906).—Female, age 23. Prior history: Tubercular family and personal history. Onset: Acute; pain. Bowels: Stools for five days. Rectal examination: Blood. Discharge of slough fifteenth day, consisting of portion of jejunum. Recovery. End result: Persistent distention with painful puffiness one month after discharge of slough.

Case 9 (Haedke, *Med. Klinik.,* 1906).—Age 3½ months. Onset: Acute; vomiting five days' duration. Bowels: Constipation. Rectal examination: Blood; irreducible prolapse. Operation refused; stools recurred; death two days later. End result: "Autopsy showed nature healing as in strangulated hernia."

Case 10 (Kolbe, *Deut. Med. Woch.,* No. 21).—Male, age 40. Prior history: Dyspepsia, distention, obstipation and hemorrhoids fifteen years. Onset: Three days' colic; vomiting. Bowels: Profuse diarrhea. Rectal examination: Blood and mucus; pus. No rigidity; borborygmi. Discharge of slough 20 cm. long. Recovery. End result: Marked improvement after slough was discharged.

Case 11 (Solberg, *Norsk. Mag. for Layrrid,* 1898).—Female, age 30. Onset: Acute obstruction. Discharge of slough fourteenth day. Recovery. End result: Eight weeks later death from second obstruction; no autopsy.

Case 12 (Segal, *Jeshenéde Vrick,* 1898).—Male, age 56. Prior history: Constipation. Onset: Chronic; pain and frequency of urination. Thirteen days after admission discharge of slough, and two days later a second larger slough. End

result: Improvement, followed by opening of abdominal abscess into bladder; persistence of pyuria and granular casts.

Case 13 (Raven, *l. c.*).—Age 9. Onset: Acute; pain and vomiting. Bowels: Obstipation after primary stool. Distention, tenderness and rigidity. Operation; gangrenous loop; enterostomy; ten days later discharge through fistula of slough. Recovery. End result: Intermittent closure of fecal fistula; death four years later from neglected acute obstruction; autopsy showed almost complete stenosis two feet above valve.

Case 14 (Chodkiewicz, *Kiel. Inaug. Dissert.*, 1878).—Male, age 20. Prior history with onset: Abdominal pain of long standing. Bowels: Diarrhea. Rectal examination: Blood and mucus; intermittent. End result: Death after five and a half months; autopsy showed small intestine opening into transverse colon; the discharge of slough was unnoticed.

Case 15 (O'Connor, *B. Med. J.*, 1894, p. 123).—Male, age 13. Onset: Three days after severe wetting; symptoms of obstruction and peritonitis. Discharge of slough of small intestine, with Meckel's diverticulum on about twelfth day. Recovery. End result: Twelve months after attack patient was well.

Case 16 (Sutcliffe, *B. Med. J.*, 1894, p. 124).—Male, age 17. Onset: Acute, with symptoms of obstruction and peritonitis for twelve days. Discharge of slough of large intestine on seventeenth day. Recovery. End result: One week after discharge of slough recurrence of symptoms for five days; dysenteric stools persisted forty days.

Case 17 (Slesser, *Lancet*, 1879, vol. ii, 909).—Age seven months. Onset: Pain. Rectal examination: Blood; dark gray membrane protruding. Tumor: Hardness lower part body. Twelfth day, passed cecum, part of colon and appendix. Remarks: Well sixteen months; last heard.

Case 18 (Schmidt, *D. Zeitsch. f. Chir.*, 1898, Bd. 48, p. 83).—Female, age 48. Prior history: Operation (Jan. 3) for carcinoma of stomach; pylorectomy. Onset: January 8; pain and vomiting. Bowels: Diarrhea; thin, foul mucus. January 27 expelled six-inch section of colon; invaginated. Abscess appeared in upper angle of wound; death February 28; at autopsy stricture in middle of the transverse colon; specimen passed showed that intussusceptum was composed of that part of colon which was freed during the pylorectomy.

Case 19 (Krabbel, *D. Med. Woch.*, 1879, No. 41, p. 525).—Female, age 44. Prior history: Child bed. Onset: Ninth day

sudden pain and vomiting (fecal); collapse. Bowels: Constipation; thin diarrhea. Tumor: Right side. Distention upper part of abdomen; visible peristalsis. Following calomel sudden improvement; bowels moved; later 48 cm. ileum in fair condition passed. Recovery. Pathological remarks: Death later of tuberculosis. Autopsy: 15 cm. above valve Bauhini a strong scar (circular) narrowing lumen of gut but not obstructing it; bowel somewhat dilated above.

Case 20 (Kofmann, *Centralblatt f. Chirurgie,* 1895, 22, p. 941).—Female, age 22. Onset: Pain and vomiting; sudden. Bowels: Constipation; stool normal in three weeks (following tearing pain in right side), then diarrhea. Tumor in left side; proved to be abscess; drained. Distention. Eight weeks after onset passed ¼ m. bowel. Recovered. Remarks: Recurrence of obstruction symptoms: operation; search of small bowel caused rupture, just below it a stricture (complete) of jejunum thought to be site of intussusception.

Case 21 (Hampelu, *St. Petersburg Med. Woch.,* 1883, Bd. 8, p. 161).—Female, age 43. Prior history: After lifting heavy burden, sudden pain and vomiting. Rectal examination: Blood; rectal mass. Tumor: Left lower quadrant, movable. Tumor reduced bimanually; hand up to splenic flexure by rectum. Discharge and character of slough: Twenty-second day; 15 cm. bowel passed; ileocecal with appendix, cecum and part of ascending colon. Recovery.

Case 22 (Pheland, *Gaz. d. Hop.,* 1840, 14).—Age 18. Prior history of trauma: Severe blow. Onset: Pain and vomiting for fourteen days. Bowels: Constipation. Tumor: In right lower quadrant.

Case 23 (Kriz, *Wien. Med. Press,* 1896, 49).—Female, age 38. Prior history: Three days' constipation, then normal stool. Onset: Pain and vomiting. Rectal examination: Blood and mucus. No rigidity. Tumor: Smooth, sausage-shape, between hepatic and splenic flexures. Operation: Reduction by massage; recurrence after two weeks; operation refused; slough discharged seventeenth day. Recovery. Remarks: Stools feculent, fluid and foul.

Case 24 (Parker, *B. M. J.,* 1896, ii, 840).—Male, age 27. Prior history: Colic and constipation; no vomiting. Onset: Gradual increasing pain; one month's duration. Bowels: Alternating diarrhea. Rectal examination: Blood and mucus. Some distention. Discharge of slough ten to twelve inches long. Recovery. Remarks: After three years of good health

death from obstruction in six weeks; invagination in lower descending colon.

Case 25 (Marchand, *Berl. klin. Woch.*, 1896, 6).—Male, age 14. History of wrestling. Rectal examination: Intermittent blood. Operation: Spontaneous discharge of enteric slough. Death from peritonitis.

Case 26 (Castelain, *Gaz. Hebd.*, 1870, No. 20).—Male, age 43. Prior history: Habitual constipation. Onset: Loss of appetite; nausea. Bowels: Constipation. Rectal examination: Blood and mucus; tenesmus. Distention and rigidity: Case mentioned under benign tumor. Fourth week; discharge of large tumor with thin pedicle. Recovery. Pathological remarks: Lipoma.

Case 27 (Ninans, *Verein d. Aert. in Steiermark*, 1871).—Male, age 32. Prior history: Intermittent attacks of pain for months. Onset: Acute; pain and vomiting for eight days. Bowels: Constipation. Rectal examination: Blood on eighth day. Operation: Twenty-sixth day; discharge of slough. Recovery. Pathological remarks: Intestinal segment has lipomatous polyp; mild obstruction one year afterward; never well since.

Case 28 (Albrecht, *Peters. M. Woch.*, 1880, No. 9).—Male, age 51. Onset: Pain, followed by diarrhea. Rectal examination: Mucus and blood. Sixth week; discharge of pedunculated lipoma from large intestine.

Case 29 (Wallenberg, *Berl. klin. Woch.*, 1864, 437.)—Female, age 21. Prior history: History given under malignant growth. Discharge of lower ileum in connection with sarcoma of cecum.

Case 30 (Ludloff, *Grenz. Gebiet.*, 1898, 3, p. 600).—Male, age 29. Prior history: Severe colicky pains. Bowels: No stool; no flatus. Rectal examination: Prolapse; invagination at rectum. Distention and tenderness persistent. In a few days discharge of slough, with temporary relief followed by local abscess, which was opened. Recovery.

Case 31 (Balskow, *Monat. f. Unfall.*, 1905, p. 56).—Male, age 21. Prior history of trauma: Heavy lifting. Onset: Acute; pain and vomiting of six days' duration. Bowels: Constipation. Rectal examination: Mucus; blood on twelfth day. Rigidity and retracted abdomen; tenderness. Operation: Slough discharged on twenty-sixth day, consisting of ileum; cecum; ascending colon. Recovery.

Case 32 (Müller, *Strass. Med. Zeit.*, 1909, vi, 45-47).—Male, age 36. Onset: Sudden pain in right lower quadrant;

diagnosis, appendix. Bowels: Constipation. Rectal tenesmus. Distention moderate; tenderness general. Discharge of slough with Meckel's diverticulum on it, twenty-first day; probably ileocolic. Died two weeks later from perforative peritonitis.

Case 33 (Sohlern, *Mitth. aus d. Hamb. Staats,* Bd. x, No. ii).—Male, age 35. Prior history: Varicose veins five years ago, with operation. Onset: Acute; pain and vomiting. Bowels: After four days no stool or flatus. Rectal examination: Blood and mucus after tenth day, with foul stools. Tenderness general; no visible peristalsis. No tumor. Discharge of slough, twenty-ninth day, containing rusty darning needle; enteric. Recovery. Remarks: Obstruction one month later; operation; stricture near duodenum; death after resection.

Case 34 (Marnach, *Scot. M and S. Trans.,* 1906, p. 176-184).—Male, age 3. Onset: Pain. Rectal examination: Blood and mucus; tenesmus. Tumor: In left lower quadrant. Slough passed tenth day. Recovery. Remarks: Well four years after.

Case 35 (Sohlern, *Mitth. aus d. Hamb. Staats,* Bd. x, No. ii).—Male, age 18. Prior history: Passage of eighteen round worms failed to relieve pain. Onset: Pain. Tumor: Size of fist in and over centre of abdomen. Slough passed; 4 cm. enteric; 8 cm. colon. Recovery. Pathological remarks: Fifteen months after, death from obstruction, autopsy showing scars in cecum, splenic flexure and small intestine terminating by narrow orifice in ascending colon 16 cm. above cecum.

Case 36 (Kirchner, *Berl. k. W.,* 1886, No. 24)).—Infant. After discharge of slough, subsequent complete obliteration developed.

Case 37 (Wilson, *B. M. J.,* 1910, i, 375).—Male, age 45. Prior history of trauma: Lifting heavy weight; constipation. Onset: Acute; pain and vomiting. Bowels: Diarrhea and then normal stool. Rectal examination: Blood and mucus after twenty-four hours; rectum negative. Abdomen retracted; tenderness general. Tumor: None. Discharge of transverse colon one week after onset. Recovery.

Case 38 (Poisson, *Gaz. Med. de Nantes,* 1908, 25, 26, 336).—Female, age 23. Onset: Acute; vomiting and pains forty days ago. Rectal examination: Blood. Tumor: Below and to left of umbilicus. Discharge of slough on fifteenth day. Recovery. Pathological remarks: Early recurrence of obstruction; invagination three feet below pylorus; former invaginated segment makes angle with surface of mesentery; anastomosis between distended and collapsed coils. Recovery.

Case 39 (Kummer, *Strasb. Med. Zeit.,* 1908, v, p. 180).—Female, age 38. Onset: Acute obstructive symptoms. Bowels: Thin, watery stools, followed by complete obstruction for two weeks. (Original diagnosis of gallstones.) Discharge of slough on eighteenth day; enteric. Recovery. End result not stated.

Case 40 (Parker, *Surg. Gyn. and Obst.,* 1908, vii, 358).—Male, age 44. Prior history and onset: Six months continuous pain and vomiting, when he passed 12 inches of small intestine; relief for few weeks, followed by recurrence of symptoms. Operation: Irreducible; resection; lateral implantation; ileocecal. Recovery. Pathological remarks: Numerous polypi in intestine and a large one at apex of invagination.

Case 41 (Pullin, *B. M. J.,* 1896, i, 11).—Male, 79. Onset: Attacks of great abdominal pain with distention. Bowels: No flatus with enema. Tumor: To left of umbilicus. Slough passed thirteenth day. Recovery.

Case 42 (Laurent and Paley, *Bull. Anat.,* 1897, p. 488).—Female, age 33. Onset: Acute; pain and vomiting. Bowels: Constipation. Distention, rigidity and tenderness. Tumor in right lower quadrant. Slough of cecum and intestine passed on fifteenth day. Recovery. Recurrence of obstruction and death two weeks later.

Case 43 (Pedrazzini, *Gaz. d. Osp.,* 1897, No. 136).—Male, age 12. Onset: Complete obstruction for eight days. Operation: Passage of slough of small intestine eighth day; enteric. Recovery.

The first 21 cases are described by Raven (*Mitt. aus den Hamb. Staatskr,* Bd. x, Hft. 1). Other cases, also mentioned by Raven, and credited by him to Braun, Steinmeyer, Sandberg, Hirschsprung, Ayer, and Cipriano (*vide* Bibliography under Raven), could not be traced by the writer and are therefore not included in this paper.

DISCUSSION

Dr. L. L. McArthur (Chicago): I have been unduly greatly interested in this most excellent paper, and I should say that there is very little in the literature on this subject that has not been covered by it.

Since it was announced that I was to lead in this discussion, I have been away from home, and have not had much

time to look into the libraries myself with a view to familiarizing myself with the literature of the subject, and so I thought I would spend what little time I have for the discussion on the cause and diagnosis, simply suggesting to you, as has been suggested to me by the paper, that the causes in the adult are different from those in children, and that the intussusception in children depends upon inflammation of the bowel and the like, while in adults it is usually some adventitious growth. The matter of diagnosis was brought to me forcibly by one of the cases the doctor mentioned, and I believe I cannot do better in the way of discussion than to relate my difficulties in that particular case.

The patient was a young man, 25 years of age, the son of a doctor. I was called late one evening to see him, and not feeling very well at the time I requested my colleague, Dr. J. C. Stewart, to see him. It was an emergency case. It was supposed that he had appendicitis, as he had had a series of attacks. Dr. Stewart saw him, and said a diagnosis of appendicitis had been made repeatedly in this young man's case, but the symptoms did not tally with his disease. He was ordered sent to the hospital immediately with a view to operation, because the patient needed an operation for some condition inside the abdomen. In the course of an hour from the time he was sent to the hospital, I saw him. He was in collapse and suffering extreme agony, having been in that condition for a number of hours. He told me, as well as he could, that this was an attack of appendicitis, that his father and other physicians had attended him repeatedly, and that he always got better in a short time. Rigidity of the abdomen, as was mentioned by the essayist, was very well marked, but it was not like that of an appendix case. It was more marked on the right side, although the whole abdomen was somewhat rigid. It was the most rigid abdomen I have ever felt. It was as hard as a table. It seemed to be exaggerated over the right lower quadrant, and at this point the patient felt the most tenderness upon pressure. It was evident that there were serious conditions on the inside. I made no effort at a clear diagnosis, inasmuch as I intended to make one through the opening. I did then what I should not do now: I made a McBurney incision for my exploration. I found a congested swollen appendix which I removed, but which was evidently not the cause of the patient's suffering. Some serum escaped through the opening. Placing my fingers in the opening I could feel a distended viscus over toward the median line. I then closed the opening, and made an

incision through the median line, and found the distended gut, which was easily taken out through the opening, and proved to be an intussusception of the ileum into the cecum and the ascending colon. It had not existed very long, and it was easily reduced. Upon feeling along the ileum to see if it had sustained any injury from its confinement, I felt what seemed to be a foreign body on the inside. Upon examining it closely I saw a little indenture in the bowel, such as one might make with the point of a lead pencil, and upon closer examination I found this was the base of an inverted Meckel's diverticulum, which had been the cause of the intussusception.

The question naturally arises, What were the conditions in the young man's previous attacks? Did he have attacks of intussusception which were overcome, or were the symptoms pronounced appendicitis simply due to cramps and disturbances which we know sometimes are caused by Meckel's diverticulum without intussusception? I learned much from this case. The one thing that impressed me most was that it is never wise to be content with the first findings when the abdomen is opened. Had I been content to trust to the first findings in this operation my patient would have died.

In the earlier days all of us have removed appendices through a small opening, which gave us very little opportunity to make a general examination of the abdomen, and we left some serious lesions behind. Had I been content to remove the intussusception without careful examination as to the cause of the intussusception, the inverted diverticulum would have been left, and the man would surely have had a recurrence. The only symptom here that would be suggestive and helpful in diagnosis in the future was the great prostration of the patient accompanied by extensive rigidity of the abdominal wall. They do not correspond exactly with anything else I have ever met.

Dr. L. L. McArthur. (Chicago): I have been unduly complimented, because of the very small experience I have had with intussusception, in being asked to continue the discussion of this paper. Naturally, on being notified I would be expected to open the discussion or continue it, I consulted the literature, and I find Dr. Eliot has presented practically everything I have been able to find in my library. What one finds, however, in the library is not what we desire to contribute here, but the little grains of experience that each of us has had.

First, I never have had a case of intussusception in the

adult. It has always been in the child, and I was surprised both in reading and in being fortified by the doctor's statistics that less than twenty-five per cent of them were considered as occurring in the adult. I have had a single case of intussusception in a child, which was reducible, and which was reducible at the end of twenty hours from the onset of the symptoms. This case made a nice recovery, but caused me extreme anxiety because, after reducing it, I did not then know what procedure to use to prevent a recurrence. For weeks and months, after having reduced it, I was worried whenever I was called to that family, thinking I would have a repetition of the experience.

In reading in regard to intussusception, I found a suggestion which rather appeals to me, and which perhaps may come to your experience to utilize, namely, that in a case of intussusception in which the amount of bowel may be only eight or ten inches that has been intussuscepted, if wrapped in its own mesentery and stitched there, in this manner partly, or three-quarters, surrounded, as illustrated in the article by Dr. Coffey, it might do something to prevent a recurrence of such an intussusception.

A second case I operated on during the spring of this year at the Michael Reese Hospital after the fourth day of the attack. The child was four years of age, was in a desperate condition, and was about to die without operation. The pediatrician in attendance requested that I make an attempt to save the child. It proved to be an intussusception at the ileocecal region extending well into the transverse colon. The condition of the child was so desperate that I made an attempt to follow the recommendation of Dr. Richardson (we are fortunate enough to have him here), in making an anastomosis above and below the intussusception as quickly as possible, and then closing the child's abdomen. The child did not recover.

Dr. Maurice H. Richardson (Boston): I am very glad to know that Dr. McArthur carried out any recommendation that I made, but I have no recollection of ever having made it. I am sorry that the case terminated fatally.

There are three things with reference to this subject that interest me extremely: first, the tumor within the intestinal lumen as a cause of intussusception in adults; second, the possibility of spontaneous reduction, even when the intussusception is tightly jammed and apparently irreducible; and, third, multiple intussusceptions occurring in very young children.

A great many years ago—I think before most of the gentlemen present did much abdominal surgery—I made a diagnosis of intussusception in the case of a gentleman of 56 years of age. For many years, at intervals of a few months, this patient had had what the physician called simple colics. From the last attack he did not recover as usual. Symptoms of acute intestinal obstruction, with bloody stools, supervened. I found the typical sausage-shaped tumor in the region of the descending colon. Fitz and I agreed upon the diagnosis of intussusception. At operation I reduced, with considerable difficulty, the invagination, and found its cause to be a tumor about the size of a Bartlett pear that was attached by a circular base an inch or more in diameter. In previous attacks this pear-shaped tumor had evidently been grasped temporarily by the ascending colon, but had been released before it became jammed. The last attack, however, carried it past the critical point, and it was hopelessly forced far into the descending colon. Removal of the tumor was easy and satisfactory; but the patient was too far gone for recovery, and he died in twenty-four or forty-eight hours. In those days we hardly expected any success in these emergencies, but operated on the desperate chances. It was the old story, so often repeated since, of palliation and delay until there remained for operative surgery an almost hopeless outlook. But, I must admit, there was much greater excuse in those days, when operations so often failed, than there is now, when we know that early intervention means as invariable success as late then meant almost invariable failure.

In another instance I made, largely from my experience in the foregoing case, a diagnosis of tumor of the cecum, probably internal to the cecal wall. I advised exploration, with the possibility of intussusception distinctly in mind. The patient went home to think over my suggestion, was almost immediately overtaken by this very complication, and acute intussusception followed. Dr. Mixter operated with signal success.

These are the only cases of tumor that I have seen. I speak of them because I believe, as Dr. McArthur has said, that this is the place for each man to contribute his mite to a broad discussion of the subject. No one man can have very great experience in intussusception, because of the rarity of the disease. When each man brings forward his cases, we shall have a mass of data from which reasonable and trustworthy conclusions may be drawn.

A second topic which I should like to hear discussed, and which is not discussed frequently enough, is the treatment; for there is much that we must learn. A possible way out of a desperate emergency was once illustrated by a simple palliative operation. It was hardly conceivable, certainly not within reason, that a tightly wedged intussusception should become spontaneously reduced, but I have seen this reduction in an unquestionable case. In the amphitheatre of the Massachusetts General Hospital, before a large audience, I demonstrated, in the case of a child eleven or twelve years of age, an intussusception which I could not reduce bowel in hand. A colostomy was therefore performed, to tide the patient over the obstruction. The condition of the child was such that no radical operation was justifiable. She did well for a week or two, when she died of pneumonia. At the autopsy no trace of the intussuspection could be found: there had been a complete spontaneous reduction.

It is a common thing when a man reports an extraordinary case—a cure in a condition apparently incurable—for some to think that there has been an error of observation,—the unexpectedness, or apparent impossibility, of the good result being *prima facie* evidence of faulty observation. If, for example, anybody reports the cure of cancer by any of the non-operative methods, some one is likely to say that that very cure disproves the diagnosis of cancer. Such a course is, however, begging the question. It discourages a man from bringing any sort of evidence, no matter how strong; but in the case that I have just mentioned I have the evidence of the staff of the Massachusetts General Hospital, and of a large audience, that this was a case of intussusception, irreducible by me, at least. I have the evidence of an impartial pathologist, with his audience, that a colostomy above the intussuspection had been followed, in nine days, by complete reduction of the invagination, and this by means of the forces of Nature alone. If that is so, what better treatment have we in desperate cases than colostomy, trusting to the efforts of Nature gradually to squeeze back the invagination after the fecal stream has been entirely diverted from the intussusception? That a tightly impacted intussusception should become spontaneously reduced after the diversion of the proximal fecal stream, with its peristalsis jamming down upon the intussusception—that such an event should be likely enough to be relied upon after enterostomy, is unreasonable; but its possibility may be reckoned upon when, in desperate cases,

one is considering so dangerous a procedure as resection of the whole mass, or other prolonged and radical operation.

Another thing that I did not hear discussed was the numerous intussusceptions due to cholera infantum, which some of the text-books speak of as occurring in children. In the State Almshouse, in which there were a large number of children, I was called one summer to operate for intussusception. They had had several deaths there from cholera infantum, and in several cases multiple intussusceptions had been demonstrated at autopsy. One who had never seen such things in the acute diarrheal diseases of infancy would have said that they were easily reducible pathological intussusceptions. It seemed to me that they were physiologic, rather than pathologic, and of no clinical importance. When I was called to the next case, operation seemed entirely unnecessary. What the pathologist at autopsy had demonstrated were multiple invaginations caused by the violent peristalsis of cholera infantum. It is, of course, impossible of proof, but the theory seems to me a good one, that these multiple intussusceptions occur temporarily, and spontaneously disappear, varying with the renewed waves of peristalsis. Only those appear at autopsy which take place, as it were, in the agony of death.

I am very glad, indeed, to have heard Dr. Eliot's paper. As I say, I am sure that, while the experience of any one man does not amount to much, the total of many men's experience amounts to a good deal; indeed, there is nothing so telling as the mouth-to-mouth relation of experience in a scientific body like this.

Dr. James E. Moore, (Minneapolis, Minn.): Inasmuch as Dr. Richardson mentioned the treatment, I wish to say that I neglected to state that in my case I removed the Meckel's diverticulum, and the patient made a prompt and uneventful recovery, and has been in good health since, now about two years. Patient gave a history just a few weeks after the operation of having had an attack of cramps of uncertain character, but did not call in a physician, and soon recovered.

In examining this diverticulum there was nothing there to suggest the cause of its becoming inverted. It was one of those blunt diverticula about the size and shape of my thumb, and why it became inverted, and others do not, is beyond my comprehension.

Dr. W. W. Grant, (Denver, Colo.): The diagnosis of acute intussusception in children is not difficult to make, as a rule, because of the acute manifestations with mucus,

hemorrhage, and tumor. It occurs usually in the small intestine, the ileum, and the jejunum. So far as I know there is but one thing to do, and that is to operate and release the intestine as early as possible; if not, it will be impossible, usually, to remove the invagination, and some more difficult operation may be advisable and that of doubtful value.

Dr. George Ben Johnston, (Richmond, Va.): I was not fortunate enough to hear Dr. Eliot's paper, and therefore cannot speak to the subject that he presented. I have had the misfortune, I may say, to see a comparatively large number of cases of intussusception, particularly when we consider how rare this condition is.

The first case I ever saw in an adult occurred as far back as thirty years ago, and was treated for typhoid fever; and after the expiration of three weeks, sixteen inches of the small intestine was passed. This man made a perfect recovery and is well today.

I know of one other case similar to this which occurred in the practice of the late Dr. Davis, professor of anatomy in the University of Virginia, where he exhibited a specimen of twenty-four inches of the small intestine that had been passed.

One of the things which struck me in these cases is the difference between the behavior of intussusception. In some it was very, very acute, but in others it was not quite so acute, and these cases were not so violent in their symptoms.

Within the last four or five years I have seen three other cases of intussusception in adults, one occurring in a man, thirty years of age, who was sent to the hospital with a diagnosis of appendicitis. We found a large mass in the region of the cecum, but none of the symptoms were distinctly those of appendicitis, and after a careful study of the case we came to the conclusion that it was intussusception, and upon opening the abdomen we found the small intestine had been swallowed through the ileocecal valve, and there was a sausage-like tumor in the colon extending as far as the middle of the transverse colon. Nature had taken care of the invagination to a certain extent, so that there was complete union of the invaginated portion with the swallowed portion at the ileocecal valve. In this case we opened the colon, took out a large, long double section of the small intestine, as much as a foot in length, whipped over the cut edges and amputated a portion of the bowel, the anastomosis being made complete by Nature. This man made an excellent recovery.

More recently I have seen a case in an adolescent, a youth

of sixteen, who had been operated on for appendicitis without relief. The operation was performed a year ago. The attacks, which were supposed to be appendicitis, continued at varying intervals from two to four months, so that at the time I saw him he had as many as four attacks since the operation for the removal of the appendix. This patient remained in the hospital for a period of a month, in order that we might study deliberately the case and undertake to determine the nature of the trouble. We finally came to the conclusion that they were attacks of intussusception due to a tumor within the lumen of the bowel, and when the next attack came on we operated and found an invagination. The gut was largely distended. It was about the middle of the small intestine. No adhesions existed, so that the release of the intussusception was a very easy one, and when we had extricated the intussusception, running over the gut with the fingers, we found a tumor as large as an English walnut in the lumen of the gut. A small incision was made, the wall of the gut by the side of the tumor, which had a small pedicle, was turned out, and this was excised by removing an ellipse of the intestinal wall, and the opening was closed. This boy made an excellent recovery, and has since had no further attacks. We naturally expected a recurrence of the intussusception in this case on account of the deformity of the bowel, but up to this time none has occurred.

I have had two very remarkable experiences in the treatment of intussusceptions in children, and these two cases have led me to believe we should not refuse operation on any case of intussusception.

The grand-child of a prominent physician in a neighboring county to the city of Richmond, was taken with what was thought to be dysentery, and after a long time, three weeks, to be accurate, the child got what the grand-father thought was a prolapse of the bowel. He was brought to the hospital in Richmond, and I was called to see him. On examination I found as much as three inches of the large intestine protruding from the anus. The child's history was distinctly one of intussusception. We opened the abdomen of the child, and found five distinct intussusceptions, and these, fortunately, were released without a great deal of difficulty. None of them were so firmly adherent that they could not be unraveled, and this was done, and the child made an admirable recovery.

I operated on another child thirteen days after the first

symptoms of intussusception manifested themselves. In this case we got a good recovery.

These are unusual cases because, as a rule, intussusception terminates long before this period of time; yet I have seen other instances in which the intussusception existed for three or four days, where the gut was comparatively easily released and where recovery took place, so that, in view of the experiences which I have had, I think we are justified in attempting to release every case which comes under our observation.

Dr. Eliot (closing the discussion): The treatment of intussusception in adults, necessarily omitted on account of lack of time, is fully discussed in the latter part of the paper.

The serious and almost fatal complications of recurrence, to which Dr. McArthur has referred, occurs, especially after the reduction of intussusception in infants, and is best prevented with the least expenditure of time by the suture of the cecum, or that part of the intestine concerned in the invagination, to either the lateral or posterior parietal peritoneum. In five or six cases of intussusception treated in this way, no recurrence has taken place.

In regard to the palliative operation of enterostomy: It may be well to emphasize that this operation in children under one year of age is almost universally fatal. Several years ago a personal search of the literature disclosed but one instance of recovery in cases of this character. In adults, on the other hand, enterostomy is of occasional value in subacute and chronic intussusception, but in the acute variety, and especially after gangrene has developed, it should rarely, if ever, be performed.

The contrast between intussusception in infants and adults is in no place more striking than in the treatment. In infants the sole treatment which seems to be of avail is reduction. If reduction fails, the child dies. I found no instance, several years ago, of resection in an infant under one year of age for irreducible or gangrenous intussusception in which recovery occurred, and I doubt whether there are many such reported today. Children, and especially infants, rapidly succumb to the toxemia of obstruction, as well as to the associated shock, and do not usually survive long enough for gangrene and perforation to develop. In adults, on the other hand, the course of even an acute intussusception is more protracted, and in neglected cases death generally results from perforative peritonitis after gangrene of the intussuscepted gut has taken place. In the subacute and chronic varieties the condition may continue for months before the

terminal obstruction appears. Under such conditions resection of the affected part, whether gangrenous or irreducible, acute or chronic, is very much more likely to be successful than is the case with children, and in the tabulated list of patients treated in this way, although all cases of intussusception reported in the literature in the pre-antiseptic days are included, the mortality is less than 40 per cent. Moreover, the greater resistance in adults is shown by the fact that, although neglected cases usually result fatally, occasionally a spontaneous cure is effected by the discharge of the necrotic intussusceptum per rectum. At least sixty cases of this character in which the necrotic intussusceptum was discharged from the rectum from fourteen to twenty days after the onset of the intussusception, are reported in the literature, and, with a sole exception which occurred in a patient three years old, all of these patients were adults. In these cases of spontaneous cure, however, it seems well to emphasize the point that the cure is not usually permanent, and that secondary obstruction, due to the fact that Nature's anastomosis is insufficient, usually appears within a year or two afterward. This unfortunate complication can, however, be obviated by making a secondary anastomosis between the two segments of the bowel on either side of the original site of the intussusception several months after the discharge of the necrotic intussusceptum has taken place.

Mr. President, I want to thank you and the other members of this Association for your kind hospitality, and I appreciate the kindness you have shown me in inviting me to read this paper before this body.

INTESTINAL OBSTRUCTION DUE TO KINKS AND ADHESIONS OF THE TERMINAL ILEUM

Charles H. Mayo, M. D.

ROCHESTER, MINNESOTA

In addition to the list of reflex symptoms originating from the appendix, there are certain symptoms, caused by partial obstruction of the lower ileum, which somewhat resemble those of the stomach or intestine, but they are less severe and more chronic in character. We are all familiar with the marked stomach-reflex in obstruction of the small intestine, and experiments have shown how readily in this condition the small intestine reverses its peristalsis. We are also familiar, though to a less degree, with the marked reflex of the stomach in cases of cystic appendicitis and moving concretions of the appendix. It is quite apparent that the stomach is the center of the effect from many reflex sources of both the conscious and subconscious nervous system. To such an extent is this true that, approximately, only one individual in ten who complains of apparent serious stomach trouble ever has any real lesion of this organ.

In its development the mid-intestine consists of all the small intestine below the common duct and includes the cecum and appendix, as well as the ascending and part of the transverse colon. About ten inches of the ileum is pelvic, and originally it is fixed to the lower end of the cecum. This attachment, which is in addition to the opening into the cecum by lateral union, should, and usually does, become detached

about the period of birth, and when it does not, we have additional cause for obstruction. The ileum may have a comparatively short mesentery at its termination above the pelvic brim, and at times the cecum has a true mesentery, permitting a considerable range of motion.

For a number of years past, in dealing with intestinal stasis believed to be due to a diseased condition of the appendix, in which the seriousness, yet obscurity, of the symptoms, required a larger incision for exploration than was usually made for the removal of the appendix when it was unmistakably diseased and the symptoms more definite, we have, at times, noted a definite kink of the ileum within three inches of the ileocecal valve. However, the frequency with which the condition was seen in certain cases did not occur to us until a few years ago, when our attention was personally called to it by Arbuthnot Lane[1].

Arbuthnot Lane has undoubtedly had a most extensive experience in the surgical treatment of serious chronic constipation, and he believes that the adhesions found in the kink of the ileum and in the appendix have added to the obstruction and tended to the development of appendiceal concretions from retained fecal contents in the organ. He also believes that the condition is not necessarily inflammatory, but is the natural result of the tendency of the heavily loaded fluid contents of the cecum to descend to the pelvis owing to the erect position of man, and therefore the bands are developed in the lines of the force of traction. There are found a short and firm attachment of the lower ileum and an attached or short appendix with ptosis of the cecum. The ileum is rolled over and becomes adherent to the peritoneum beneath it.

Two years ago Jackson[2] reported certain cases of appendicitis showing at operation a veil of new-formed peritoneum over the cecum and ascending

Fig. 1.—A form of Lane kink with adhesions.

Fig. 2.—Lane kink after separation of the band and removal of the appendix.

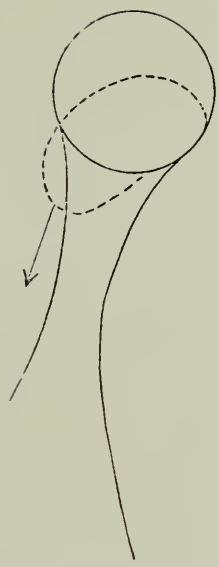

Fig. 3.—Form of narrowing of the ileum in kink (Lane).

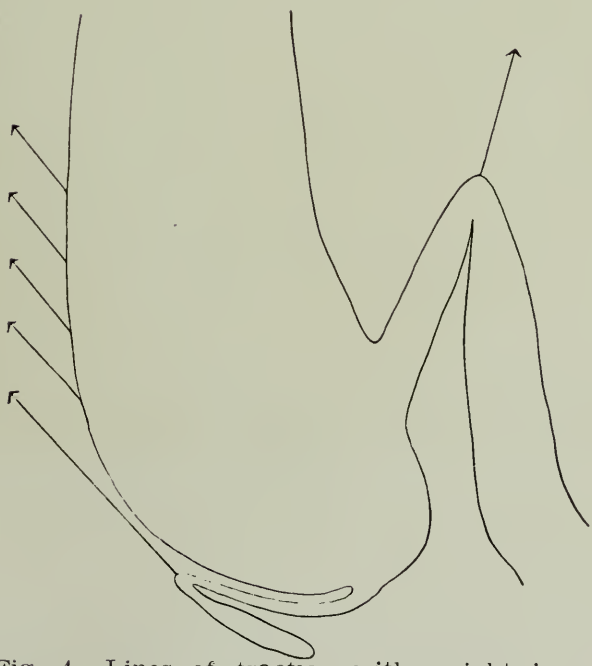

Fig. 4.—Lines of traction with weight in cecum (Lane).

colon. Jackson claimed that where this veil existed the patients were not often cured by the removal of the appendix, but that they could be cured by the removal, or partial removal, of this adventitious peritoneum. We believe that this condition is undoubtedly due to the late rotation of the bowel and the descent of the cecum from its hepatic position after the formation of the parietal portion of the peritoneal cavity in the infant. The cecum burrows its way into position, as it were, through the peritoneum. Such cases, however, are often found to show the bands of adhesions and narrowing of the ileum.

During the past two years we have observed many cases in which there was a definite kink of the ileum within a few inches of its termination. The ileum was rolled over and fixed upon the mesentery, evidently a condition of inflammatory origin. Sometimes these adhesions, with resulting bands of peritoneum causing a kink, appear to be a congenital development, because the condition has been reported existing in children without evidence of local inflammatory cause. It has been observed that when adhesions were present, or the peritoneal bands were greatly thickened, the appendix also showed chronic inflammation, which was apparently the source of the peritoneal thickening. The relief afforded by freeing the bowel of the adhesions indicates that this is undoubtedly a condition which has much to do with the ill health of the individual, even though the greater number of symptoms were not local but reflex in character, acting upon the stomach and intestines.

With the development of technic in surgery the risks of operation have gradually been eliminated, and considerations other than that of the mortality have become of marked importance, viz., morbidity and permanent cure.

Some twenty years ago surgery of the appendix was

confined to the treatment of grave and tangible lesions, such as draining abscesses. A little later on, the appendix was searched for and removed during operation for abscess, and still later the "interval" operation was developed, which not only prevented serious infection, but relieved these patients of the minor symptoms associated with a chronic catarrhal appendix. Operations upon the appendix became fixed within narrow limits. They were made through the smallest possible opening in the shortest possible time, with the least possible exposure of the intestine, and with no examination of organs other than the appendix. In rare instances the patient's failure to recover might later show that he had gall-stone, ureteral calculus, or even sacro-iliac disease, in addition to the diseased appendix.

Today the refinements of surgical methods demand a more careful examination of the abdomen in a larger percentage of operated cases, especially in those individuals who do not present well-marked clinical symptoms of the disease which is suspected.

The object of this brief paper is the earnest recommendation that the terminal four inches of the ileum be examined in all cases where it is convenient to do so when the abdomen is open, and especially should this be done when the condition of the appendix at operation (seen through a small incision) does not show sufficient change to account for the serious symptoms which demanded operative procedures.

It is not always possible to differentiate, clinically, the symptoms under consideration from those caused by disease of the appendix, as the conditions are so often associated. The region of the kink is usually tender, extending from the umbilicus downward to the right, while localized pain may also be obtained. The pain is increased by peristaltic activity, especially when caused by the activity of the individual. The intestinal

and gastric symptoms are often more marked at fairly regular periods after eating, and frequently there is a distension of the small intestine in evidence when the individual is fatigued. In some of these cases with the symptoms as outlined above, there are chronic constipation and also alternating constipation and colitis.

In the treatment it is essential to cut all confining bands, and prevent the formation of adhesions by adjusting the peritoneum with sutures. In some cases the application of sterile vaselin over the traumaticized peritoneal area, seems to prevent the development of deleterious adhesions following the operation.

REFERENCES

1. Arbuthnot Lane: "The Kink of the Ileum in Chronic Intestinal Stasis." James Nisbet & Co., Limited, London, 1910.
2. Jackson: Transactions of the Western Surgical and Gynecological Association, 1908.

DISCUSSION

Dr. Jabez N. Jackson, (Kansas City, Mo.): I am of the opinion that in the presentation of this paper by Dr. Mayo today, as well as the papers which have been presented by Mr. Lane, and the one which I had the pleasure of presenting before this Association a few years ago, we are approaching the consideration of a subject, or condition, of considerable frequency and to which little attention has been paid in the past, and about which we know very little at the present time.

Dr. Mayo has made one statement in his opening remarks which is important, and that is that we must recognize today the fact that gastric symptoms are not always, or even in the larger proportion of cases, indicative of disease of the stomach itself. It is curious how we have found by physiologic studies the interdependence and interrelationship of the different segments of the digestive tract. It is curious to observe that in almost any portion or area of the intestinal tract the initial symptoms or signs of disease confined to the mucous membrane are usually referred to the stomach. Take, for instance, cases of appendicitis. As long as we have a purely catarrhal appendix, the symptoms are absolutely gastric. The localized symptoms of pain, rigidity, and tenderness do not occur until the inflammation reaches such a de-

gree of severity that it extends through and involves the peritoneal covering. Likewise, as we know to-day, in gall-stones, which originally were only recognized after obstructive biliary colic and jaundice had appeared, we are now able frequently to diagnose from the mere existence of gastric symptoms. However, with the advent of the recognition of the appendix and the gall-bladder as focal lesions of many of these gastric troubles, we know that a great many operations for appendicitis and gall-stones were attended by practically no results. The experience with a number of these cases and the careful observations we have made have convinced us that the appendix is not the only organ which is responsible for the symptoms that resemble appendicitis or gastric disease. As a matter of fact, there is a very extensive line of conditions found, particularly about the right colon, which apparently have a pathologic origin independent of the appendix. These conditions are characterized clinically by the appearance of a membrane on the outside of the colon or intestine, moving freely over the underlying colon or peritoneum of the colon, and characterized by a large number of blood-vessels, which give a vascular appearance closely analogous to the injection of the blood-vessels of the eye in cases of acute conjunctivitis. This fact has led to an important surgical point, as Dr. Mayo has suggested, and unless we are able to make an absolute diagnosis of a limited lesion of the appendix, the small incision, which used to be so popular with us all, should be done away with. I remember very well the time when I used to talk about removing the appendix through an incision three-quarters of an inch in length, and leaving practically no scar; but I soon ceased making that small incision when I had experience with a few cases, not having seen the rest of the colon, and not knowing what was the matter. I believe the condition which Mr. Lane has described, and to which Dr. Mayo has alluded, and the condition which I have spoken of under the name of *membranous pericolitis,* belong to the same category. I must say, however, from personal experience, that I have never been able to confirm fully the observations of Mr. Lane. From his writings we are led to believe that the same conditions are found about the splenic flexure and about the descending colon and sigmoid. Since the observations of Mr. Lane were published, I have invariably taken the precaution, through a large incision for the purpose of exploration, to observe the left side of the abdomen, and so far my observations have shown pathological conditions confined entirely

to the right side of the abdomen. In most of these cases the trouble is mainly developed upon the ascending colon. The cecum is entirely free from it, and the appendix is free from it, except in those cases, as illustrated in the picture where the appendix runs to the outside of the cecum. Then it is covered by this fold of vascularized peritoneum which comes from the posterior and lateral abdominal wall. In the majority of cases I have not seen these kinks of the ileum which Dr. Mayo alludes to, but when present in my observations it has been usually a complication of the general condition, the extension of the membrane from the lateral aspect of the colon over onto the colon, usually terminating at the inner side of the longitudinal bands. In some instances, however, I have seen the membrane go clear over beyond the internal longitudinal band and onto the ileum, and produce this kink of the ileum, as Dr. Mayo has described. In one isolated observation, in which a diagnosis was made of pyloric obstruction, we found no obstruction to the pylorus, but the membrane ran from the hepatic flexure over across the peritoneum and to the jejunum, which was surrounded for about six inches by this vascular membrane. I have observed this membranous condition in a number of cases in which there were no symptoms to give rise to the suspicion of their presence. In the typical cases, however, when membrane is characteristic, it is attended by such a formation of fibrous tissue, with little blood-vessels running through it, that it produces mechanical obstruction in this part of the intestine. In fact, in one specimen exhibited before the Western Surgical Association last year by Dr. Hill, in my absence, after passing water through the ileocecal valve into the cecum, the cecum was distended as fully as possible without rupture, and yet not one single drop of water would pass the ascending colon and the hepatic flexure, showing that the membrane produced actual mechanical obstruction of the intestine. With the observation of these two different classes of cases, it is probable that this vascularized membrane begins originally from some trouble inside of the colon. When the membrane first develops it is purely vascular; it is the response to irritation on the inside of the intestine, and does not, in the beginning, produce any mechanical obstruction in the gut. If the case goes on long enough and the vascularity becomes chronic, we have the development of fibrous tissue, and it reaches a stage where it becomes one factor in the causation of mechanical obstruction.

There are many theories advanced as to the origin of the

peculiar condition that we have called membranous pericolitis. Some believe it to be a congenital condition; but against that theory we have the observation that, clinically, we have seen no case beginning under the age of twenty. All agree that sometimes it occurs in patients who are well advanced in years. Another theory is that it is due to peritonitis, with the formation of a vascular membrane from the outside. A third theory is, that it is due to a reaction from infection from within, producing a subperitoneal exudate with lifting and then revascularization of the peritoneum. I am frank to say, the more I see of these cases the less I know about the exact origin of them. In most instances it has seemed to me the condition is primarily due to a change in the mucous membrane of the gut.

In this connection I might mention the case of a patient who took large doses of bichloride of mercury, was poisoned, and died; and it was shown that there was no reaction whatsoever visible externally in any part of the stomach or the intestines, but the ascending colon and cecum showed almost complete gangrene. We also know that in this portion of the intestine very much absorption takes place, and we also know this portion of the intestine is that in which bacteria are most numerous. Suffice it to say, whatever our theory of it may be, the important fact is this: It is a condition which, when it exists, causes positive symptoms and suffering, and, as a rule, treatment that we have carried out in the past has been useless. For instance, to take out the appendix in these cases and leave the kink or angulation of the ileum is fruitless. To take out the appendix and leave a constricting band about the ascending colon is fruitless, and the question arises whether we can accomplish the desired object by simply extirpating the bands, as indicated in the Mayo diagram of the ileum, or as illustrated in the procedure I suggested of dissecting the attachment of the bands from the colon, or whether it will be necessary to do a radical operation of excising the affected portion of the intestinal canal, as suggested by Mr. Lane. Mr. Lane's teaching is extremely radical to most of us; but unless something such as we have suggested proves efficient, the method of Mr. Lane will be thoroughly justifiable, because these patients are not cured by medication, and are not cured by simply removal of the appendix or the gall-stones. It is certainly, in my judgment, one of the lesions of utmost importance and merits a searching investigation and surgical solution at the present time.

Dr. W. D. Haines, (Cincinnati, Ohio): For the past two

years in our work we have been looking for Longyear's ligament and for Dr. Jackson's ileocecal veil. The latter subject has interested me greatly from the time it was presented to this Association two years ago, and we have been looking faithfully for this condition since. We have found it, and I think we have done our patients a great deal of good in consequence. We had found in a number of instances this condition, or veil, the doctor has described, not knowing at the time that it was claimed to be an anatomic or pathologic entity. We have found in a great many instances a certain number of what we took to be adhesions, both on the outside of the colon attached to the mural peritoneum and the first two or three inches of the ileum. It was but recently, however, that we were rewarded in finding what I termed this veil extending two and one-half inches on the ileum and covering the entire appendix. This is the only instance in which I have found it since hearing Dr. Jackson's description.

I have read Mr. Lane's article on the subject, and think it tallies with what Dr. Jackson intends to convey. We had an experience that was very unpleasant, in that a man continued to have symptoms of appendicitis after his appendix had been removed. He came to us for re-operation. I asked the men who operated to be present at the second operation. At the previous operation the doctor had left an appendiceal stump an inch and a half long. He had just ligated it, cauterized it, dropped the stump, and went along. At first we thought the symptoms, as we have seen them in a number of instances, were due to this method of not removing the appendix, as the man had distress in the right iliac fossa, and as usual in such instances we finished the operation, that is, removed the stump. But I said to my assistant, "Do not forget Dr. Jackson's veil," and after investigation we were rewarded in finding it. I do not think, in the light of Dr. Jackson's remarks, it would be fair to charge the adhesions which we found extending out for probably an inch and a half or two inches along the bowel with having caused all the disturbance created by the chronic inflammation of the remaining appendiceal stump.

The short incision has served its purpose, and it must pass along and join the trend of other things we have discarded. If you are going to do anything, do something definite. When you are in a man's abdomen, attempt to demonstrate and remove the pathological condition. Do not open the abdomen and take out a small portion of his trouble and leave the greater part.

To do a causal operation, i. e., a complete operation, one must have the field of operation well in view; therefore make an incision long enough to demonstrate the presence, or absence, of pathological conditions, and deal with the pathological conditions to the best of your ability.

Dr. W. W. Grant, (Denver, Colo.): In this second operation, what did you do with the condition you found?

Dr. Haines: In the case I mentioned, we did an ordinary appendectomy, disregarding the operation that had been previously attempted. In the previous operation the surgeon had simply taken off the end of the appendix. In that instance we divided the veil of adhesions freely, and that is all we did in either of the cases. We dealt with them as you would deal with adhesions. The near future may demonstrate the absolute correctness of the radical position taken by Lane to deal with this condition the same as you would deal with a neoplasm by resection and lateral anastomosis.

Dr. F. A. Dunsmoor, (Minneapolis, Minn.): My experience in the last year with three cases has been such as to enable me to confirm the first point brought out in Dr. Mayo's paper. With the assistance of our pathologist we made an absolute diagnosis in these three cases of cancer of the stomach, on account of the entire absence of free hydrochloric acid, emaciation, and pain; and on making an incision for the cure of such trouble, as far as might be done, absolutely no pathological condition, except some atony of the stomach, could be found in any direction. As usual, we then extended the incision and tried to determine the pathological condition in another part of the intestinal canal, and more than once, when the diagnosis had not been absolute, we found a diseased appendix associated with the trouble, and removed it.

Now, I wish to add that I have been looking for the kink which Dr. Mayo has described, and also for the membrane which Dr. Jackson has told us about, and since my visit with Mr. Lane I offer this as an addition to the subject. Three times in the last two years I have made anastomosis of the ileum with the sigmoid flexure. In one of these I had to re-open the abdomen because the anastomosis became too narrow for some reason. Aside from that, those operations afforded relief, the trouble being due to chronic constipation and obstipation, which it is unnecessary for me to dilate upon. I have found the veil a number of times, that part which Dr. Jackson seemed to lay stress upon in

his first communication to this Association. When I heard his first paper it did not seem to me that this veil could possibly cause obstruction to the contents of the intestinal canal going through the colon, but three or four different times I slit this membrane and separated it because of the suggestions the doctor had given, but personally it did not seem to me that at any time this membrane or a kink in the bowel would cause absolute intestinal obstruction; yet it certainly did envelope the intestine from the mural side clear up the hepatic flexure of the ascending colon. I have found occasionally what I should imagine is an extension of the longitudinal band of the cecum, binding and covering in the entire appendix, so that it had to be split, and I imagine that is a part of the membrane, or the original part of it, which has been so completely described by Dr. Jackson.

With regard to the incision: An incision made along the semilunar line has been my favorite for two years at least, and I make it extensive enough so that I can easily explore not only the condition of the appendix, but the condition of everything within reach of the finger, and if the incision is two inches long I can explore all the contents of the pelvis, everything in the line of junction of the ileocecal region, and can touch at least the kidney, the liver, and the gall-bladder.

Dr. Jabez N. Jackson (Kansas City, Mo.): There is just one observation I would like to make incident to what has been said. The question was raised at the meeting of this Association before when I spoke of this membrane, as to whether in stripping it off we would not leave a large amount of raw surface which would give rise to recurrent adhesions. I rise at this time to say that I have since had opportunity to open the abdomens of two patients on whom I had previously operated for this pericolic membrane, and in neither instance was there any adhesion reformed.

Dr. Mayo (closing the discussion): There are three distinct conditions in connection with this subject. The veil of which Dr. Jackson speaks, may occur without appendicitis or the Lane kink. Certainly, we see cases of appendicitis without this veil and without the Lane kink, and we see the Lane kink without disease of the appendix and without the veil. In the process of development the large bowel begins on the left side of the spine and rotates across and around the mesentery of the small intestine. In the third and fourth months of fetal life it is under the stomach, and later it is

under the liver. A child may be two years of age before the cecum comes down into its fixed position. We find that in individuals with a late descent of the cecum after the parietal peritoneum is formed, the cecum must descend through an already developed peritoneum, and in that manner strips it up, works down through it, and we have the development of this veil, and the rolling under the appendix and the head of the cecum; and if it slides over this peritoneum the cecum develops a mesentery, therefore I think we may consider them separate conditions. We have operated upon some cases in which we considered the veil an important factor, binding the cecum down, and they were benefited. In the last two years we have seen a number of cases in which there was this rolling over, kinking and narrowing of the lumen of the ileum within the first two or three inches from the ileocecal valve. This is so marked that the ileum is much distended above, and in these cases constipation is sometimes a marked feature, that is irregular constipation, alternating with diarrhea; and we have increased peristalsis, which may act in producing reverse action of the small intestine and back toward the stomach again in which we have the stomach reflex. Again, it may empty itself rapidly into the cecum and start up a condition of increased peristalsis, which acts as colitis. We have seen a number of these cases that have been relieved by releasing the kink and adhesions.

PATHOLOGICAL CONDITIONS ARISING AS A RESULT OF MECKEL'S DIVERTICULUM

Byron B. Davis, M. D.

OMAHA, NEBRASKA

Judging from my own experience and the frequent reports in the literature a persisting vitello-intestinal duct is not as rare a condition as commonly believed. The great diversity of its points of attachment, length, and size gives variety to the pathological conditions to which it gives rise.

Attachment.—It seems almost always to be attached by one end to the ileum within about thirty-six inches of the ileo-cecal valve, but it may be at any point from the duodenum to the cecum. It may even not be attached to the gut at all, but to the mesentery, as in one of my cases. The other end is sometimes free of all attachments, floating about in the peritoneal cavity. Sometimes this free end forms an inflammatory adhesion to any of the viscera or to the abdominal or pelvic wall. In a recent case it had adhered to the bottom of Douglas' cul-de-sac, a small abscess being present, and an obstruction had been produced by dragging on the ileum. When the end distal to the ileum is primarily attached, it is most likely to be at or near the umbilicus, but may be attached to the omentum, to any part of the abdominal wall, or to the ascending colon.

Length.—Its length varies from one and one-half inches to several inches.

Size.—It may have a lumen and be as large as, or

even larger than, the ileum, or it may be a mere fibrous cord with a diameter no larger than that of a slate-pencil.

There can be no doubt that many persons live their lives and die with a persistent vitello-intestinal duct which is never discovered and has never been the cause of any unpleasant symptoms.

There seem to be three distinct pathological conditions caused by the unobliterated duct. The first is due to the lumen persisting through the entire duct, characterized by a fecal discharge from the umbilicus. Or it may persist at the umbilical extremity only, giving rise to the secretion of mucus, which discharges at the umbilicus.

The second condition which Meckel's diverticulum may produce, is pain, fever, and pus caused by its becoming infected. This is most likely to occur when the lumen is narrow or obliterated in whole or in part.

The third and probably the most frequent pathology caused by it is mechanical obstruction due to catching of a loop of intestine under the band or to a loop becoming entangled with the band in such a manner as to shut off the intestinal lumen at some point. Still another method of producing obstruction has been reported. It is when a comparatively short diverticulum with a free end becomes inverted into the lumen of the ileum; then dragging upon the wall it produces intussusception of the ileum. I have recently found two such cases in the literature. Rutherford Morison reports one of them, a boy of five years, on whom he operated, finding an intussusception caused by the complete inversion of a Meckel's 1½ inches in length.

In most cases reported and in my own experience diagnosis of the diverticulum is seldom made before operation. It may be suspected, but positive diagnosis in the very nature of things is almost impossible. In cases of mechanical ileus it can merely be thought of

as one of several possible causes of the obstruction. In infections of Meckel's diverticulum the pre-operative diagnosis usually made, is appendicitis. The symptoms and physical signs of the two diseases are practically identical, unless, as in my second case, the location of the abscess gives one a hint.

I have had one experience which shows that when one operates for appendicitis he should not consider the diagnosis fully confirmed unless a search is made for a Meckel's diverticulum, as well as for an inflamed appendix. In this case a boy of nine years, the son of a physician, had the typical history of an attack of appendicitis. The right abdominal muscles were rigid, and pronounced tenderness was present at McBurney's point. A small muscle-splitting incision was made, and an appendix which seemed to show a sufficiently pathological condition to explain his symptoms, was easily drawn through the wound and removed and the abdominal incision closed without any extended examination of the intestines. The boy apparently recovered and was taken home. The old symptoms soon recurred, and the father has recently written me that he has had another operation, and that an inflamed Meckel's diverticulum was found with the free end adherent in the pelvis. Such a case makes one wonder how zealous one's search should be in every case in which the abdomen is opened.

I wish, briefly, to place on record the cases of Meckel's diverticulum met with in my surgical practice. As will be noticed, they have produced most of the several pathological conditions to which this strange anomoly may be the cause.

Case 1.—About fifteen years ago a little girl was brought to me with a fecal discharge from the umbilicus. My records are lost, and many of the details are forgotten. An elliptical incision was made including the umbilicus, and a patent diverticulum communi-

cating with the ileum was ligated off and removed. The abdominal wound was closed, and the patient made a good recovery.

CASE 2.—Master H. R., aged seven years, schoolboy. Two weeks before entering Immanuel Hospital he began to have pain in the left side of the abdomen, the attack at first being accompanied by diarrhea and vomiting. Three days later he had a sticking pain in the region of the umbilicus for a few hours. This pain ceased for a week and returned, the pain now radiating to the lumbar region. When the pain came on the second time a mass was found in the abdomen in the umbilical region according to the history given by the mother.

When he entered the hospital his pulse was rapid and weak, his temperature varying from 99° to 101°, his thighs were flexed on the abdomen, which was very tender to the touch. A tender mass was found, almost circular in shape and about 4 inches in diameter, with center of mass corresponding to the umbilicus. There was dullness on percussion over the mass, with tympany and considerable distention over the rest of the abdomen.

The diagnosis made was between an appendiceal abscess and an infected Meckel's diverticulum. The location alone was all that caused me to think of a diverticulum.

Operation.—November 3, 1906. Dr. C. A. Hull assisted; Robertson gave the ether; students from the College of Medicine, University of Nebraska, were present. The abdomen was opened below the mass, in the median line. After loosening adhesions, the mass was found to be a continuation of a Meckel's diverticulum, connected to the ileum about fifteen inches from the ileocecal valve. Its lumen corresponded almost exactly with that of the ileum where it was attached. Its base was crushed with forceps, ligated,

and cut off, the stump being buried in the ileum by means of a purse-string suture. Next, enough of the abdominal wall was excised to enable us to remove the mass intact, and the abdominal wound was closed.

On examining the specimen, an abscess was found to occupy the segment attached to the abdominal wall. The gut portion which was connected with the ileum was three and one-half inches long and had a uniform lumen to its point of attachment to the abscess. Two or three ounces of pus were found, and this portion seemed to have had no communication with the iliac portion of the diverticulum. The intestines were greatly distended, but the condition seemed to be paralytic, rather than mechanical ileus.

The boy was very ill for several days, but made a perfect recovery, the bowels moving about twelve hours after the operation, following an enema.

Case 3.—Miss N. H., aged 26 years; dressmaker; referred by Dr. W. F. Stotler, Shenandoah, Iowa. She had pain in the right side for the past two years. The pain recurs frequently and lasts only a few hours. She often vomits at short intervals for two or three days at a time, the vomiting resembling that of an intestinal obstruction. As soon as the bowels move freely, vomiting and pain cease.

The diagnosis made before operation was recurrent appendicitis. On November 14, 1907, at Immanuel Hospital, Drs. Hull and Fossler assisting, and Dr. Stein giving ether, with her physician, Dr. Stotler, present, the abdomen was opened. At once a Meckel's diverticulum about three inches long was discovered, joined to the lower ileum and extending from there to a point of attachment on the abdominal wall one inch to the right of the median line and one and one-half inches below the level of the umbilicus. It ran directly through the great omentum and when drawn out left a small hole in the omentum. It was band-like, but

had a lumen for a short distance from the ilium. It was removed by double ligation. A long appendix, which seemed only slightly inflamed, was removed. A slight operation was also done on the pelvic organs. Recovery followed.

Whether this girl's symptoms were the result of appendicitis or the catching of a loop of intestine by the Meckel's band, has never been quite clear to me, but I have been inclined to the opinion that her vomiting was caused by temporary obstruction due to the diverticulum.

Case 4.—Miss E. E., aged 24 years; teacher. She entered Immanuel Hospital on December 27, 1909. For three years she has had recurring attacks of pain in the right lower quadrant. She reports six definite attacks with several slighter ones. The last attack was three weeks ago. She had no fever when she entered hospital. There was slight but definite tenderness at McBurney's point, with a little abdominal rigidity. Chronic recurrent appendicitis was the pre-operative diagnosis.

On December 28, she was operated on, with Dr. Prichard assisting and Dr. Myers giving ether. The McBurney incision was made and a thickened appendix removed. Just when ready to close the abdomen a band was noted, and on examination it was found to be connected with the ileum, low down, the other end being attached to the adbominal wall near the umbilicus. It was excised. There was no lumen. Recovery followed.

Case 5.—V. B., a little school-girl, aged ten years. She was brought to Immanuel Hospital by Dr. Montgomery of Stella, Nebraska. She had been taken suddenly with sharp abdominal pain two weeks before. For three or four days following the attack the bowel movements occurred, but for nine days there have been

no bowel movements. She has been vomiting more or less since, and has had some fever most of the time.

The examination at the hospital revealed an extreme degree of tympany and absence of peristalsis. The diagnosis of ileus was made, due to some unknown cause, but with suspicion directed to the appendix.

Immediate operation followed on November 1, 1910, with Drs. Hull and Scott assisting, Dr. Buol giving ether, and her physician, Dr. A. W. Montgomery, of Stella, present. Incision was made in the median line below the umbilicus. Loops of reddened and greatly distended bowels were present. The appendix was found to be normal. From the ileum, about four inches from the ileocecal valve, a short Meckel's diverticulum was found. It extended down into the pelvis where it was adherent and had perforated at the end, approximately one ounce of pus being found walled off. The diverticulum had a lumen almost as large as the ileum. It was tied off and removed, and the stump buried. From the traction on the bowel there seemed to have been produced a twist of the root of the mesentery, beneath the border of which a loop of strangulated bowel was found, which was almost gangrenous. It was held down by an adhesion of the border of the root of the mesentery. As soon as the adhesion was loosened, gas passed into and filled the collapsed loops. The loop of semigangrenous ileum was brought near the abdominal incision, covered over by a pad of gauze wrung out of hot normal salt solution, and the wound left open. A rubber tube was also inserted to the bottom of Douglas' cul-de-sac. The patient did not rally, and died about five hours after the operation.

The more facts learned about Meckel's diverticulum the clearer become the following conclusions:

First.—That in every case of obstruction of the bowels a Meckel's diverticulum should be considered as a possible cause of the ileus.

Second.—That no diagnosis of appendicitis or other intraperitoneal inflammation should be made until the possibility of an inflamed Meckel's diverticulum has been carefully considered.

Third.—That in abdominal sections, made for whatever cause, it would be well to examine for the presence of a Meckel's diverticulum before closing the incision.

DISCUSSION

Dr. Van Buren Knott (Sioux City, Iowa): It is not so long ago when we regarded obstruction from Meckel's diverticulum as a rare occurrence. Of recent years we know that this is comparatively common. When we stop to consider that Meckel's diverticulum occurs in from one to two per cent of all persons, we may readily see how a great many cases of obstruction may be due to this diverticulum.

The day I was asked to open the discussion upon this paper, one of the most interesting cases of this kind I have ever seen was brought into the hospital with a diagnosis of acute appendicitis. I was not able to verify the diagnosis of appendicitis, but I made a diagnosis of obstruction, operated upon the boy, and found that the obstruction was due to an adherent Meckel's diverticulum; but we also found an acute gangrenous appendix. The appendix was gangrenous with a large concretion in the tip. This case proved that a coincidence of this sort may happen and that we may have both conditions to deal with at once.

There are, undoubtedly, a great many cases in which obstruction is said to be due to Meckel's diverticulum, but in which the diverticulum is not responsible. There are certain fibrous cords which originate in the region of the ileocecal valve and run from there up to the mesentery which are not true diverticula, and I believe that unless it can be demonstrated that the tissues of this structure contain tissues which are the same as those of the ileum, we are not justified in calling these cords or small bands in particular diverticula.

I have nothing in particular to add to the subject. Dr. Davis has given us an interesting paper, and I am quite sure every one of you has had many of these cases of obstruction due to this cause. The advice I would give is to be careful that our diagnoses are exact, and not overlook some important condition within the abdominal cavity.

During the past year I have had two cases, both occurring in children who were very sick, in which obstruction persisted for some time. The condition did not permit of an extensive operation. Following the idea brought forth by Lillienthal of New York City in his experimental work upon the duodenum in two cases of obstruction due to Meckel's diverticulum, we have simply ligated the diverticulum close to the ileum, cut it off as you would the appendix, and cauterized the stump with carbolic acid, and dropped it. Both of these patients recovered.

In our surgical work we desire to simplify matters as much as possible, and if, in cases of this sort, ligation, with cauterization and dropping back, will do, it will save two or three minutes in suturing; and in cases of acute intestinal obstruction, it means a good deal to the patient. I believe during our operations within the abdomen, if we should happen to encounter a diverticulum which is not adherent, which has made no trouble, but which is two inches long or longer, it should be removed in order to avoid a possible occurrence in the future of intestinal obstruction.

I hardly see how it is possible to make a diagnosis of obstruction due to Meckel's diverticulum before operation. We have never made that diagnosis, and doubt whether we shall ever be able to do so. Of course, in these cases of acute obstruction of the intestine we can assume that Meckel's diverticulum may be the cause, and it is a good location in which to hunt for the obstruction and eliminate the possibility of a diverticulum being present before we commence to search in other portions of the abdomen.

Dr. Daniel N. Eisendrath (Chicago): Unfortunately, I could not be here during the reading of the paper, but Dr. Davis spoke to me about it yesterday afternoon. I have brought down two specimens which I think will be of interest to the members in connection with this paper. They are both specimens which show the pathological condition that can result from Meckel's diverticulum. Dr. Davis' original title of his paper was "Meckel's Ileus," but he told me afterwards it was more a case of inflammation of Meckel's diverticulum.

In the *Annals of Surgery* about a year ago I published this first case of inflammation somewhat similar to the case cited by Dr. Davis, in which there was not only inflammation of Meckel's diverticulum, but intestinal obstruction due to one of the forms of ileus that result from Meckel's diverticulum, namely, adhesions of this little terminal ligament, as it is

called, at the tip of the diverticulum to a portion of the mesentery adjacent to the diverticulum, and the slipping of two coils of intestine under the ring formed by the Meckel's diverticulum. That is the first specimen.

As to the second specimen: It is strange that within a short time I should run across two cases of that kind, but that is usually the rule in medicine. This specimen was taken from a boy of six years, whom I saw *in extremis.* The little patient had been seen by a physician in Chicago, Dr. Collins; but on account of some delay in notifying Dr. Collins that the bowels did not move, he did not see the patient more than an hour before I did. He saw the coils of intestines so that one could palpate the contour through the abdominal wall. The pulse was extremely rapid. All I attempted to do was to perform an enterostomy with the idea of affording temporary relief. When I opened the abdomen I encountered three pathological conditions. The Meckel's diverticulum, which was found, was taken out at autopsy, as the boy died within a few hours after the operation. This was an exceptional case to operate on. In the first place, it was an example of ileus in a diverticular ring. The terminal portion of the diverticulum was adherent to the mesentery, two coils of intestine having slipped under it, and it became obstructed. The second is a form of gangrene of Meckel's diverticulum. You can see a greenish-black condition of Meckel's diverticulum, and that was number two. Number three, you could still see at the base of Meckel's diverticulum two foreign bodies similar to those we found in the appendix. There were really five things. Number four was a stenosis mentioned by all writers on Meckel's ileus, which you can plainly see is due to the mesenteric vessels as they pass across. There was a distinct stenosis of the gut distal to the Meckel's diverticulum, due to a cicatricial contraction following obliteration of the mesenteric vessels which supply Meckel's diverticulum. Lastly, there was volvulus at this point, so that we had everything possible in the way of pathological conditions due to Meckel's diverticulum. I could not think of resection of the diverticulum, as that would mean resecting this portion of the gut. I made an artificial anus through the tip of the diverticulum, and not having seen a perforation at the time of the operation, I simply brought this up through the abdominal wall, but I found at the autopsy that we had a leakage at the base of the Meckel's diverticulum due to a perforation. This Meckel's divertic-

ulum was started in a typical place, about thirty inches away from the ileocecal valve.

I think this subject of inflammation of Meckel's diverticulum and ileus due to Meckel's diverticulum in its various forms, is one which is beginning to receive more and more recognition. I have seen within the last week a case of inflammation of Meckel's diverticulum, because the tenderness, rigidity, and tumefaction were located near the umbilicus, away from the appendiceal region. If you see these cases early enough, the inflammatory signs are not typically located over McBurney's area, but lie closer to the umbilicus.

Dr. A. E. Benjamin (Minneapolis, Minn.): I rise to report an interesting case which was similar to Dr. Davis' second case only so far as operation is concerned. The patient was a young man, about eighteen years of age, who had been sick twenty-four hours, and was sent to the hospital with a diagnosis of appendicitis. Not agreeing in that diagnosis made by the other physician, I decided to make a median incision, as the patient had acute symptoms of obstruction, with high temperature and rapid pulse. The abdomen was very much distended. I found a Meckel's diverticulum four inches in diameter, that is, the extreme end was four inches in diameter, adherent to the abdominal wall, and filled with grape seeds and fecal matter, and the proximal end very much occluded, so that there was obstruction present and a gangrenous area in that portion adherent to the abdominal wall. The appendix also was chronically inflamed. We removed it at the same time. I performed the operation similar to that which Dr. Davis performed in his second case. The man made a recovery. I have never seen or heard of a Meckel's diverticulum similar and of the size of this case, and that is the reason I report it.

THE SELECTION OF OPERATION FOR INGUINAL HERNIA

ARCHIBALD MACLAREN, M. D., AND HARRY P. RITCHIE, M. D.

ST. PAUL, MINNESOTA

This paper is founded upon the records of 105 anesthesias, showing 123 operations in 97 individuals. Eighteen cases were operated upon for double hernia. Two men and one woman returned for operation upon the opposite side from the original repair. Four men were re-operated on for relapse. Eighty-two opertions were on men and twenty-three on women.

By decades the ages are as follows:

1st, 4 males and 1 female.
2d, 16 males and 2 females.
3d, 28 males and 7 females.
4th, 17 males and 6 females.
5th, 6 males and 2 females.
6th, 5 males and 3 females.
7th, 3 males and 1 female.
8th, 3 males and 1 female.

It may be seen that the greater number appear during the period of active life. Many have worn trusses for several years and accept the operation because of the occurrence of new symptoms or the failure of the truss to retain the hernia. In the series there are very few of the extreme conditions, and our experience with grossly complicated hernia is limited. In this fact lies the reason that no extraordinary measures, such as filigree, flaps of the recti, etc., were found necessary to obtain a satisfactory repair.

There are but five cases in the first decade. This is not entirely from lack of opportunity. In large hospitals doing charitable work the operation may be routine. In private practice the child is under constant observation, and the necessity for the operation without the most positive indications is often questioned. A support is usually easily applied, and the child readily adapts itself to it. It is no odd experience to have the truss obliterate the sac, and when recurrence does come it will usually result in a less complicated form of hernia. The convalescence is more easily controlled, and, in fact, all conditions are more conductive to a favorable result. So far, we have yet to see or obtain a history of a strangulation of the inguinal hernia in the very young.

During the second decade and beyond, our advice is positive, as the presence of the hernia is then permanent. The exceptional cases in which a cure is obtained by injection or truss-pressure are very rare, and the permanency questioned. With men in industrial pursuits or in active life, and with patients of middle life with encarcerated or omental hernia or with symptoms of strangulation, the indications are positive; and in urging the operative repair our responsibility rests upon proper care and technic.

The patient who successfully controls his rupture, asks our advice. He is told of the dangers of strangulation and the permanency of the hernia without repair. It must be remembered, however, that this complication is only tentative, and in advising such a patient to operation our responsibilities are greatly increased.

Mortality.—Two deaths have occurred, both in strangulated hernia; one a case of four days' obstruction, and one an old man of 79, who, three weeks after operation, while sitting in bed, fell dead.

The total number of strangulations is eight. Three

of these were in the third decade and the remaining five in the sixth and seventh. Our experience now justifies us in assuring our patients of their recovery from the operation.

Accidents of the Operation.—The bladder was opened in one case, with recovery and clean wound. The vas was cut in a boy with a complicated congenital hernia. An attempt was made at repair; with what success is not known.

Complications of Convalescence.—General: In one case the cord was constricted and the testicle swollen, with recovery. Another developed a severe pneumococcus bronchitis, with recovery. One other showed a temperature of 103°, for two days, without wound inflammation, which was undetermined as to cause.

Local: Seven have notes of wound-infection, such as a "few drops of serum," "wound-infection, upper end of wound, etc." One case suffered a severe infection discharging sloughs and undergoing a tedious convalescence. This was a double herniotomy where the sides were repaired synchronously by two operators. The right healed primarily while the left was unclean. Since this experience the operators have always worn masks. All cases suffering an inflammation to any degree whatever are instructed particularly as to the possibility of recurrence, as such processes in any wound may nullify the strength of the union.

Other Operations.—The question of performing other operations at the same time as herniotomy is a frequent problem. The indefinite abdominal pain and distress is often the chief complaint, and when this occurs in a well controlled hernia it is well to remove the appendix. This has been done five times through a separate wound. Six years ago it was found that, by extending the incision in the external oblique high enough, a button-hole could be made approximating

the cross muscle opening, through which the appendix can be readily removed. This has been done in 21 cases. Often it may be reached through the sac itself. In one case a herniotomy and a cholecystectomy were done at the same time.

Double Herniotomy.—Two cases returned within a year, showing a hernia developed on the opposite side. Such occurrences suggest a careful examination for incomplete hernias, which only need the added abdominal pressure to make them definite. The cases of double herniotomy have as easy a convalescence, and there is no reason why the side opposite should not be investigated and the hernia in its inception cured.

Relapses.—The permanency of our work is the great question, for upon it lies the justification of advising our patients to submit to the operation. In women the problem of the disposition of the round ligament is unimportant in relation to the cure of hernia. Here the operation should be called a herniotomy, and is not to be placed to the credit or discredit of any of the well-known methods. When a relapse does occur it must be the result of some operative fault or complication of convalescence.

There is a record of six relapses. In 25 operations on females there are 2 recurrences; in 98 operations on males there are 4 returns; of these 98 operations there is listed, 1 Halstead with cure, 35 Bassini with 1 return, and 42 Ferguson with 3 returns. All such reports of success and failures are open to criticism, as there may be other failures of which there is no report made to us. But the above is probably correct, as we have had no general hospital service and the relationship between a private patient and his physician is certainly more intimate. Especially in the last few years the patients have been assured proper care if there appears any sign of relapse.

Operative Technic.—That employed has been along lines generally accepted and proven efficient in the hand of surgeons of wide experience. We have felt unjustified in attempting original or odd procedures, and we believe that high removal of the sac, expert approximation of tissue, gentle manipulation, a clean and a dry wound, are as essential to success as the use of the many accessory procedures. Of these that are in most constant use is the imbrication suggested by Dr. Andrews. In all cases absorbable material was used: kangaroo tendon, Ramsey County pyoktannin, and chromacized catgut; yet in these days of reliable sterilization, less returns may result from the use of a permanent suture.

Selection of Operation.—The great problem of repair is the disposition of the cord. The Halstead was performed in October, 1904. This patient, a young man, fired an engine for five years, and now sits at the throttle. Previous to 1905 there were two cases in which, from the description, the cord was not displaced, but in all others, 34 in number, a Bassini was done. At this time one relapse had been re-operated upon, but the remembrance of the technic of the first operation was such that the failure was ascribed to this, rather than to the principles of the operation. In this case the hernia returned at the internal oblique ring, and the conditions found were similar to the first operation. It was in 1905 that the operation for herniotomy was the most positive in surgery, and there was no need of change in technic. The high position of the internal oblique had been many times noticed, and the stitch above the cord used when indicated. Since our return, and others reported following the Bassini always occurred at the internal ring, it seemed plausible that, if this opening was closed, a cure was guaranteed.

The supporting facts and reports of successful re-

sults influenced us in the use of the Ferguson as a routine procedure, beginning in February, 1905, and ending in January, 1909. This was done 42 times with 3 returns which have been re-operated upon.

The first to appear was the man who suffered from the severe infection of the left wound. It was considered that the cause lay in this experience, and it was expected to find that many of the tissues had been destroyed and a large defect present. No such thing occurred. The external oblique fascia was present in its usual strength, and the external ring was definite and so solid that it felt as though the opening were made with a punch. The external oblique was perfectly united to Poupart's ligament just as it was originally placed. No sac of the hernia could be demonstrated, so the whole wound was re-dissected and the abdomen opened through a button-hole. By placing a gloved finger within, a sac could be pushed out through the most dependent part of Hesselbach's triangle, and displacing the cord outwards. When this was removed it was easily demonstrated that, if the tissue were replaced as before, this defect would be uncorrected, and there seemed to be no reason why the sac would not immediately recur. The only possible procedure was the use of the conjoined tendon and the displacement of the cord, thus performing a Bassini.

Within the last year two similar cases have returned, but with this added interest, that they had healed primarily at the first operation. In the re-dissection the tissues were found exactly as sutured, so that there seems to be no question of operative fault, but one of principle.

The percentage of our success as to displacement or non-displacement of the cord, is in favor of the former. It is unnecessary to mention the facts and reasons given in favor of one or the other operations,

more than to say that in our work it is constantly demonstrated that the most evident process in the formation of a hernia, is the shortening of the inguinal canal and the approximation of the openings. It is reasonable to consider that any measure which will over-correct this condition is most rational. The view of the formation of an entirely new kind of hernia, which comes without displacement of the cord and which we are powerless to prevent, has swung the pendulum back in favor of the Bassini, and our present feeling is that, if there is a recurrence from it, we will call it an operative fault and do it over again.

Such individual experience, however, must not be considered conclusive evidence against the Ferguson, and we still believe that the principles underlying the Ferguson are reasonable, and the arguments in its favor valid. We have many cases in which a severe test of the operation has been made and they are still perfect.

Would it be too ideal to suggest that in the future, by experience and observation, a surgeon may reach that stage of perfection where he may select the procedure best suited to the conditions found at the time of the operation; that, for the sliding hernia of the sigmoid, he employ all structures to support the most independent points and do a Halstead; when the fascia beneath the inguinal canal is attenuated that he do a Bassini; and when the lower structures of the canal are strong and the defect is high that a Ferguson be selected, thus dispensing with routine methods, and reach the goal of our endeavors, namely, a success in every case?

DISCUSSION

Dr. F. Gregory Connell (Oshkosh, Wis.): I can most heartily concur in the conclusion Dr. Ritchie has arrived at, that the probable reason for failure and recurrence after operation for inguinal hernia is due to the fact, as a rule, that all

herniæ of certain types have been treated by one or another method of operating, disregarding the extent of the anatomical changes that will have taken place in the particular hernia, instead of the details of the operative cure being governed by the findings at the dissection. Rather startling, very significant, and fundamental changes are being introduced into the hernia problem today. The congenital origin of all oblique inguinal herniæ is practically accepted, and now Mr. Murray of Liverpool, England, seems to have conclusively shown that femoral herniæ are likewise of congenital origin. This necessitates a change in the nomenclature of hernia and a discarding of the term *congenital* as it has previously been employed.

Another cause of confusion in the classification is the distinction between indirect, or oblique, and direct inguinal hernia. This is based upon the relative position of the deep epigastric vessels, but as these vessels may be depressed even to the pubic bone and in the latter location, the resultant hernia, while still anatomically indirect, or oblique, is to all practical purposes the same as a direct hernia. Therefore, as a basis for differentiation this can be of but questionable value.

It must be recognized that no one technic is practical in all cases of inguinal hernia, and the selection must be governed by the changes that are found at the dissection. An operation aiming at the radical cure of hernia must do two things: first, remove the cause, that is the sac. This must be done in *all* cases. In some it will be sufficient, and in others, alone, it will be of no avail. The second necessity is the replacement of the anatomical structures to their normal relations. I mean by that, the correction of the pathological changes that have been caused by the presence of the sac in the inguinal canal. In doing this, little or much will be required of the operation.

In the usual small hernia, the internal ring has been dilated and depressed. This will be made smaller and elevated by sutures at its lower margin. The internal oblique muscle will have been pushed upward by the sac, and this will be depressed so that it will act as muscular protection for the internal ring. The inguinal canal has been dilated. This will be taken up by imbrication of the anterior wall. The external ring may have been enlarged upward, and this will be rectified by sutures at its upper boundary. In the fortunately less common type, the larger, older, and in which a truss has been worn for some time, the internal ring is often

stretched beyond recognition, descends to the pubes, directly behind the external ring. In such cases the internal ring can not be repaired in a satisfactory manner, and some plastic operation that will create a new internal ring is called for, the rectus fascia or muscle usually being called upon to fill in the weak spot. The other details are the same as in the smaller variety of hernia.

In the Bassini operation a new internal ring is created by the transplantation of the cord. This effects a satisfactory new ring, but it does not allow the muscular internal oblique to act as a check or protection to the ring, which is of great importance, as is shown by the recurrence when it does take place, at the upper extremity of the wound through the internal ring.

It will be by a proper recognition and treatment of these three degrees of inguinal hernia (1), in which removal of the sac is all that is necessary; (2), in which the internal ring must be repaired and the anatomical relations reestablished; (3), in which a new internal ring must be formed, that we are to achieve still better results in the treatment of oblique, or indirect, inguinal hernia.

The direct should be classed, in reality is, with a ventral hernia and not cause confusion by being considered inguinal.

Dr. Ritchie (closing the discussion): It was with some degree of diffidence that we brought this contribution before such a distinguished body of surgeons as this, but we thought it was important for you to know our experience that without displacement of the cord a new form of hernia may result. The tendency, as Dr. Connell has said, is to do these operations in a routine manner. In the future advancement of our work we should try to differentiate conditions and meet their requirements in our operations.

THE PLICATION OF THE ANTERIOR FOLD OF THE BROAD LIGAMENT FOR RETRODISPLACEMENT OF THE UTERUS

A. W. Abbott, M. D.

MINNEAPOLIS, MINNESOTA

In August, 1908, while operating upon a case that had had the left tube and ovary removed I found that the left broad ligament was almost entirely absent. The round ligament also had been removed. After replacing the uterus I found that, by stretching the peritoneum at the site of the internal ring and suturing it to the uterus, I was able to hold the organ in good position. The result in this case was very satisfactory. This drew my attention to the broad ligament, rather than to the round ligament, as a means of holding the uterus forward.

At the next meeting of this Association Dr. Coffey, of Portland, read a very instructive paper recommending the plication of the anteriolateral fold of the peritoneum coupled with the shortening of the round ligament. This paper gave me more confidence in carrying out my first intention, that of utilizing the meso of the round ligament alone, instead of depending upon the round ligament itself in any way, for correcting retrodisplacements of the uterus.

Since the case cited I have operated upon 56 cases. Of these I have been able to follow 50, who report themselves as "well." Thirty-nine of these cases have been examined by me or by competent proxy. In

38 of the 39, or 97 per cent, the uterus remains in perfect position. The one failure was undoubtedly due to the dragging of a subsequently formed ovarian cyst. In 9 of these 38 successful cases the retroflexion was accompanied by prolapse, and the uterosacral folds were also shortened, the necessary plastic work upon the vagina and uterus having been done.

The technic of the operation is simple. Having completed any other necessary work in the abdomen, especially the shortening of the uterosacral folds when indicated, seize the round ligament midway with long forceps, draw it up so as to bring the meso distinct and smooth. With a short, curved, round-pointed needle, threaded with fine chromic gut, begin the suture well in front of the point of exit of the round ligament; then picking up at short intervals the peritoneum just below the round ligament, bring the needle out at a point where the upper limb, of the round-ligament fork, joins the uterus. Again pass the needle about one-half inch below the thread just inserted, tie both threads, and repeat the operation upon the opposite side. No further attention whatever is paid to the round ligament. After the sutures are tied it lies in a loop just back of the pleat. Some judgment is required in choosing the first point of entrance of the needle, as otherwise the tension may be too great.

At the end of six months, the shortest period I have had for observation, the round ligament resumes its normal appearance. There is no suggestion of a loop and no trace of the pleating of the meso. It may be that these changes take place in less time.

I prefer this method to any operation upon the round ligament itself, because it seems anatomically correct and does not put the burden upon a tissue not intended to bear such burden. Moreover it is simple, rapid, and, in my experience, more effectual than any

other method. My experience would indicate that there is less dragging pain afterwards than following any other operation for the purpose.

Your perfect familiarity with the anatomy and mechanism of the parts relieves me from any discussion of this portion of the subject. I will, however, recall to your minds a few facts which have a pertinent bearing:

1.—Muscle alone, nowhere in the body, acts as a permanent support.

2.—When muscle is made to so act, by shortening in any way, it eventually gets tired and gives out. Fascia alone has a permanent sustaining power, and the peritoneum has decidedly a fascial quality.

3.—The round ligament, so much used in correcting retrodisplacements, unless artificially shortened, never tends to draw the non-pregnant uterus forward. It is always found slack. The condition is just the same in a short time after the round ligaments have been previously shortened. In a comparatively brief time they become slack, as before the operation. Any of the numerous methods of shortening the round ligaments unquestionably do generally result successfully. This is not due, however, to continuous traction exerted by the round ligaments, but to the following factors in addition to the intrinsic tendency of the uterus to maintain its normal position:

a.—The resumption of the normal conformation and weight of the uterus.

b.—The resumption of the normal dimensions and tone of the peritoneum in the front and at the sides of the uterus.

The only objection to the operation is, that it involves the opening of the abdomen. But when we consider that, in the class of cases under discussion, the abdomen should be opened, in the great majority of instances, on account of adhesions, ovarian and

tubal disease, appendicitis, or some other abnormal condition, as well as for the retroflexion, this objection loses its force. Should this operation be preferred in a case of no co-existing abdominal or pelvic complications to the extra abdominal shortening of the round ligaments or to any of the vaginal methods for accomplishing the same end? My answer to this question would be, given symptoms sufficient to warrant interference at all and a surgeon who is familiar with abdominal surgery I would unhesitatingly say that this method is just as safe and much more rapid and certain of results, and especially that it is much less likely to be followed by those discomforts which are sure to trail behind any operation founded on a faulty anatomical basis.

DISCUSSION

Dr. Arnold Schwyzer (St. Paul, Minn.): Inasmuch as Dr. Abbott has confined himself to a description of the operation, we do not have to go into the numerous ways of dealing with retrodisplacements of the uterus. When I read the title of the paper I first thought it meant another operation, as recommended not long ago, the shortening or duplication of the anterior part of the lowermost part of the broad ligaments by the vaginal route by making a horizontal incision in front of the cervix, grasping what solid tissues one can get of the broad ligaments, and bringing them together in front of the cervix. That is a simple method in those cases in which we have at the same time a sagging down and a prolapse formation.

As to his operation which I have not done or seen done. There are a number of points which make us feel at once this is a commendable operation. The fact that the method has been recommended by Dr. Abbott and its simplicity are strong points in its favor. The picture shows us how easy the operation must be. We have no creation of abnormal pockets. Another point in its favor is this: Usually when we have a plication of the round ligament in the abdomen, we take the middle or anterior part of the round ligament and fix it to the fundus of the uterus somewhere, and in this way we hope to be able to stretch the anterior portion of the round ligament, which has been elongated before, and which

is more stretched by us. In Dr. Abbott's operation the round ligament is not kept in overtension as we have it when we fix it to the fundus of the uterus, but it is relaxed, and we know that the muscles will adapt themselves to the fixation-points. When they are near they will adapt themselves to an extensive degree. I should think that this suture would hold the uterus sufficiently in position. At the same time, instead of weakening the round ligament support, as in those cases where we stretch the anterior part of the round ligament, gradually the round ligaments may come to again, so that after a while the round ligaments would have a chance to slowly retract again.

Dr. Franklin H. Martin (Chicago): I did not expect to be called upon to discuss this paper, but I am, nevertheless, very much interested in the subject.

It took us a long time to discover that operations upon the uterus, so-called round-ligament operations, were really nothing but shortening of the peritoneum, and Coffey's work of two or three years ago emphasized the point that it was the peritoneum, instead of the round ligaments, that we had been utilizing all these years. All of us who did the old round-ligament operation by the Alexander route, found every little while our cases failed. They failed when we utilized only the round ligament. When we succeeded, in spite of ourselves, in drawing out the peritoneum so as to make it taut, practically rendering taut the anterior portion of the broad ligament, did we really get success. In every round-ligament operation that is done now we dwell upon the necessity of the round ligament, but almost invariably we include the peritoneum at the same time. Therefore we are really plicating the peritoneum every time we do a round-ligament operation. For instance, in the Baldy-Webster operation we drag through the broad ligaments the round ligament at a point an inch and a half in front of the uterus beneath the tube, and the utero-ovarian ligament, and with it we include the peritoneum. We then unite the round ligaments and the peritoneum, covering them together. The supporting power here, of course, resides in the peritoneum and the round ligament combined. Whenever the organs of the body are fixed from a loose condition in the embryonic state, they are fixed by blending of the peritoneum. When the ascending colon is fixed to the posterior parietes it is through the blending of its peritoneum or its early mesentery to the parietes before obliteration of the peritoneum, and as a result of this blending a fibrous fascial connection occurs.

This operation of Dr. Abbott emphasizes the point of the value of the peritoneum in operations for any kind of pexy.

Dr. Walter B. Dorsett (St. Louis, Mo.): It occurred to me, while Dr. Abbott was explaining the diagrams here, that possibly there might be some interference with the function of the bladder in this operation, inasmuch as a distended bladder would necessarily pull on the plication that was made. However, I would not say it does, because I know nothing about the operation. From the fact that this is a new operation, it demonstrates that the profession has not reached a perfect operation as yet. Personally, I have been doing for the past two or three years the Tod-Gilliam operation, and I want to say that I have been thoroughly satisfied. This operation is now almost routine with me, and I have had but one failure, and that was the first operation I did; and this failure was probably due to the fact that I did not thoroughly understand the technic.

I hardly think the statement made by Dr. Martin will hold good in its entirety, for the reason that the objection to the old ventrofixation or old ventrosuspension was due to the fact that the peritoneum pulled out, and so much so has that been the case that ventrosuspension and ventrofixation have been practically abandoned. The peritoneum often pulled out into a long cord, following which entanglement of the bowel occurred. If there was no suspension there was fixation, and Cesarean section had to be made in subsequent pregnancies for this reason. When you did a fixation, you did away with the peritoneum by sacrifying it to such an extent that the peritoneum did not enter into the fixation at all. It was connective tissue that came from under the peritoneum, whether it came from the connective tissue in the uterus.

I have not done one of these operations for a long time. In doing the Tod-Gilliam operation I bring the round ligament through a hole amply large to prevent any constriction of the fold of the round ligament, and then I stitch down the peritoneum, because if you enclose with the suture a great part of the round ligament you are apt to get a sloughing or necrosis and sometimes a pulling out.

Dr. W. W. Grant (Denver, Colo.): The pathological condition within the pelvis should and must determine the procedures adopted to correct these posterior displacements of the uterus. We cannot determine these accurately without opening the abdomen. The objection to the old Alexander-

Adams operation is that you know nothing, as a rule, about the conditions within the pelvis. Furthermore, there is the objection that it does not pull the uterus forward, but, rather, laterally. The vaginal operation for the correction of these deformities I hope will become obsolete. I think, as a rule, it is little done by American surgeons. But the shortening of the round ligaments internally should be the operation of choice. The Baldy operation does not seem to meet these conditions as perfectly as the Tod-Gilliam-Crossen or the Montgomery or Ferguson modification of the original operation. One point in the technic: Instruments are devised for the purpose of going beneath the fascia recti and pushing through the peritoneum, taking up the round ligament and pulling it through forcibly. I have seen the round ligament torn by skillful surgeons in doing this operation in this way. My own method is perhaps not new to some of you at least, but I invariably pick up the round ligament, put a coarse silk ligature around it, taking a smooth curved forceps, smaller point than usual, carrying it to the outer border of the muscle, or through the muscle, and catching the silk ligature, spreading the forceps enough to make sure of stretching the peritoneum, to bring it in without constriction, pulling the round ligament through by the silk ligature rather than grasping the ligament with an instrument; and in this way you do not contuse and bruise the round ligament in pulling it forward and stitching with a small linen or chromacized catgut in the middle line and to the edge of the fascia, closing the peritoneum and closing the fascia over it. I have never yet seen in my own practice—and I have been doing this operation for five years—any unpleasant results. Some of the women operated upon have borne children since, and it holds the uterus forward perfectly. If adhesions exist you can break them up. This operation, with the slight modifications, is to my mind distinctly the operation of choice.

Dr. Abbott (closing the discussion): I wish merely to say that this operation does not interfere with the bladder in any way whatever. There are no bladder symptoms following its performance. Dr. Coffey's idea is the one I adopted. There is no question about that, and I wish to give him full credit for it. The only difference is, I do not pay any attention whatever to the round ligament except to simply keep it out of the way, while Dr. Coffey includes the round ligaments in his sutures. This is the difference between this operation and all the round-ligament operations. If the uterus is

placed in position, under ordinary circumstances there is very little force required to keep it there.

This operation seems to be the better one as it answers the same purpose, and takes much less time than any of the round-ligament operations.

ABDOMINAL EXCLUSION OF THE FUNDUS IN COMPLETE PROCIDENTIA

Joseph Rilus Eastman, M. D.

INDIANAPOLIS, INDIANA

The question of whether the uterus in its normal state is suspended by its ligaments, and thus secured in a position, or is supported or upheld by the muscles and fasciæ of the pelvic floor, the ligaments serving only as guides, becomes, in the presence of complete procidentia, a question of lessened importance, for, in these extreme cases, hysterectomy, or the abdominal operation with fixation, is absolutely necessary in addition to a thorough repair of the vaginal supports with amputation of the elongated portio vaginalis and curettage.

In cases of third degree descensus, with protrusion of the bladder-floor and part of the rectum, separation and elevation of the bladder after Schauta or Goffe, with attachment of the viscus at a higher point on the floundering, sunken uterus, is to little purpose, and if not followed in complete procedentia by abdominal fixation is usually as ineffective as an attempt to lift one's self by one's boot straps.

There is certainly no department of surgery in which care in the selection of the operative procedure to be employed in the particular case, is of greater importance. No doubt, as many failures in the treatment of uterine prolapsus are ascribable to error in the selection of the operative method as to faulty technic. In any case repair of the diastasis of the levatores ani, as earnestly advocated by Barret and

Jewett, and the restoration of the conjoined tendon of the pubococcygei, can hardly be omitted. Likewise curettage and amputation of the elongated portio vaginalis apply to any comprehensive procedure which does not include a hysterectomy. The field of large differences is entered when the manner of sustaining the uterus itself in its normal level and positional relation, is considered. It is here that the choice of the proper step for the particular case in hand is an absolute need. It is evident to any man of any experience in this surgery that no procedure will fit all cases.

Cystohysteropexy, interposition, and ligament-operations—all doubtless have their usefulness, but in extreme complete procidentia, with general relaxation of ligaments, fasciæ, and muscles, they do not often suffice, in my experience, to correct the dysuria and the dragging pains. In these cases it is not often possible, by making a perineorrhaphy, oval anterior denundation of Sims, restoring the fascia after Webster, and elevating the bladder floor after Schauta, to successfully protect against the collection of residual urine and the appearance of desquamative cystitis, as observed and described by Kolischer.

In a small personal experience with hysterectomy and union of the ends of the broad ligaments, dysuria and dragging pains have persisted, and it has seemed better that the uterus had been left in to the end that I might have something to attach firmly and permanently to the abdominal wall, thus to support the bladder and the rectum. In one instance the persistence of residual urine in the bladder, the "fond" of which still presented folds, caused straining so violent as to spoil the result of the operation in every essential detail.

Carstens, who hysterectomizes procidentia cases asks. "Of what use is the uterus if left?" In many

cases if the uterus be left it has a use, and this usefulness rests in the circumstance that the uterus, through its attachments, may serve as a means of support to the other pelvic viscera after abdominal fixation. I have heard ventral fixation called a crime. Perhaps it is before the menopause, yet by drawing the folds out of the bladder-trigone and re-establishing the inclination of the normal bladder-base toward the internal meatus, trigonitis and dysuria, unchanged by previous plastic operations for the correction of the cystocele, have been relieved.

The fixation here referred to is not a classical one by which the fundus is sutured to the abdominal aponeurosis, but one in which the uterine fundus is drawn quite through the abdominal wound, the entire fundus being excluded and secured with a transfixing pin eight inches long and of one-eighth inch diameter, the ends of which rest upon the skin lateral to the wound. The pin is allowed to remain in place for two and one-half weeks.

It is not a rare experience to find, a few months after a simple fixation, the abdominal wall sunken in at the site of fixation and the prolapsus returning. Occasionally a well intentioned fixation gives way entirely. In extreme procidentia the sagging bladder cannot be held at its normal level by an ordinary fixation. These are the cases in which Baldy, for example, makes a supravaginal hysterectomy and permanent fixation of the stump by means of two silk-worm-gut sutures carried through the whole thickness of the cervical stump and buried on the fascia of the abdominal wall. He says that in two or three such cases after performing this operation the patient has returned with the prolapsus reproduced in part. He then made a complete and total hysterectomy, a sufficient amputation of the vaginal vault, a closure of the vaginal mucous membrane, and a fixation of the

vaginal vault to the abdominal wall as close to the pubic bone as possible.

I have the impression that recurrence in such a case may be due to ligament-formation at the site of the fixation, and owe this impression to the discovery of elongated, fibrous, ligamentous attachments to the abdominal wall of the cervix stump fixed ventrally years ago after Bantock's supravaginal hysterectomy, with extra-peritoneal fixation and abdominal exclusion of the stump.

In excluding the fundus in cases of complete procidentia, the aim has been to fix the uterus higher than can be done by an ordinary fixation, to provide for firm attachment of the peritoneum, muscles, and aponeurosis at a low level upon the anterior and posterior aspects of the uterine body. All of the layers of the abdominal coverings are drawn snugly around the uterine body and sutured to that organ anteriorly, posteriorly, and laterally.

The transfixing pin in the three cases operated on has been passed deeply enough to exclude the entire fundus. The large pin, an old-fashioned Bantock's "skewer" for extraperitoneal cervix-stump fixation, does not mutilate as do sutures. It does not tend to cut out as do silk or silkworm gut. It is perhaps barbarous in appearance, but does not lacerate or produce discomfort.

Two patients thus operated on, though they were past fifty years of age, had not passed the menopause, and in one of these the uterine appendages were removed and in the other the tubes were divided, and the peritoneal screen suggested by Reis interposed. In all three cases the abdominal operation was preceded by curettage, amputation of the portio vaginalis, anterior and posterior colporraphy, and perineorraphy.

The results in these cases have been better than I have been able to obtain in similar cases by other

methods. There has been no post-operative dysuria, no residual urine, and no return of the prolapsus uteri.

In each case the fundus has been covered over with skin, growing centrally from the periphery within two or three weeks. Owing to the firmness of the attachment and the elevation given by the transfixing pin, the possibility of sagging or detachment is minimized. The method offers the greatest possible uterine surface for fixation in the abdominal coverings. It makes possible reduction of deformities caused by extreme relaxation as a simple intra-abdominal fixation could not do, for the reason that the uterus is drawn higher, and the firmer fixation prevents a yielding ligamentous fixation or a complete sundering of the attached structures and accident, which is perhaps less rare than is imagined.

A possible advantage of abdominal exclusion over intramural sequestration, as practised by Philander Harris, rests in the fact that the uterus is permitted to maintain more nearly normal positional relations with the other pelvic viscera.

DISCUSSION

Dr. W. D. Haines (Cincinnati, Ohio): I have had no experience with this operation. The Secretary asked me a few days ago, in consequence of the illness of Dr. Oviatt, who was designated to open the discussion, to speak upon the subject. I hurriedly glanced through the literature, and the only thing I could find fitting the doctor's title was the description of an operation devised by Dr. Crile of Cleveland, which is described in Mumford's recent work on surgery. The operation described therein is similar to that described by Dr. Eastman, with this difference: he doubly ligates the ovarian, divides the upper margin of the broad ligament on either side, just as you would do preparatory to doing a hysterectomy, and brings up the fundus of the uterus similar to the way the doctor brings it, but makes use of the little tags of the broad ligament for fixation to the aponeurosis. These are about the steps in the so-called Crile operation.

Personally, I have been doing hysterectomy for prolapsus in elderly women, treating these cases as you would treat a

hernia, trying to divide the anterior cul-de-sac about as high as I could, and then bringing the posterior part of the vaginal stump up to this portion. Now, we would, of course, bring the round ligaments above that preliminary to doing this; in other words, make a complete closure below, getting the vaginal stump as high as possible from the pubic bone. We have been doing this operation for three years following the lead of Cullen of Baltimore, Dr. William J. Mayo, of Rochester, Minnesota, and one or two other men whose names I do not just now recall. We have probably accomplished more by draining the bladder to get rid of the bladder symptoms.

I have tried the Tod-Gilliam method, and various other methods of suspending uteri, with total failure.

I feel very kindly disposed toward the operation Dr. Eastman has described, and as the best has not been any too satisfactory with me in doing complete hysterectomy, I shall be pleased to adopt this method at some future time.

Dr. A. W. Abbott (Minneapolis, Minn.): We have two great classes of women who have prolapse of the uterus: those who have not borne children, yet are in the child-bearing age, and those who are too old to have children. That puts a different complexion upon the cases. I am sure we would not want to do anything that would prevent a woman from having children if she is of the right age. That is, I presume, the doctor's intention in this paper, namely, to apply the operation to those women who are too old to have children, if nothing else can be done.

The most grateful letter I ever received from a patient I got the other day from a woman on whom I operated for this condition a little over a year ago. The following is the technic of the operation: The vagina is made smaller, going clear back to the uterus and taking up the fascia of the recto-vaginal wall so as to make a better columnar support there. Those of you who have taken hold of the anterior lip of the cervix with bullet forceps and pushed the cervix backward into its normal position have seen the cystocele and rectocele disappear entirely. For that reason, in these cases of women who are in the child-bearing age, after doing whatever is necessary to make the vaginal support as good as possible, I make a thorough plication of the so-called utero-sacral fold of the peritoneum. That draws the cervix backward, just as if you pushed it back with the bullet forceps. I have recorded in my paper nine of those cases, and they were all cases of complete prolapse of the uterus, so that the vesical and rectal walls were down, and they all report

themselves in good condition. I have examined all of them. In one the result has not been just as I would desire. She thinks she is all right, but anatomically she is not. There is some falling forward of the cervix. Taking the cases where women have passed the child-bearing age, Dr. Eastman's operation should be a very effective and serviceable one.

Dr. Jabez N. Jackson (Kansas City, Mo.): There is just one point I would like to call attention to. The doctor spoke of difficulty with the incomplete drainage of the bladder. Some years ago, when I began to study surgery, as an illustration, in repair of the perineum an extensive so-called posterior colporrhaphy used to be made, in which a large portion of the mucous membrane over the rectocele was removed, requiring intricate plastic work to construct the new perineum. Nowadays, on the contrary, in the proper anatomical repair of the perineum we do not remove the excessive mucous membrane. When the perineum is torn and the muscles give way, we have the formation of a rectocele. Instead of cutting away the excessive mucous membrane, which has nothing to do with it, if we make anatomcial restoration, so that the levator muscles are brought together and the perineal fascia is also separately sutured, which is an important point brought out by Dr. Hill of Kansas City and which deserves great emphasis, we get better results. We never now suture the perineum in mass as we were told to do in the old days when likewise we used through-and-through stitches in abdominal work, but we pay close attention to accurate coaptation of the muscles and the fascia.

Dr. Hill called attention to the importance of bringing the fascia in front of the muscle and thus restoring the pelvic diaphragm, so that the mucous membrane drops in behind this wall and the rectocele disappears. After noticing the effect of that change, the idea occurred to me that probably cystocele can be explained in a measure on the same ground; that frequently the anterior perineal fascia is torn through, and we have nothing to support the bladder and it prolapses. In the same way we have the beginning of a cystocele, with no support from below to guard against it.

Five years ago I devised for experimental purposes this little idea: Instead of going back underneath the bladder into the vaginal wall, and doing the customary vaginal denudation we make an incision just beneath the urethra on either side down to the mucous membrane. Dissecting back until the fascia is exposed, we then bring the fascia from each

side together in the median line, thus forming an anterior diaphragm. With that little triangular denudation, when the fascia is brought together and the mucous membrane is excised, a firm fascial diaphragm is made. The cystocele now immediately disappears, and you have therefore made a diaphragm on which the bladder rests from below, instead of having yanked it up by the suspension of the uterus. This little point in technic has proved of value to me, although it is intended only to supplement the rest of the doctor's suggestions.

Dr. M. L. Harris (Chicago): It does not make much difference as to the degree of the prolapse of the uterus, whether it be the first degree or complete procidentia. If the cervix and the upper part of the vagina be restored to the hollow of the sacrum, the prolapse is cured, and all the accessory conditions—cystocele, vaginocele, rectocele, and so forth. Of course it is necessary to correct and repair lacerations of the perineum and the pelvic floor, but the essential point in the correction of all prolapses is to restore the cervix and upper portion of the vagina to the hollow of the sacrum. The various operations which have been done on the uterosacral ligaments have been practically failures because they stretch out again, for in these cases of prolapse there is no structure but peritoneum in these ligaments and that yields. To correct these conditions, I have devised an operation, which I described a few months ago, of utilizing the psoas parvus muscle as the living support to the cervix and to the upper portion of the vagina, taking the psoas parvus muscle on each side and passing the tendons underneath the iliac vessels, and sewing them in the posterior surface of the uterus or the posterior fornix of the vagina. The uterus and vagina are held backward and upward into the hollow of the sacrum where they belong and the cystocele disappears, the prolapse disappears. They are held there permanently by a living active support. Now, the fundus is easily taken care of if the cervix has been restored to the hollow of the sacrum. Any of the round-ligament operations will correct the fundus; all you have to do is to hold that forward, and that can be easily done if the cervix is held backward. The most essential part of the operation for prolapse in my opinion is to restore the cervix to the hollow of the sacrum, and I believe that the use of the psoas parvus muscle, or in its absence the psoas magnus, holding the cervix and vagina in this position, will correct all of these cases. I think those operations that turn the fundus into the vagina and put it outside

the person's body are not surgical. I cannot see why we should do such surgical operations when the condition can be corrected without them. In addition to this operation I always repair the perineum. That has to be done naturally, and some operation on the round ligament is necessary to keep the fundus forward.

Dr. W. W. Grant (Denver, Colo.): I have been hoping that we could hear from Dr. Murphy on this particular occasion and subject. The supravaginal amputation of the uterus derives its chief support from the fact that in many cases it can be utilized to prevent or cure existing rectocele and cystocele. This can be done in many cases by fixing some part of the round and broad ligaments between the anteroposterior flaps of the uterus, which we utilize in this operation, preserving some of the muscular tissue of the uterus. In this way many of these cases do admirably; but in the cases under consideration of procidentia uteri, as described by Dr. Eastman, usually in women past the child-bearing period, we have the condition in women who are frequently on their feet, working women, in whom none of the ordinary operations have succeeded. I have seen Dr. Murphy comparatively recently do an operation in such cases as this, which struck me as being the most absolutely certain of any I have ever seen. He brings the uterus out very much as Dr. Eastman has described, divides the round ligament and the tubes down to the point of even tying the cervical artery, then refixes the divided broad ligament to the lower segment of the uterus, brings the fundus without the abdomen, fixes it to the peritoneum all around and to the fascia, and then does what I have not seen or heard of before, divides the fundus anteroposteriorly and laterally, completely dissecting the mucous membrane, turning the four flaps back on the fascia of the recti muscles, suturing them, and closing the skin and cellular tissue over this part of the uterus,—over what is left of it,—making four segments. It seems to me, if any operation could hold, this would. I do not know how frequently Dr. Murphy has done this, but it certainly seems to me to be feasible and desirable in this particular class of cases.

Dr. John B. Murphy (Chicago): I have been very much interested in the operation which has been described by Dr. Eastman. It seems a simpler plan than mine. But with reference to the analysis of the supports which carry the weight of the uterus, as illustrated in these drawings, I wish to say that the first step in descensus is made by changing the posi-

tion of the cervix forward, as emphasized by Dr. Harris. Then comes a gradual sliding downward and outward. The cases to which Dr. Eastman has applied this treatment were those of procidentia of the superlative degree, and most of us have had trouble with this class of cases. We have been endeavoring to find some means to carry not only the weight of the uterus, but also the intra-abdominal pressure, which is continuous, on the bladder and rectum. The upper fold of the vagina and the bladder are attached at the cervicocorporal junction to the side of the uterus, in front at the vesicouterine fold, and the posterior wall of the vagina and rectum are attached behind. If you take this central or pivotal attachment and lift it upward, you draw up the slack in the vagina, rectum, and bladder. The difficulty has been to find some means of holding it up. Dr. Eastman's suggestion of exclusion of the fundus and sustaining it with these pins until it becomes one inelastic and continuous support to the anterior aponeurosis of the recti on both sides, when it is put in position and becomes united to the uterus, is an excellent one and should hold permanently. It is a simpler procedure than the one I use. In the latter you draw the central attachment up to the level of the rectus abdominis; you detach the broad ligament on both sides down to the cervicocorporal junction and ligate the distal stumps; then split the uterus parallel to the long axis of the body down to the cervix and cut out the mucosa of the tubes and uterus down to the cervical level; sew the two halves of the uterus crosswise over the rectus muscle; make the Pfannensteil incision down to the aponeuroses of the recti first; then split the rectus muscle parallel to its long axis; and sew the cutaneous flap back over the bisected fundus. This method of fixation drains the bladder perfectly, but I believe the Eastman operation will accomplish the same results with a simpler technic. I sincerely hope that this plan will give us as firm a fixation to the anterior abdominal wall as we all know was obtained when the *serra neud* was used in performing abdominal hysterectomy. The traction from this fixation gave one of the disagreeable symptoms following hysterectomy by this latter method which Dr. Eastman's father played such an important rôle in rectifying. Support is needed where there is elongation and a flaccid condition in all these walls, a condition uniformly present and in the superlative degree in procidentia.

Dr. Eastman (closing the discussion): Of course, we can-

not say that Dr. Harris' technic will not yield good results, because only time can determine that, but I doubt whether he puts the uterus in a more nearly normal position than it is put when the fundus is fixed in the abdominal coverings firmly.

Now, in trying sincerely to practice the technic of Webster in restoring the fascia supporting the bladder, and trying hard to elevate it after Goffe and Schauta, I have not been able to relieve the trigone of its folds, and it has seemed to me a matter of just common sense to be the right thing to take the bladder floor and lift the back part of it, so that it will "shed water." As a matter of fact, the patients thus operated on do not complain of dysuria, and they do not have residual urine. I do not know how you can get support for the bladder by attaching it to the uterus, sunken and floundering in the pelvis. It seems to me like a man trying to lift himself by the straps of his boots. We must attach to something that is firm and permanent, and we cannot always pull out all the kinks and folds of the bladder-floor unless we pull out the uterus through the abdominal wound and fix it higher than one can with a simple abdominal fixation.

The technic I have suggested is so simple that I hesitated to present it to such a distinguished body of surgeons, because I feared it might be condemned because of its gross simplicity. It is, however, I believe, of practical usefulness.

LESIONS OF THE HIP-JOINT AND THEIR MANAGEMENT

John B. Murphy, M. D.

CHICAGO, ILLINOIS

I wish to speak to you this afternoon of a few elements in connection with lesions of the hip-joint which play an important part in the final results obtained in fractures. When you look at the specimen from which this chart is made, and when you look at the chart itself you will ask yourselves the question, Where is the neck? When you look at this chart (indicating), you will ask yourselves, Where is the major portion of the neck? and when you look at this other chart you will see the neck is there to a great extent. Why in one case and not in both? In our recent work in attaching the upper end of the femur frequently we found definite conditions occurring. These conditions have been mentioned in older works, but the reason or explanation for it has been, in my opinion, wrong. What has happened to the neck in this case (indicating)? It is not there. There is no such absorption in fractures in any other position of the body. That never occurs when you have a fracture in the upper end of the humerus, as indicated here in another chart. There is no absorption. It is due, I believe, to a primary circulatory condition in the neck, and when you look at and study the neck with the blood-vessels attached here, and which pass into the neck, it would appear as though they all passed into the head; but this is not the case. They pass in and pass out. Then, when you look at them here (indicating), you see the direction

of the vessels is in the opposite direction, outward instead of inward. Now, when we have a lesion or a disease, the repair of the lesion depends more upon the condition of the circulation in the neighborhood than on any other one thing, taking into account always the regenerative potency of the individual structure. In the fractures that occur close to the head there is practically no absorption at all. There is no fatty degeneration, no breaking down, no liquefaction of bone. Where a fracture occurs at this point (indicating), carries off the blood-vessels and takes away the capsule,—in these cases we find the upper portion is left and comes between them and leaves the capsule attached. What has happened to the distance from the point where this fracture took place, and why the shortened neck? It disappeared seven weeks afterward. It was a soft, pulpy mass. This line drawn from the tip of the trochanter major to the tip of the trochanter minor shows great absorption had taken place between here and there (indicating), the upper portion was dead, and there was strangulation of the ligamentum teres. (Look over the text-books on surgery.) These (indicating) are pictures of a fracture close to the base of the neck, and in its attachment to the trochanter it does not tear off the blood-vessels in the capsule inside. That capsule, as you remember, goes down and out in the direction (indicating), and the blood-vessels go in a proximal and distal direction, but the bone from that point to there (indicating) in a great percentage of cases is absorbed.

The next question which arises is this: When you have a lesion there, such as a fracture, what must you expect as a result of the treatment of these fractures? You put on extension. The fragments are put in apposition, and are kept in apposition for five or six or seven weeks. The limbs, when measured, are practically right, but when you take off the extension at

the end of two weeks or later, you find that shortening has taken place, and it is just what is to be expected. Why? Because you have to take into consideration the element of time that is necessary for the absorption to take place and its removal, before you can get regeneration in the living portion of the head; and in all these cases of nailed fractures you will notice that where the fracture has been close to the head there has been absorption out to the level of the trochanter. If you have a fracture, however, that is clear out in the neck so as not to tear that off (indicating), then the portion between the trochanter and the head remains, and is capable of revascularization,—it is capable of reossification, and of regeneration. It is capable of sustaining the neck. Let us suppose we have tuberculosis occurring here in the neighborhood just to the outer side of the epiphyseal line. Here is one of the places where tuberculosis occurs, throwing the epiphyseal line into the head.

Tuberculosis of the neck of the femur is much more rare than tuberculosis that occurs in the head and surface and in the synovial membrane of the femur, differing from the conditions in the knee and in the lower end of the femur and upper end of the tibia. When tuberculosis begins here, it has the least possible means of support. It begins to pass around here (indicating) and shuts off the circulation from the head, and finally absorption and dislocation occur, and the tuberculous process passes out into the joint. If we are to have this condition, with defective circulation, we must take into account that the distal portion of the proximal fragment, unless broken close to the individual lesion, is going to be absorbed, except where it is broken away down here near the trochanter (indicating), and every skiagram I have taken shows that absorption has taken place. Sufficient time must be given for absorption to take place before organic

union can begin. Not only must these fragments be kept in apposition, but they must be kept in apposition for a longer period of time than is the usual custom, in order to allow this absorption to take place.

With reference to the manner of maintaining the fragments in apposition, there are a few elements from a practical standpoint that should be considered. In the management of fractures of the femur, I am sorry to say, these fractures in the past have been dressed with a straight external splint. What does that do? The tendency is to cause shortening by shortening the adductors, shortening the gluteal group of muscles attached to the trochanter, and, not only that, there is a tendency on the part of the adductors to draw the limb inward. Should we allow it to become shortened in that position? No. What we wish to do is to reduce to a minimum contraction during the process of absorption of this portion of the head, so that when absorption has taken place and the tissues are ready for regeneration we have no contact here. Some one in New York, whose name I cannot at present recall, suggested that in the treatment of fractures in the upper end of the femur. An important principle in the management of fractures is that you must keep the fragments in apposition, but how can you best do that by relaxing the group of muscles which tend so much to shorten? With extension applied, turning the neck of the upper fragment outward against the end of the lower fragment and putting into effect all of the adductor group of muscles in drawing inward against the head and dressing it, and not by putting a binder over the hips, which has no effect at all, but by applying extension and maintaining the fragments in apposition.

In the management of lesions of this type, particularly tuberculosis, because it is the great lesion in the hip, the present method is to treat these cases with

ambulatory splints and permit the patient to go about. In tuberculosis of the upper end of the femur, in a large percentage of cases the lesion occurs on the upper surface, anteroposteriorly, and only in a small percentage of the cases on the inferior surface.

I want to show you the condition of a patient who came into my office yesterday. It is typical of what looks like tuberculosis. First, this patient sustained a trauma, and following the trauma he began to have a little pain, which was located behind the trochanter, but he walked remarkably well. Why did he walk well? Let me show you a skiagram and the extent of the lesion. Why did he walk so well? Because the lesion was situated where pressure in walking did not affect it, and I merely mention this to emphasize what I wish to say with reference to the ambulatory splint. The joint is apparently normal until you come to a certain pain. When I abducted his leg and made rotation, immediately he had intense pain because the pressure was placed on the seat of the lesion.

The ambulatory management of lesions of the hip-joint—and I speak specifically of tuberculosis of the head of the femur—is wrong. In the first place, what is an ambulatory apparatus put on for? To prevent motion. So far as it inhibits motion in a joint, it is valuable. But what should it be applied for? To prevent pressure on the inflamed part. Whenever we have an inflamed surface, if the products of infection are held under tension, what happens? Rapid destruction of tissue. It is the same law that governs and controls destruction of the tissue in every position of the body, but I emphasize the hip because it is in the hip where it is so difficult to put on an ambulatory splint. There is one thing that glues the parts, and that is a good heavy Buck's extension. In the management of these cases, unless you keep pressure off of the inflamed surfaces, you are only partially doing

the work by immobilization, and absorption takes place—luxation takes place in the hip, as in any place else, just because you have an enormous musculature contracting under pressure, and because you have a peculiar type of circulation which favors the destruction of tissue.

In tuberculosis of the hip-joint I believe that our first and main principle should be to separate these articular surfaces by puting on an extension apparatus, one that separates, and not one that pretends to separate, and then build the patient up, after these articular surfaces are separated, by stimulating the process of repair.

(Dr. Murphy then showed photographs of cases on which he had operated, illustrating the principles of treatment he had so briefly enunciated.)

DISCUSSION

Dr. Alexander Hugh Ferguson (Chicago): I was delighted with Dr. Murphy's paper, for the reason that hip-joint disease and the rectification thereof are interesting to me, and his line of work has been running essentially the same as my own, except that he has had a more extensive experience.

Eighteen years ago a patient came to me with five inches and a half of shortening of the right leg, which was due to tuberculosis sicca in the hip-joint of twenty-five years' standing. He was treated by Sir William Fergusson, of London, with splints, and also by an orthopedic surgeon (Smith) in New York by splints. The entire head and neck were absorbed by pressure. It was the most extensive absorption of bone at the upper end of the femur that I have ever witnessed. The trochanter major was on a level with the crest of the ilium, and almost protruding. I cut down and removed a rim from both tables of the great wing of the os innominatum and jammed the part of the upper end of the femur with the trochanter major right into the new socket and brought all of the muscular structures on top of it. That man is now in Vancouver, B. C., able to walk with a cane, without discomfort, and free from pain. I mention this operation for two reasons, namely, to emphasize the absorp-

tion which Dr. Murphy has brought out, and certain rectification of it when it is so extreme.

Since the x-ray has come into vogue, of course we have had a great addition to our resources, because it enables us to make an early and accurate diagnosis. Since I have been using the x-ray with a view of ascertaining all I could about bone lesions, I have not used any splints whatever, doing nothing but injecting the joint, washing it out, etc. Since 1887 I have been using the injection treatment of iodoform and glycerine (10 per cent) emulsion in those cases, taking care not to use more than an ounce in an adult, and I have had exceedingly good results. I have had absolute cures in those cases where the tuberculosis was limited to the synovial membrane.

I do not need to explain the method of injection and so on, in your presence. There is one little point in connection with the technic that I might mention, however, and that is, after the injection you must insert a drain of silkworm gut through the cannula. If you do not do that the patient will have a great deal of pain. The injection has more or less influence upon the kidney, consequently you must not use too much at a time, nor too often, otherwise you will get smoky urine, and so on. With Beck's paste we have a substitute for the iodoform emulsion, but it is dangerous to use it except where we have a sinus.

I have a patient with tuberculosis of both knees and ankles. I injected the right knee with Beck's paste and the left knee-with iodoform and glycerin emulsion, and while the patient had symptoms of bismuth poisoning he got over it. Three months later he returned, and I used only two drams (thirty per cent) of Beck's paste in the left ankle-joint, and he had symptoms of bismuth poisoning again. I mention this to show that there is great danger connected with the use of Beck's paste.

I am glad Dr. Murphy has brought out very clearly the practical point not to put splints on in these cases. In a case of fracture of the hip-joint in a woman of sixty-five, and also in one of sixty-two, which I treated not long ago I followed Ruth's method with the swing and putting the leg out in this position (indicating). In addition to that I nailed the fragments. It is difficult to nail these fragments properly when the leg is extended and abducted. In fact, I used it roughly. I disengaged it instead of gently manipulating it, and then I got it out into this position (indicating), and nailed it there,—held it there for a month or more,—and at

the end of six weeks or so you can let these patients go around with the nail in there. There are some cases in which we must remove the head of the bone where there is so much absorption, so that you get only a spindle-neck and insignificant head, particularly in people who could not stand the long treatment of opening the bone and packing it, which takes longer than the removal of the head, so as to allow the patient to get about. You can do an excision in a few minutes, making Barkers' anterior incision and getting down into the head at once, and with dissector saw it across and turn it out. One can do that operation inside of ten minutes, and it shortens the treatment of any case.

I operated on a man from Denver five years ago, and he has perfect use of the limb, but, of course, has shortening.

In the younger people the nail treatment is better than the use of ivory pegs. I have one case in which I used the ivory peg eight months ago. The ivory peg is undergoing softening, or doubtless giving way when the patient is walking about, and he is getting some deformity. These patients are less liable to have deformity where you use nails instead of ivory pegs.

I think the old chronic cases that come to us with a gap in the neck, and in which some absorption has taken place, and there is an inch and a half of shortening, do better if left alone, particularly old people. In those who can stand the operation I would really favor it. We cannot break up the bones easily, but we can make an osteotomy, straighten the limb, and then bend it. Ruth maintains that by this abduction and slight flexion, and so on, we get union in these old cases after a time, but I must say I have not been so fortunate in getting union in the old cases.

Dr. E. M. Sala (Rock Island, Ill.): I do not care to discuss the paper of Dr. Murphy, but I want to report two cases of intracapsular fracture treated with ambulatory splints. I understand that Dr. Murphy's remarks had reference particularly to the ambulatory treatment of tuberculosis of the hip, and he objected to this method of treatment on that ground, but I have a case of my own I wish to report, as well as the case of another practitioner, in which the ambulatory splint was used. One was a woman, sixty-eight years of age, and another a woman over eighty, both of whom got very good limbs and very good union. The case I had was the most comfortable case of fracture I have ever attended in an old person. We were able to help her about the bed, and I believe we should have lost her were it not for the application

of the ambulatory splint. I have no interest in the ambulatory splint except to indorse it as a humane substitute for the usual treatment of fractures of the hip-joint, especially in old people.

TYPHOIDAL CHOLECYSTITIS

John E. Summers, M. D.

OMAHA, NEBRASKA

Although it had been known for many years that inflammation of the gall-bladder might complicate typhoid fever, it was not until 1890 that Gilbert and Girode proved, bacteriologically, that cholecystitis was caused in certain cases by the typhoid bacillus. Cushing demonstrated, bacteriologically, the presence of the typhoid bacillus in a case of cholecystitis where there was no antecedent history of typhoid fever. Most observers are now of the opinion that the typhoid bacillus in the gall-bladder; other bacilli may present in the gall-bladder in every case of typhoid fever. In the majority of cases the presence of these bacilli is not clinically recognizable, in others a mild, sub-acute, or perforative cholecystitis may develop during the course of an attack of typhoid; or a more or less chronic, remittent cholecystitis may follow, at intervals of months or years, after an attack of typhoid fever. These early and late attacks of cholecystitis are not all, of course, due to the presence of the typhoid bacillus in the gall-bladder, other bacilli may be responsible for the infection. There may or may not be gall-stones.

Much discussion has taken place as to the mode of invasion of the gall-bladder by the typhoid bacilli. Chiari says that the route of infection is not by ascension from the intestinal tract. Chariolanza's experiments seem to demonstrate this. After intravenous infection of rabbits with the typhoid bacilli, although the cystic duct had previously been ligated, the typhoid

bacilli found their way into the gall-bladder through its capillaries. Chiari's theory of gall-bladder infection by the typhoid bacillus is, first, the intestine, thence the blood, and then the gall-bladder. He also believes that, as a result of inflammation, the bile is converted into a medium for the growth of the bacilli. (W. Loele, "Deutsche Med. Wochenschrift.") Kohlbrugge's investigations ascertained that the empty small intestine in animals,—rabbits, guinea-pigs, moles, and calves,—is sterile. In man, however, it is not so easy to clear up this point, since, in a very few hours after death, the colon bacillus may be found in the whole intestinal tract. All theories and experiments to the contrary, one must ever bear in mind the possibility of direct infection of the gall-bladder through its connection with the duodenum. Forster says that the invasion of the typhoid bacillus occurs through the throat; they multiply in the tissues of the body, enter the gall-tracts and gall-bladder through the liver bile, and from thence are found in the intestine.

Apart from the cholecystitis which the typhoid bacilli may excite, it has become well established that many people who have had typhoid, carry around in their bodies typhoid bacilli, which for several months, and in rarer cases for years, are discharged from their bowels as a menace to those who, by any means, might become subject to infection from such evacuation. It has been suggested that possibly the bacilli may have their habitat in a diverticulum of the lower small bowel or in one or more diverticula sometimes found near the ampulla of Vater. The late Robert Koch estimated that about 5 per cent of typhoid fever patients become such a menace; 2.5 per cent carry bacilli for three or four months; 2.5 per cent longer; and some for years.

The percentage of cases of ulceration and perfor-

ation of the gall-bladder in typhoid fever cannot be estimated. It must vary somewhat with the specific epidemics.

Both Thomas and Ashhurst (*Progressive Medicine,* Vol. XI, No. 1) have studied carefully the subject of perforation of the gall-bladder as a complication of typhoid cholecystitis, the former collected from the literature 154 cases of cholecystitis in typhoid fever. Of this number perforation of the gall-bladder occurred in 39; eleven were operated upon, with a mortality of 5.46 per cent; all the others died. Ashhurst collected 21 cases in which operations were done upon the gall-bladder during an attack of typhoid fever. Thirteen died; and of these, four were not conclusively demonstrated until after death; in 11 bacteriological examinations demonstrated the typhoid bacillus in pure cultures; the colon bacilli and typhoid bacilli were found in one, and in another the paracolon bacilli only.

The absolute relationship of the typhoid bacillus to gall-stones has not been determined. This bacillus eventually plays its rôle, as others do, in the formation of gall-stones. As a result of the work of Pettenkoffer, Munich has been almost rid of typhoid fever developing in the city, yet the proportional number of cases of gall-stones remains as before the perfection of Munich's modern sanitary system. In Hamburg since the change in the water-supply in 1892, following the cholera epidemic, there has been almost no typhoid fever, but the number of cases of gall-stone disease has not decreased. These examples certainly are significant.

The writer is of the opinion that, if every case of typhoid fever could be seen early enough so as to obtain a responsible anamnesis, as well as accurate subjective symptoms, those cases of perforative cholecystitis operated upon during the attack of

typhoid fever in which gall-stones are found, would justify the opinion that the gall-stone formation had antedated the attack of typhoid fever. This, in no manner, is an attempt to negative the commonly accepted opinion that gall-stones may form in the gall-bladder *after* an attack of typhoid fever, and be caused by the presence of the typhoid bacillus in the gall-bladder. Gall-stone formation may begin during an attack of typhoid fever, yet the fever must be prolonged or else relapses occur, caused by re-infection from the presence and activity of the bacilli in the gall-bladder and their discharge into the intestine in order that sufficient time elapse for the formation of gall-stones.

I have thus briefly outlined the subject of typhoidal cholecystitis in order that I may bring to your notice, by several illustrative cases, the surgical side of this complication as it appears to me from clinical experience.

First, the diagnosis: When the mental condition of a typhoid patient admits of an accurate anamnesis so that either an antecedent cholecystitis, with or without the probable presence of gall-stones, can be established or eliminated, an important position is attained relative to anticipatory findings during the course of the fever, and the relative importance to be given to subjective and objective symptoms pointing to infection of the gall-bladder or biliary tracts. A gall-bladder or gall-duct previously infected, harboring or not gall-stones, is more prone to further involvement, if invaded by typhoid bacilli, than one previously free from such complications. Therefore surgical complications are more likely to follow. That typhoidal cholecystitis, with threatened perforation of the gall-bladder, may be so prominent a manifestation that it can lead one to overlook a perforation of the ileum through an ulcerated Peyer's patch, is true. As an ex-

ample: I saw with a medical colleague in the Clarkson Hospital a young man in the third week of an attack of typhoid fever. Widal reaction was positive, and there was a moderate leucocytosis. There was marked sensitiveness over the gall-bladder area; the right lobe of the liver was enlarged and tender,—all of the symptoms pointed to an infection in the right upper quadrant of the abdomen, more particularly towards the middle line. His general condition was fair. It was determined one evening, because of the pain, swelling, and tenderness in the upper abdomen, to do an exploratory operation, as a leak from a focus of suppuration was suspected. Unfortunately, the operation had to be postponed until morning. A rapidly progressive peritonitis developed during the night, and at operation no focus of infection was found in the upper abdomen, but a perforation in the lower ileum disclosed the cause of the peritonitis. The usual technic and after-treatment were followed, but the man died. Keene ("Surgical Complications and Sequelæ of Typhoid Fever") says: "If the gall-bladder is much distended and perforation takes place toward the fundus, the seat of the most severe pain may be nearer to the umbilicus or in the right iliac fossa. In such cases it is not at all improbable that it would be very difficult to differentiate it from the perforation of the bowel from typhoid ulcer or perforation of the appendix. The difficulty of making a differential diagnosis is of less importance than might appear at first sight, since, in the present state of the surgery of typhoid fever, the same treatment should be unquestionably instituted." In my case the conditions were reversed; however, I have other evidence which shows the difficulty of estimating the value of symptoms.

A young woman, aged 35, had been ailing for several (three) weeks,—a kind of malaise, but not of sufficient import to keep her from her work, that of

a milliner. She consulted a phyisician, complaining of discomfort in the abdomen, more especially in the upper part. She had an attack of severe pain followed by collapse and then some reaction. The symptoms of a well-advanced general peritonitis was her condition when I saw her forty-eight hours later. Operation was out of the question, but some reaction developing, she was brought to the Clarkson Hospital, and the abdomen immediately opened on the right side and high up. Large quantities of gaseous infected bile were evacuated, and drainage was favored by tubage and position. The intestines were matted together, covered with lymph and not adherent at any place to the parietal peritoneum. For forty-eight hours the patient improved; then a perforation of the intestine took place; and this new infection, added to the original one, so depressed her vitality that she died in twenty-four hours after this complication was manifest. A combination of circumstances prevented other than a limited post-mortem. The perforation was demonstrated in the lower small bowel, and there was a large ragged hole in the gall-bladder. There were no gall-stones.

This case was not bacteriologically proved to be one of typhoid, but the man of experience will not quibble over the diagnosis of a "walking typhoid," perforative cholecystitis, perforation of the intestine. I have seen and operated upon a typhoidal perforation of the intestine where the history showed that the man had not been sick enough to stop work (he was a government teamster). The operation was done in the Government Hospital at Ft. Omaha.

Case furnished by Dr. A. D. Dunn. Miss S., aged 20 years. Past history of no importance except typhoid fever eight years previously. Patient gradually developed pain and discomfort in the right hypochondrium, with febrile and toxic manifestations.

The pain increased in severity and radiated to the right scapular and mammary regions; the gall-bladder became distinctly palpable and tender. After two weeks of such trouble she developed rose-spots and large spleen, a leukopenia of 3,700, with positive Widal. As the typical typhoid developed, the gall-bladder symptoms subsided. The case ran the usual course to recovery.

The patient lived in a farming community where there had been no typhoid for years, and in the last three months she had been away from home at a neighbor's only once. It would seem that the patient had carried typhoid bacilli in her gall-bladder for eight years, which ultimately led to a recurrence.

That the presence of typhoid bacilli in the gall-bladder and gall-ducts may tend to prolong a case of typhoid fever, re-infect perhaps, may be illustrated by the following case:

Severe, relapsing typhoid fever complicated by cholecystitis. Operations: cholecystostomy and choledoctotomy followed by cure.

Miss S., aged 32; occupation, clerk. She was first seen by her physician, Dr. Ginn, of Nebraska City, on April 1, 1910. The doctor made a diagnosis of typhoid fever. A careful anamnesis elicited nothing in the previous history of the case which would indicate in any way a lesion of the gall-bladder or gall-ducts. She gave a history of having had an attack of articular rheumatism at fifteen years of age, at which time she acquired a mitral insufficiency. The fever was of a relatively severe type, being complicated by hemorrhages from her bowels.

On April 25th,—estimated to be about the thirtieth day of her illness,—the temperature was normal for the first time, and remained practically normal for one week. On May 4th, the temperature rose rapidly to 104° F.; patient became delirious; the pulse was

rapid, weak, irregular and intermittent; and this condition persisted during the week. On May 10th, 11th, and 12th, there were hemorrhages from the bowels, and at this time pain and tenderness were complained of in the right upper part of the abdomen. The woman was very ill up to May 26th, the temperature on that day reaching 106° F. From then on there was a rapid amelioration of all symptoms, and on June 1st the temperature reached normal. The temperature remained practically normal until June 26th, when both the temperature and pulse showed marked evidence of a re-infection. There were great pain and tenderness over the gall-bladder, and some swelling. By June 30th the temperature was again normal, and the tenderness over the gall-bladder was much relieved. On August 16th there were again a very positive elevation of temperature, and increased pain and soreness in the gall-bladder region. On August 17th the patient was brought to the Clarkson Hospital.

The hospital record shows, in addition to the above report of Dr. Ginn, the following physical findings: sclera jaundiced; tenderness over the gall-bladder region, with some rigidity; heart enlarged three-quarters of an inch to the left of the mid-clavicular line, and to the right border of the sternum; systolic murmur of mitral insufficiency present; temperature, 102.4° F; pulse, 126; blood,—hemoglobin, 85 per cent; reds, 4,560,000; whites, 7,000; differential,—P. M. N., 70 per cent; L. M. N., 11 percent; S. L., 7 per cent; L. L., 12 per cent; Widal reaction, positive. Unfortunately, no cultures were made of the urine or dejecta.

Although the patient's general condition was far from encouraging for doing a surgical operation, I felt positive that the cholecystitis was typhoidal in type, and that the reinfections of typhoid fever were due to the presence of typhoid bacilli in the gall-blad-

der. An attempt was made to better the patient's condition, but failing in this she was operated upon on August 22d, five days after admission. The gall-bladder was somewhat distended; there were no stones in it, but the bile was slightly turbid. A stone, 1.5 cm. in length, was found, and removed from the lower end of the common duct. Drainage of both the gall-bladder and common duct was established. The bile from the gall-bladder showed pure cultures of typhoid bacillus; and that from the common duct, the typhoid bacillus and a small strain of the colon bacillus (the bile for cultures was taken from the gall-bladder and common ducts as they were incised). The woman was dangerously ill following the operation, but made a satisfactory recovery and has remained well to date.

This was a pure case of typhoidal cholecystitis, the gall-bladder involvement giving symptoms at the beginning of the first relapse. The absence of any obtainable history of gall-stones prior to the illness can fairly fix the initiation of the formation of the stone found in the common duct as taking place probably during the first part of the attack. The time from the beginning of the attack to the time of removal of the stone was from April 1st to August 22d,—sufficient time for its formation.

In so far as I am informed, this is the first case of typhoidal cholecystitis with probable formation of the stone during the attack, in which the stone was removed from the common duct. Cultures from the center of the stone were sterile,—a finding which does not negative the origin of the stone as due to typhoidal cholecystitis.

Operation (cholecystostomy) upon typhoid carriers, I think, should be done whenever there is evidence of any infection in the gall-bladder or ducts. In cases where no signs of inflammation can be found it might

be considered that possibly the nesting-place for the bacilli was in a diverticulum, and that operation was not indicated. There is favorable evidence for the carrying out of cholecystostomy in these dangerous persons. Vaccines should be tried before resorting to operative precedures, as clinical reports of their value are in evidence, when used in typhoid carriers.

DISCUSSION

Dr. W. D. Haggard (Nashville, Tenn): This is a very interesting theme which Dr. Summers has brought to our attention, and I am satisfied that its importance is not fully appreciated. When we consider that here we have twenty-one operations reported, with thirteen deaths, a mortality of sixty-odd per cent, it demonstrates that we are far behind in our management of cases of cholecystitis associated with typhoid fever. Even with intestinal perforation we have been able to cut down the mortality to thirty-odd per cent, and I do not see why we should not do better with the gall-bladder. Of course, we all recognize the great gravity of doing any operation upon typhoid-fever patients; but, at the same time, in cases of cholecystitis with classic manifestations, we ought to be able to drain, and drain sufficiently early, to give very much better results. To be sure, if we have perforation, then we are up against the same proposition we have in perforation of the intestine, and, by the way, the diagnosis is just as difficult, for the reason that the infectious fluid is carried down to the point near the appendix, on account of the hepatic flexure, and one is confounded as to whether or not he has intestinal perforation, but if we act, no matter which one we do, I think we do much better.

Personally, I have had one case of cholecystitis associated with typhoid fever, and that turned out to be a fortunate circumstance, the patient having a gradual onset, with the pain, rigidity, increased leucocytosis, and tumefaction over the gall-bladder, and after the ordinary cholecystotomy the patient made a recovery.

I have found that after we have rid these patients of these typhoid bacilli, they usually do quite well. The question has been raised if it would not be better to drain the gall-bladder in these cases. If these patients should have symptoms, my own idea would be to give them the benefit of the cholecystenterostomy and permanent drainage. In the doctor's ex-

perience with two cases he resorted to ordinary drainage, but was not able to effect a cure. That being the case I do not think McArthur's procedure of affording temporary drainage would suffice, but it is better to give them permanent drainage in the colon, which may bring about a permanent cure, because the intestine easily gets rid of typhoid bacilli.

This is an important topic and one that should be discussed freely in our local and state medical societies, as we have discussed intestinal perforation, because, after all that is said and done, the general practitioner is the man to be educated first of all. I think a paper like Dr. Summers has presented educates us, and we in turn must go out and do the missionary work. (Applause.)

Dr. Summers (closing the discussion): I have nothing to add, except I would suggest to those gentlemen who are in the habit of doing surgical work about the pylorus to obtain, if possible, from the upper part of the duodenum cultures from the fluid that may be evacuated, and in that way it will perhaps lead us to tell better whether or not infection might occur into the common duct from the intestine, or whether it comes through the general circulatory apparatus. Unfortunately, as you know, Mr. Moynihan has said that many of our deductions are based on post-mortem examinations, and that we should learn more from the living. I think in this one point, regardless of others, something might be done which will be valuable and will help us to understand what we are dealing with. There are many men who have opportunities from time to time of making the examinations I have suggested, and they should favor us with reports of their findings.

PREVENTION AND CURE OF INSANITY BY SURGERY

D. C. Brockman, M D.

OTTUMWA, IOWA

For ten years or more, beginning twenty years ago, there was an acrimonious discussion between alienists and gynecologists as to the relation that existed between pelvic diseases and insanity; and, as in many other such contentions, the advocates tried to prove their position rather than to shed light on the subject. The alienists too often contended that all insanity was due primarily to tissue changes in the brain; that all mental obliquity was due to material pathology; that Galen and Hyppocrates were mistaken when they wrote about "sympathetic insanities." At the same time the ultra-gynecologist contended that most cases of insanity in women, not due to gross brain disease, were due to pelvic reflexes. They advocated the examination of every insane woman under an anesthetic, and when any pelvic pathology could be found it should be removed, no matter whether it had ever caused symptoms or not.

Fortunately for humanity and science, both parties have ceased arguing for their illogical and erroneous contentions, and have settled down to a rational, scientific investigation of the subject, with very good results to all concerned. Every observer knows that mental symptoms very often make their first appearance at puberty, during pregnancy, or at the menopause; also that these great functional activities exercise an influence on an unstable mentality, which

too often interferes with the fine adjustment of the mental balance and consequently produces insanity. I say unstable mental condition, for I believe that most cases of insanity occur in patients who have some inherited or acquired defect that acts as a predisposing cause to the later insanity, and that when this predisposition exists, a relatively slight exciting cause develops well-marked mental symptoms. This predisposing cause accounts for the occurrence of insanity in one patient and not in another who suffers from the same somatic conditions.

Experience and observation show us that very many insane women suffer from gross diseases of the organs of generation, and that in the great majority of these cases there is but little, if any, relation existing between the two conditions, while in another group there is a direct relation that must be considered. It is to this latter class that I wish to call your special attention to today.

Every insane woman who has pathological pelvic conditions producing symptoms should have the same care and treatment as is accorded to her sane sister, whether or not there exists any relation between such pathological conditions and her mental trouble. In one group we may expect mental improvement to result directly from the cure of the pelvic disease, while in the other any mental improvement that results from the pelvic treatment will be indirect, that is, through the improvement of the general health and well-being of the woman.

The class of women in whom we may expect immediate, direct results to accrue from the cure of pelvic disease, includes women whose insanity and pelvic disease are synchronous, or nearly so, or who suffer from delusions or hallucinations pointing to the sexual organs. I have never seen this particular phase of the subject mentioned by any authority.

In every insane hospital will be found several women who suffer from delusions of a sexual type, either erotic fancies which lead them to sexual indiscretions whenever the opportunity presents itself, or delusions that point to, and seem to emanate from, the sexual function. These women will usually be found to be victims of gross pathological conditions of the pelvis, either inflammatory in character or due to the pressure of a tumor or well-marked uterus displacement. Not infrequently the pelvic and mental diseases showed themselves at the same time.

In other cases the insanity may not show itself until the pelvic irritation has exhausted the nervous system so that insanity results. These are the cases that respond most readily to surgery directed to the cure of the pelvic disorder, and it is surprising how rapidly mental improvement follows the cure of the local pathological conditions.

I feel that the character of the delusions from which the women suffer and the length of time they have suffered have much to do with the prognosis.

The other unfortunate women to whom we can bring great good are those who have suffered from the insanity of pregnancy.

It is a well-known fact that the women who suffered from insanity during one pregnancy will probably develop the same trouble during a future pregnancy. My plea for those poor unfortunates is relief through sterilization. I do not think we have any moral right to allow such a woman to suffer repeated recurrences of insanity, simply because she cannot help becoming pregnant. Not only is the happiness of the mother utterly ruined, while sane, by the hourly worry for fear that she will again lose her reason through conception, but the moral and mental integrity of the unborn child is jeopardized by the mental condition of the mother.

So long as the wife has no sure measure of preventing conception, and the average husband utterly disregards the wishes or interests of his wife in this regard, I feel that it is our duty to relieve the woman of her worry and danger by excising the tubes well down in the uterine cornua, whereby she will be rendered absolutely sterile. But I would strenuously oppose the too frequently performed double oöphorectomy, which produces a severe shock to the nervous system that may result in a mental explosion which will be more lasting than the condition that it was to remedy.

There is another group of women in whom we can prevent insanity by proper gynecological operation, in a large proportion of cases. I refer to the young woman who develops menstrual insanity or mental epilepsy. We have all observed such cases, in which epilepsy or mental aberration occurs only at the menstrual epoch. These cases, if allowed to go untreated, soon drift into a condition that is not amenable to any treatment. In a paper read before this Association eight years ago, I reported a series of this class of cases in which I tried to emphasize the importance in these cases, as in Jacksonian epilepsy, of operating early,—before the habit was established,—if we hope to derive any good from the treatment. At the same time I showed that in all cases where an artificial menopause was established very early, a complete cure resulted, just as the focal type of epilepsy should be prevented by proper surgery at the time of injury, or, if not then, an attempt should be made to correct the brain lesion at a very early date, before the epileptic habit had become established.

In all cases of menstrual epilepsy or recurring menstrual mania, double salpingo-oöphorectomy should be done within six months or a year after its occurrence. If done thus early, we shall effect a cure in all cases

except those dominated by a hereditary or other predisposing cause.

Some cures may be effected during the second year, but after continuing for two or three years, only little, if any, good should be expected.

The class of surgeons constituting this Association do not need a long-drawn-out dissertation on a practical subject like this, but need only to have attention called to a few salient points whereby great good may be brought to a most distressing class of our race. Then to summarize, briefly:

1. All insane women should have a careful pelvic examination on entering the hospital.

2. All pelvic pathological conditions causing symptoms should be treated the same as if occurring in a sane woman, primarily, in the cause of humanity, and, secondarily, in the hope that the physical improvement may assist in the mental cure.

3. All women suffering from pelvic pathological conditions which occurred synchronously with the insanity, should be treated.

4. All women suffering from pelvic pathological conditions and having sexual delusions or hallucinations may be expected to be cured mentally by curing the pelvic diseases.

5. All women who have suffered from insanity of pregnancy or puerperal insanity should be sterilized by removal of the tubes deep in the uterine cornua.

6. All cases of menstrual epilepsy or insanity should have the menopause established at the earliest possible moment.

MEMBERS OF THE WESTERN SURGICAL ASSOCIATION

January, 1910

ALPHABETICALLY ARRANGED

Abbott, Amos W.....Minneapolis, Minn
Allison, Nathaniel.....St. Louis, Mo.
Andrews, E. Wyllys.....Chicago, Ill.
Andrews, John W.....Mankato, Minn.
Baldwin, Samuel C.....Salt Lake City, Utah
Bartlett, Willard.....St. Louis, Mo.
Barton, George C.....Minneapolis, Minn.
Basham, David Walker.....Wichita, Kansas
Beede, Simon C.....David City, Neb.
Benjamin, Arthur E.....Minneapolis, Minn.
Blair, Vilroy P.....St. Louis, Mo.
Black, Carl E.....Jacksonville, Ill.
Bouffleur, Albert I.....Chicago, Ill.
Bowers, Charles E.....Wichita, Kansas
Brockman, David C.....Ottumwa, Iowa
Brown, John Young.....St. Louis, Mo.
Burge, Albertius J.....Iowa City, Iowa
Byford, Henry T.....Chicago, Ill.
Byrnes, William J.....Minneapolis, Minn.
Campbell, Osman B.....St. Joseph, Mo.
Christie, Robert J., Jr.....Quincy, Ill.
Clopton, Malvern B.....St. Louis, Mo.
Coffey, Robert C.....Portland, Ore.
Cokenower, James W.....Des Moines, Iowa
Collins, Clifford U.....Peoria, Ill.
Connell, F. Gregory.....Oshkosh, Wis.
Cottam, Gilbert Geoffrey.....Rock Rapids, Iowa
Courtney, Walter.....Brainerd, Minn.
Crawford, J. Lynn.....Cedar Rapids, Iowa
Crossen, Harry S.....St. Louis, Mo.
Davis, Byron B.....Omaha, Neb.

Dorsett, Walter B.....St. Louis, Mo.
Dunsmoor, Frederick A.....Minneapolis, Minn.
Eagleson, James B.....Seattle, Wash.
Eastman, Joseph Rilus.....Indianapolis, Ind.
Eisendrath, Daniel N.....Chicago, Ill.
Eitel, George G.....Minneapolis, Minn.
Eyester, George L.....Rock Island, Ill.
Fairchild, David S., Jr.....Clinton, Iowa
Fairchild, David S., Sr.....Clinton, Iowa
Ferguson, Alexander Hugh.....Chicago, Ill.
Forgrave, Harrison S.....St. Joseph, Mo.
Freeman, Leonard.....Denver, Colo.
Frick, William J.....Kansas City, Mo.
Geiger, Jacob.....St. Joseph, Mo.
Goodfellow, George S.....San Francisco, Cal.
Grant, William W.....Denver, Colo.
Gray, George Morris.....Kansas City, Kansas
Griffith, Jefferson D.....Kansas City, Mo.
Ground, William E.....Superior, Wis.
Haggart, John.....Durango, Colo.
Haggard, William D.....Nashville, Tenn.
Haines, William D.....Cincinnati, Ohio
Hall, C. Lester.....Kansas City, Mo.
Halstead, Albert E.....Chicago, Ill.
Hancock, John C.....Dubuque, Iowa
Harris, Malcolm L.....Chicago, Ill.
Hertzler, Arthur E.....Kansas City, Mo.
Hessert, William.....Chicago, Ill.
Hill, Howard.....Kansas City, Mo.
Hill, Roland.....St. Louis, Mo.
Hollowbush, Joseph R.....Rock Island, Ill.
Jackson, Jabez N.....Kansas City, Mo.
James, Charles S.....Centerville, Iowa
Jayne, Walter A.....Denver, Colo.
Jepson, William.....Sioux City, Iowa
Jobse, Peter H.....Milwaukee, Wis.
Jonas, August F.....Omaha, Neb.
Jones, Everett O.....Seattle, Wash.
Judd, Edward S.....Rochester, Minn.
Kahn, Maurice.....Leadville, Colo.
Kerr, Archibald A.....Salt Lake City, Utah
Kimball, Hannibal H.....Minneapolis, Minn.
Kletzsch, Gustav A.....Milwaukee, Wis.
Knott, Van Buren.....Sioux City, Iowa
Kreider, George N.....Springfield, Ill.

Lemon, Charles H. . . . . Milwaukee, Wis.
Levings, A. Hamilton . . . . . Milwaukee, Wis.
Littig, Lawrence W. . . . . Davenport, Iowa
Lord, John P. . . . . Omaha, Neb.
McArthur, Lewis L. . . . . Chicago, Ill.
McCandless, William A. . . . . St. Louis, Mo.
McCarthy, Wilton . . . . . Des Moines, Iowa
McDonald, Beverley . . . . . San Francisco, Cal.
McKinnon, Artemus I. . . . . Havelock, Neb.
MacLaren, Archibald . . . . . St. Paul, Minn.
MacMonagle, Beverly . . . . . San Francisco, Cal.
Macrae, Donald, Jr. . . . . Council Bluffs, Iowa
Magie, William H. . . . . Duluth, Minn.
Mann, Arthur T. . . . . Minneapolis, Minn.
Mayhew, David P. . . . . Colorado Springs, Colo.
Mayo, Charles H. . . . . Rochester, Minn.
Minahan, John R. . . . . Green Bay, Wis.
Mitchell, Albert . . . . . Lincoln, Neb.
Moore, James E. . . . . Minneapolis, Minn.
Morfit, John C. . . . . St. Louis, Mo.
Mudd, Harvey G. . . . . St. Louis, Mo.
Murphy, John B. . . . . Chicago, Ill.
Nicholson, Clarence M. . . . . St. Louis, Mo.
Oviatt, Charles W. . . . . Oshkosh, Wis.
Paddock, Charles E. . . . . Chicago, Ill.
Pearse, Herman E. . . . . Kansas City, Mo.
Percy, James F. . . . . Galesburg, Ill.
Perkins, Isaac B. . . . . Denver, Colo.
Plummer, Samuel C. . . . . Chicago, Ill.
Pond, Alanson M. . . . . Dubuque, Iowa
Porter, Miles F. . . . . Fort Wayne, Ind.
Powers, Clarence A. . . . . Denver, Colo.
Purdue, George C. . . . . Wichita, Kansas
Quain, Eric P. . . . . Bismarck, N. D.
Ricketts, B. Merrill . . . . . Cincinnati, Ohio
Ritchie, Harry P. . . . . St. Paul, Minn.
Rochford, William E. . . . . Minneapolis, Minn.
Ross, William L. . . . . Omaha, Neb.
Rothrock, John L. . . . . St. Paul, Minn.
Sudler, Mervin T. . . . . Lawrence, Kansas
Sala, St. Elmo M. . . . . Rock Island, Ill.
Sample, Chester H. . . . . Saginaw, Mich.
Sayle, Robert G. . . . . Milwaukee, Wis.
Schwyzer, Arnold . . . . . St. Paul, Minn.
Schwyzer, Gustav . . . . . Minneapolis, Minn.

Seelig, Major G. . . . . St. Louis, Mo.
Sherman, Harry M. . . . . San Francisco, Cal.
Smith, Joseph F. . . . . Wausau, Wis.
Sorkness, Paul. . . . . Fargo, N. D.
Stewart, Charles A. . . . . Duluth, Minn.
Stewart, J. Clark. . . . . Minneapolis, Minn.
Stokes, Arthur C. . . . . Omaha, Neb.
Sudler, Mervin T. . . . . Lawrence, Kansas
Summers, John E., Jr. . . . . Omaha, Neb.
Sweetser, Horatio B. . . . . Minneapolis, Minn.
Tait, Dudley. . . . . San Francisco, Cal.
Thompson, Benjamin. . . . . Tama, Iowa
Todd, Luther A. . . . . St. Joseph, Mo.
Turck, Raymond C. . . . . Jacksonville, Florida
Wallace, Charles H. . . . . St. Joseph, Mo.
Warren, John N. . . . . Sioux City, Iowa
Wetherill, Horace G. . . . . Denver, Colo.
Witherspoon, Thomas C. . . . . Butte, Mont.
Wright, Arthur L. . . . . Carroll, Iowa
Yates, John Lawrence. . . . . Milwaukee, Wis.

MEMBERS OF THE WESTERN SURGICAL ASSOCIATION

January, 1910

Arranged by States and Cities

CALIFORNIA

San Francisco
Goodfellow, C. E.
MacMonagle, Beverly
Sherman, H. M.
Tait, Dudley

COLORADO

Colorado Springs
Mayhew, David P.
Denver
Freeman, Leonard
Grant, W. W.
Jayne, Walter A.
Perkins, I. B.
Powers, Chas. A.
Wetherill, H. G.
Durango
Haggart, John
Leadville
Kahn, Maurice

FLORIDA

Jacksonville
Turck, R. C.

ILLINOIS

Chicago
Andrews, E. Wyllys
Bouffleur, A. I.
Byford, Henry T.
Eisendrath, D. N.
Ferguson, A. H.
Halstead, A. E.
Harris, M. L.
Hessert, William
McArthur, L. L.
Murphy, L. L.
Murphy, J. B.
Paddock, Charles E.
Plummer, Samuel C.
Galesburg
Percy, James F.
Jacksonville
Black, Carl E.
Collins, C. U.
Quincy
Christie, Robert J., Jr.
Rock Island
Eyster, George L.
Hollowbush, J. R.
Sala, St.E. M.
Springfield
Kreider, Geo. N.

INDIANA

Fort Wayne
Porter, Miles F.
Indianapolis
Eastman, J. R.

IOWA.

Carroll
Wright, A. L.
Cedar Rapids
Crawford, J. Lynn
Centerville
James, C. S.
Clinton
Fairchild, David S., Sr.
Fairchild, David S., Jr.
Council Bluffs
Littig, L. W.
Davenport
Macrae, Donald, Jr.
Des Moines
Cokenower, J. W.
McCarthy, Wilton
Dubuque
Hancock, J. C.
Pond, A. M.
Iowa City
Burge, A. J.
Ottumwa
Brockman, D. C.
Rock Rapids
Cottam, G. G.
Sioux City
Jepson, Wm.
Knott, VanBuren
Warren, J. N.
Tama
Thompson, Benjamin

KANSAS

Kansas City
Gray, G. M.
Lawrence
Sudler, M. T.
Wichita

Basham, D. W.
Powers, Chas. E.
Purdue, G. C.

MICHIGAN

Saginaw
Sample, C. H.

MINNESOTA

Brainerd
Courtney, Walter
Duluth
Magie, William H.
Stewart, C. A.
Mankato
Andrews, J. W.
Minneapolis
Abbott, A. W.
Barton, Geo. C.
Benjamin, A. E.
Byrnes, Wm. J.
Dunsmoor, F. A.
Eitel, George C.
Kimball, H. H.
McDonald, H. N.
Mann, A. T.
Moore, J. E.
Rochford, Wm. E.
Schwyzer, Gustav
Stewart, J. Clark
Sweetser, H. B.
Rochester
Judd, Edward S.
Mayo, C. H.
St. Paul
MacLaren, Archibald
Ritchie, Harry P.
Rothrock, John L.
Schwyzer, Arnold

MISSOURI

Kansas City
Frick, W. J.
Griffith, Jefferson O.
Hall, C. Lester
Hertzler, A. E.
Hill, Howard
Jackson, J. N.
Pearse, H. E.
St. Joseph
Campbell, O. B.
Forgrave, H. S.
Geiger, Jacob
Todd, Luther A.
Wallace, C. H.
St. Louis
Allison, Nathaniel
Bartlett, W.
Blair, Vilroy P.
Brown, John Y.
Clopton, M. B.
Crossen, Harry
Dorsett, W. B.
Hill, Roland
McCandless, W. A.
Morfit, John C.
Mudd, H. G.
Nicholson, C. M.
Seelig, Major G.

MONTANA

Butte
Witherspoon, T. C.

NEBRASKA

David City
Beede, S. C.
Lincoln
McKinnon, A. I.
Mitchell, A. R.
Omaha
Davis, B. B.
Jonas, A. F.
Lord, J. P.
Ross, W. L.
Stokes, Arthur C.
Summers, J. E., Jr.

NORTH DAKOTA.

Bismarck
Quain, Eric B.
Fargo
Sorkness, Paul

OHIO

Cincinnati
Haines, W. D.
Ricketts, B. M.

OREGON

Portland
Coffey, R. C.

TENNESSEE

Nashville
Haggard, W. D., Jr.

UTAH

Salt Lake City
Baldwin, S. C.
Kerr, Archibald A.

WASHINGTON

Seattle
Eagleson, J. B.
Jones, Everett O.

WISCONSIN

Green Bay
Minahan, J. R.
Milwaukee
Jobse, Peter H.
Kletzsch, Gustav A.
Lemon, C. H.
Levings, A. H.
Sayle, Robt. G.
Yates, John L.
Oshkosh
Connell, F. Gregory
Oviatt, Chas. W.
Superior
Ground, Wm. E.
Wausau
Smith, Joseph F.

INDEX

Abbott, A. W.
The plication of the anterior fold of the broad ligament for retrodisplacement of the uterus..... 243
Discussion on the above..... 249
Discussion on rupture of the kidney..... 124
Discussion on complete procidentia..... 256

Andrews, E. Wyllys.
Desmoid tumors of the abdominal wall after operation 27
Discussion on the above..... 32
Discussion on rupture of the kidney..... 120

Antiseptics, a new principle in the action of..... 81

Appendicitis, the operative technic in acute suppurative.. 67

Appendix, primary sarcoma of the..... 49

Bartlett, Willard.
The operative technic in acute suppurative appendicitis 67
Discussion of the *x*-ray..... 105

Beede, S. C.
Discussion on sarcoma of the appendix..... 58

Benjamin, A. E.
Discussion on antiseptics..... 92
Discussion on rupture of the kidney..... 123
Discussion on Meckel's diverticulum..... 231

Brockman, D. C.
Prevention and cure of insanity by surgery..... 283

Cholecystitis, typhoidal..... 273

Connell, F. Gregory.
Primary suture of subparietal rupture of the kidney, with report of a case..... 109
Discussion of inguinal hernia..... 239

Corscaden, James A.
Intussusception, with special reference to adults.. 131

Courtney, Walter.
Discussion on appendicitis..... 70
Discussion on rupture of the kidney..... 126

Davis, Byron B.
Pathological conditions arising as a result of Meckel's diverticulum..... 221
Discussion on rupture of the kidney..... 121

Division of fees and giving of commissions..... 15

Dorsett, Walter B.
Discussion on retrodisplacement of the uterus..... 248

Dunsmoor, F. A.
Discussion on rupture of the kidney..... 122
Discussion on intestinal obstruction..... 211

Eastman, Joseph Riley.
Abdominal exclusion of the fundus in complete procidentia 251
Discussion on the above..... 260

Eisendrath, Daniel N.
Discussion on the *x*-ray..... 102
Discussion on rupture of the kidney..... 124
Discussion on Meckel's diverticulum..... 229

Eliot, Ellsworth.
Intussusception, with special reference to results.. 131
Discussion on the above..... 205

Fairchild, D. S.
Discussion on osteomyelitis..... 38

Ferguson, Alexander Hugh.
Discussion on lesions of the hip-joint..... 268

Frick, William J.
Discussion on rupture of the kidney..... 120

Gould, C. W.
A new principle in the action of antiseptics..... 81

Grant, W. W.
Discussion on osteomyelitis..... 39
Discussion on intussusception..... 203
Discussion on retrodisplacement of the uterus.... 248
Discussion on complete procidentia..... 259

Haggard, W. D.
Discussion on typhoidal cholecystitis..... 281

Haines, W. D.
Discussion on intestinal obstruction..... 216
Discussion on complete procidentia..... 251

Harris, M. L.
Discussion on osteomyelitis..... 45
Discussion on complete procidentia..... 258

Hernia, the selection of operation for inguinal..... 233

Hertzler, E. A.
Discussion on desmoid tumors..... 31
Discussion on osteomyelitis..... 43
Discussion of sarcoma of the appendix..... 57

Hip-joint, lesions of the, and their management..... 263
Insanity, prevention and cure of, by surgery..... 283

Intestinal obstruction due to kinks and adhesions of the terminal ileum..... 209

Intussusception, with special reference to adults..... 131

Jackson, Jabez N.
Discussion on intestinal obstruction.....213-219
Discussion on complete procidentia..... 257

Jepson, William.
Discussion on sarcoma of the appendix..... 63

Johnston, George B.
Discussion on intussusception..... 203

Jones, E. O.
Primary sarcoma of the appendix..... 49
Discussion on the above..... 64

Kidney, primary suture of subparietal rupture on the, with report of a case..... 109

Knott, Van Buren.
Discussion on appendicitis..... 71
Discussion on Meckel's diverticulum..... 228

Krieder, George N.
Discussion on rupture of the kidney..... 121

Levings, A. H.
Discussion on the *x*-ray..... 106

Lord, John P.
Division of fees and giving commissions..... 15

McArthur, L. L.
Discussion on intussusception..... 199

MacCarty, W. C.
Discussion on sarcoma of the appendix..... 59

MacLaren, Archibald.
The selection of operation for inguinal hernia.... 233

Macrae, Donald.
Discussion on sarcoma of the appendix..... 60
Discussion on retrodisplacement of the uterus..... 247
Discussion on rupture of the kidney..... 128

Martin, Franklin H.

Mayo, Charles H.
Intestinal obstruction due to kinks and adhesions of the terminal ileum..... 209
Discussion on the above..... 219

Meckel's diverticulum, pathological conditions arising as a result of..... 221

Mediastinum surgery of the, other than injury and disease of the cardiovascular system..... 75

Moore, Jane E.
Discussion on osteomyelitis..... 40
Discussion on rupture of the kidney..... 127
Discussion on intussusception.....197-203

Murphy, John B.
Lesions of the hip-joint and their management..... 263
Discussion on complete procidentia..... 259

Procidentia, abdominal exclusion of the fundus in complete 251

Richardson, Maurice H.
Discussion on intussusception..... 200

Ricketts, Benj. Merrill.
Surgery of the mediastinum other than injury and disease of the cardiovascular system..... 75

Ritchie, Harry P.
The selection of operation for inguinal hernia.... 233
Discussion on the above..... 241

Root, Emerson F.
Discussion on sarcoma of the appendix..... 62
Discussion on the *x*-ray..... 107

Sala, E. M.
Definite knowledge obtained by means of the *x*-ray 95
Discussion on lesions of the hip-joint..... 270

Schwyzer, Arnold.
Discussion on antiseptics..... 89
Discussion on rupture of the kidney..... 123
Discussion on retrodisplacement of the uterus..... 246

Schwyzer, Gustav.
Discussion on sarcoma of the appendix..... 61

Seelig, Major G.
A new principle in the action of antiseptics..... 81
Discussion on the above..... 92
Discussion on appendicitis..... 72

Stewart, J. Clark.
Non-suppurative osteomyelitis..... 33
Discussion on the above..... 46
Discussion on desmoid tumors..... 30

Summers, John E.
Typhoidal cholecystitis..... 273
Discussion on the above..... 282

Tumors, desmoid of the abdominal wall after operation.. 27

Uterus, the plication of the anterior fold of the broad ligament for retrodisplacement of the..... 43

X-ray, definite knowledge obtained by means of the..... 95